

Twenty-nail Dystrophy Treated with Topical PUVA

LARS HALKIER-SØRENSEN, MARIE CRAMERS and KNUD KRAGBALLE

Department of Dermato-Venereology, University of Aarhus, Marselisborg Hospital, Aarhus, Denmark

A case of twenty-nail dystrophy treated with topical PUVA is described. The patient, a 19-year-old woman, had a 4-year history of a nail dystrophy involving all finger- and toe-nails. The finger-nail changes were treated with topical PUVA, dose 0.7–1.4 J/cm² × 3/week. After 7 months excellent improvement was seen, while the untreated toe-nails were unaffected. A maintenance dose of 0.7 J/cm² × 3/week was necessary to prevent recurrence. We suggest that topical PUVA is worth trying for the treatment of twenty-nail dystrophy.

(Accepted March 12, 1990.)

Acta Derm Venereol (Stockh) 1990; 70: 510–511.

L. Halkier-Sørensen, Department of Dermatology, Marselisborg Hospital, 8000 Aarhus C, Denmark.

Twenty-nail dystrophy is an acquired, idiopathic disease characterized by dull, thin, fragile nails with excess longitudinal ridging. It affects both children and adults. The pathogenesis is controversial, and the treatment unsuccessful (1, 2, 3). We report a case of twenty-nail dystrophy with marked improvement after treatment with topical PUVA.

CASE REPORT

A 19-year-old woman was seen in our Department in July 1988 because of dystrophic nails. The changes began insidiously at the age of 15 and were first noticed in the finger-nails, followed by similar changes in the toe-nails. One year after onset, she was treated with triamcinolone acetonide (10 mg/ml) injections, with some improvement initially, but the changes recurred and treatment was stopped. In July 1988 she was admitted to our Department. All finger-nails and toe-nails were involved, the thumb-nails and great toe-nails most severely. The nail plates were dull, thin, fragile and longitudinally ridged. The cuticles and eponychial tissues were normal (Fig. 1). A dermatologic examination disclosed a lingua scrotalis, but no evidence of lichen planus, alopecia areata or psoriasis and there was no family history of mucocutaneous diseases, psoriasis, lichen planus or alopecia areata. The tongue changes had existed since the early childhood. All laboratory values were normal and the mycological examination proved negative. A nail biopsy taken from the proximal nailfold of the right thumb showed no histological sign of psoriasis or lichen planus.

Initially she was treated experimentally with local vitamin D cream on one side for 3 months, but without success. It was then decided to try topical PUVA. A 0.15% solution of Meladine® (8-methoxypsoralen (8-MOP)) was applied uniformly to the eponychial epidermis on the fingers 45 min before radiation. The UVA radiation source was a battery-driven Woodlight, normally used in our Department for detection of tinea, erythrasma and during reading of patch tests and also used by philatelists. The average irradiance was 1.2 mW/cm² (measured with a PUVA-Meter, Herbert Waldmann), distance 0.5 cm. The exposure to UVA irradiation was initially 10 min (0.7 J/cm²) × 3/week, increasing gradually to 20 min (1.4 J/cm²) × 3/week after 3 weeks. Treatment was domiciliary. After treatment for 3 months an improvement was noticed. The dose was reduced to 10 min (0.7 J/cm²) × 3/week after 4 months because of moderate phototoxic reaction. An examination after 7 months revealed an excellent result in all finger-nails, while the untreated toe-nails were unaltered (Fig. 2). An attempt to reduce the dose resulted in recurrence and treatment was continued with a maintenance dose of 0.5 J/cm² × 3/week for 5 months without recurrence. Treatment of the toe-nails with topical PUVA has now been started.

DISCUSSION

Twenty-nail dystrophy is a clinical entity of onychodystrophy of all nails without other manifestation of skin disease. However, it has been associated with several causes such as alopecia areata, lichen planus, psoriasis and ichthyosis vulgaris (1, 2, 3). Our patient was entirely free of skin-, hair-, dental- and bone diseases and there was no family history of these diseases. In the literature we have not found any reports of simultaneous occurrence of lingua scrotalis and nail changes or tics. Lingua scrotalis may be seen in psoriasis – but psoriasis was excluded.

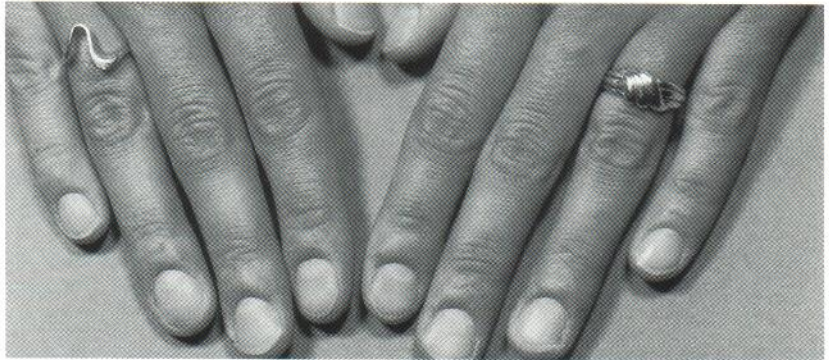
Although nail dystrophy has a tendency to resolve slowly with age (1, 2, 3) it is likely that the marked improvement was a result of topical PUVA treatment, as the changes in the finger-nails recurred following an attempt to reduce the dose. Also the toe-nails, used as controls, remained unchanged during treatment.

Since other treatment attempts have been unsuccessful (3) we suggest that treatment of nail dystrophy with topical PUVA is worth trying, although regression occurs slowly and a maintenance dose is necessary for a long time to prevent recurrence. One

Fig. 1. The finger-nails and toe-nails of a 19-year-old woman with twenty-nail dystrophy before treatment with topical PUVA.

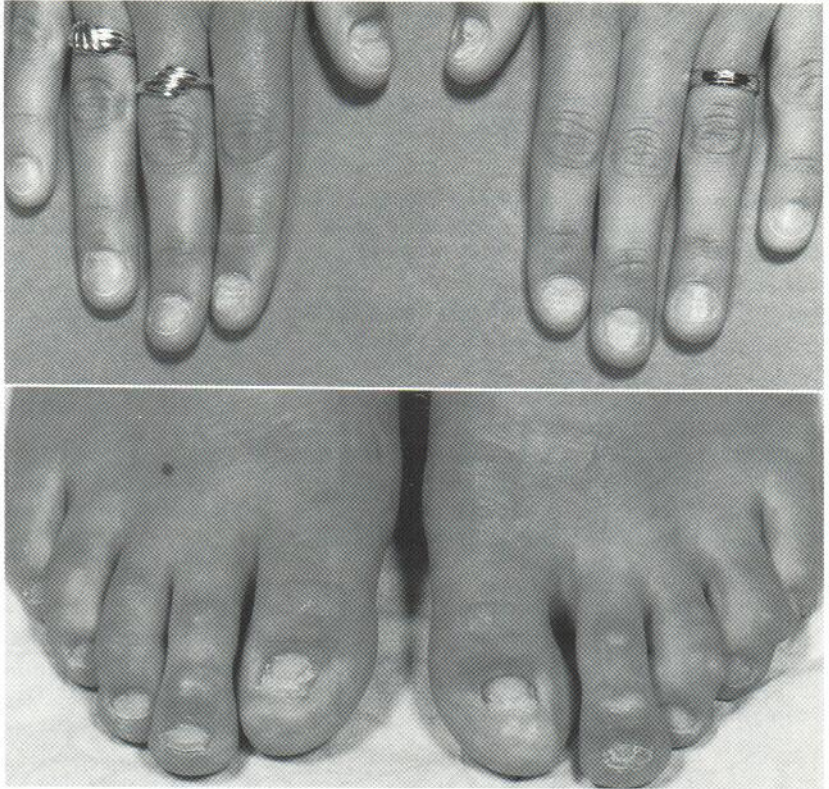

Fig. 2. The finger-nails of the same patient 7 months after treatment with topical PUVA.



advantage of using a simple Woodlight is that treatment can be carried out on a domiciliary basis. Furthermore, systemic side effects are avoided and smaller doses of PUVA radiation are required. Topical PUVA treatment for nail psoriasis has also been reported to be effective (4).

REFERENCES

1. Baran R, Dawber RP. Diseases of the nails and their management. Oxford: Blackwell Scientific Publications, 1984.
2. Horn RT, Odom RB. Twenty-nail dystrophy of alopecia areata. *Arch Dermatol* 1980; 116: 573-574.
3. Hazelrigg DE, Duncan WC, Jarratt M. Twenty-nail dystrophy of childhood. *Arch Dermatol* 1977; 113: 73-75.
4. Handfield-Jones SE, Boyle J, Harman RRM. Local PUVA treatment for nail psoriasis. *Br J Dermatol* 1987; 116: 280-281.