

# Punctate Porokeratotic Keratoderma:

## *Some Pathogenetic Analyses of Hyperproliferation and Parakeratosis*

SHIGEO KONDO, TAKAKO SHIMOURA, YUTAKA HOZUMI and KAZUO ASO

*Department of Dermatology, Yamagata University School of Medicine, Yamagata-city, Yamagata, Japan*

**An 82-year-old Japanese woman had numerous palmo-plantar keratotic plugs and pits, resembling 'music box spines'. Histological examination revealed compact columns of parakeratosis in the horny layer. Ultrastructurally, the affected stratum corneum contained numerous variable-sized pyknotic nuclei, and cells in the stratum granulosum contained fewer keratohyalin granules. Autoradiographic analysis by [<sup>3</sup>H]thymidine [<sup>3</sup>H]TdR incorporation into epidermal cells of affected skin slices in organ culture revealed that only basal cells below the keratotic plug were stimulated to proliferate. Two-dimensional gel electrophoresis revealed that palmar keratotic plugs contained the keratin filaments that are specifically present in the plantar viable epidermal layer, or other hyperproliferative epithelial cells. Key words: Palmo-plantar keratotic plug; Organ culture; Keratin pattern; Two-dimensional gel electrophoresis.**

(Accepted March 5, 1990.)

Acta Derm Venereol (Stockh) 1990; 70: 478-482.

S. Kondo, Department of Dermatology, Yamagata University School of Medicine, Yamagata-city, Yamagata 990-23, Japan.

The clinical presentation of numerous fine, acuminate, firm keratotic palmo-plantar papules resembling the spines of an old-fashioned music box cylinder has been designated by numerous terms. Recently, Friedman et al. (1) reported two cases of "punctate porokeratotic keratoderma". Lestringant & Berge (2) reported a similar case they called "porokeratosis punctata palmaris et plantaris". Furthermore they suggested that the case was a new entity.

We report a case similar to those in the above two papers. We examined the abnormally proliferative part of the affected skin by autoradiography with [<sup>3</sup>H]thymidine [<sup>3</sup>H]TdR, as well as by analysis of the keratin pattern by two-dimensional gel electrophoresis.

### CASE REPORT

An 82-year-old Japanese woman visited our clinic in May,

1987, complaining of solid palmo-plantar papules. Several days before her visit, her physician treating her angina pectoris noticed the papules and recommended her to visit our clinic. She had first noticed them about 20 years before, but had not paid much attention to them. Examination revealed numerous 0.5-2 mm keratotic plugs on the volar surface of the hands and feet (Fig. 1). There were also many punctate keratodermatous depressions among the plugs.

Her father died when she was 2 years old, and her mother when she was 4 years. She had 8 children; 6 alive, 4 males and 2 females now in the age range 40 to 61 years; 2 male children had died at 33 and 61 years. She had no brothers or sisters. Her children had no similar palmo-plantar papules. She did not remember whether her parents had had similar papules on their palms. She had no experience of taking arsenic. She had been treated for angina pectoris for 1 year.

### *Clinical findings*

Findings of peripheral blood cell counts, liver function and urine were all within the normal range. Electrocardiography showed slight ischemic signs.

### *Skin biopsy*

Punch biopsy specimens (2-3 mm) of palmar keratotic plugs were obtained for both light and electron microscopic examination, as well as for organ culture. The skin biopsy samples were taken such that each specimen should include both uninvolved and involved epidermis.

### *Organ culture (roller tube culture)*

The culture method was almost the same as that we had reported previously (3). Punch biopsy specimens were placed freely into 5 ml of culture medium in a sealed culture tube, which was then rolled at 15 rpm and 36°C. To the culture was added [<sup>3</sup>H]TdR (2 µCi/ml) on day 0 (start of culture), and after 1, 2 and 3 days of culture respectively, and incubated for 14 h. After labelling for 14 h (overnight), specimens were removed from the culture tubes and fixed in 10% formalin for autoradiography.

### *Two-dimensional gel electrophoresis*

Keratotic plugs on the palms were excised with an eraser and collected together. Punch biopsy specimens (2-3 mm) of uninvolved areas of the patient's palms were also obtained. Samples of pure stratum corneum of control persons were also collected, by tape-stripping with 3M-Scotch tape. Extraction and electrophoresis of keratin were carried out by the method of Achtstaetter et al. (4). The extracted keratins were subjected to two-dimensional gel

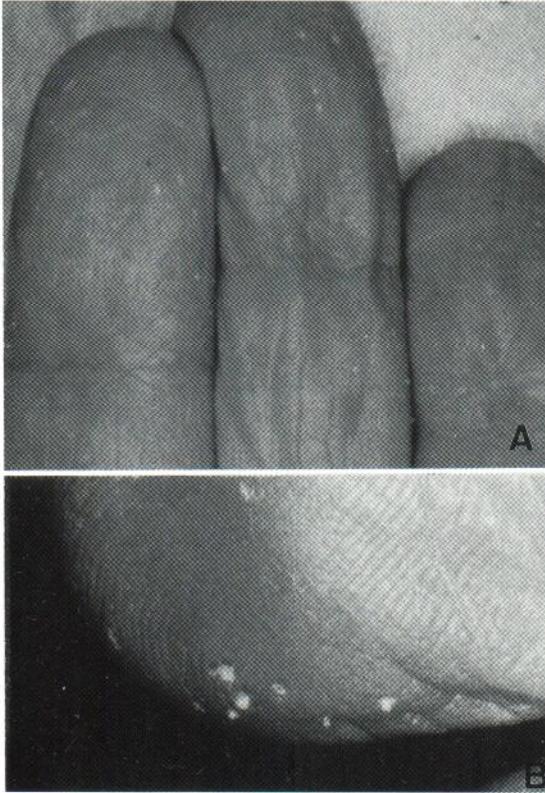


Fig. 1. Keratotic plugs, 'music box spines', and pits on volar surface of fingers (A), and on volar surface of toe (C).

electrophoresis (first: non-equilibrium pH gradient gel; second: sodium dodecyl sulfate-polyacrylamide gel). The spots in the gel were numbered according to the keratin catalog described by Moll et al. (5). For control purposes, keratins extracted from pure stratum corneum of normal palms of 2 normal adults, from whole epidermis of palms of 4 normal adults and from whole epidermis of uninvolved areas of the patient's palm were analysed.

## RESULTS

Clinical aspects of the patient's palmo-plantar lesions are shown in Fig. 1.

### Light microscopy

As shown in Fig. 2, biopsy specimens from the patient's palms revealed keratotic plugs over a sharply delimited area, with depression of the underlying malpighian layer below the general level of the epidermis, and that the papules consisted of a vertical parakeratotic column arising from the malpighian layer, with little or no intervening granular or lucid layer. The parakeratotic shaft corresponding to a

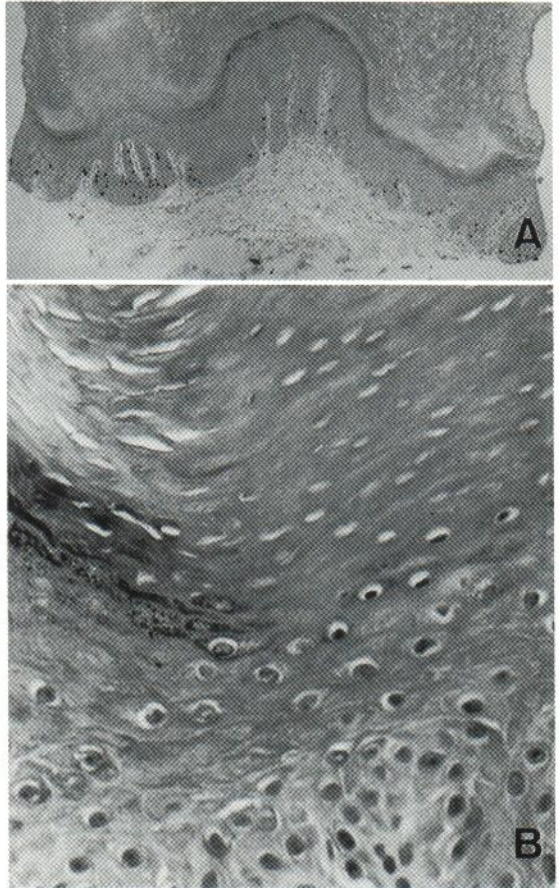


Fig. 2. Histological observations of the keratotic plugs. (A) Autoradiograph with  $[^3\text{H}]\text{TdR}$  incorporation. One of the serial sections of a cultured specimen shows two epidermal depressions beneath a well-demarcated (left) and a disappearing (right) keratotic plug. There are  $[^3\text{H}]\text{TdR}$ -incorporated cells (black dots) localized along the basal layers. They are much more frequently seen under the well-demarcated keratotic plug than the other part of the epidermal layer, including the part under the disappearing keratotic plug.  $\times 50$ . (B) Transitional zone of epidermis at the border of a keratotic plug. Normal surrounding epidermis (left side) shows orthokeratosis with many granular cells, meanwhile adjacent epidermis (right side) shows parakeratosis with fewer granular cells. No dyskeratotic cells are seen in the epidermal layer. Hematoxylin-eosin,  $\times 300$ .

plug was very sharply demarcated from the surrounding orthokeratotic corneal layer. There was no evidence of dyskeratosis or vacuolation degeneration in the epidermis below the plug. The pits were found to be histologically identical, though the apex of the parakeratotic plug was not raised up above the surrounding epidermis.

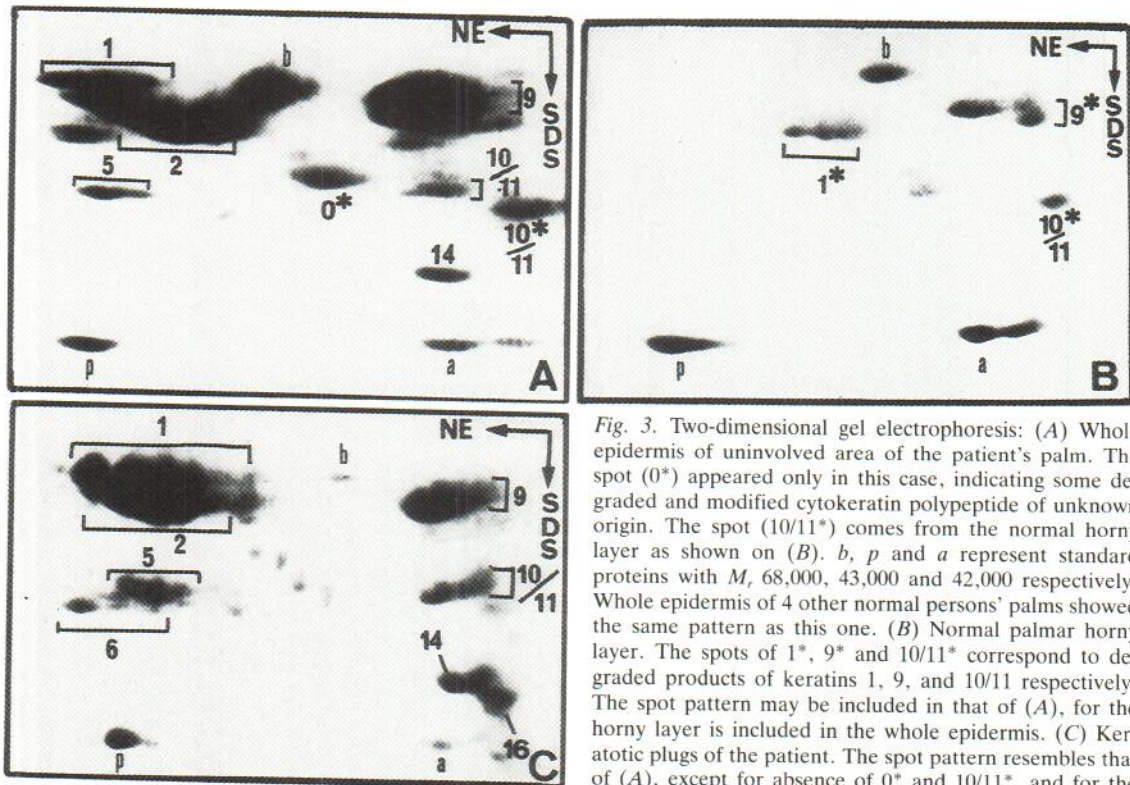


Fig. 3. Two-dimensional gel electrophoresis: (A) Whole epidermis of uninvolved area of the patient's palm. The spot (0\*) appeared only in this case, indicating some degraded and modified cytokeratin polypeptide of unknown origin. The spot (10/11\*) comes from the normal horny layer as shown on (B). *b*, *p* and *a* represent standard proteins with *M*, 68,000, 43,000 and 42,000 respectively. Whole epidermis of 4 other normal persons' palms showed the same pattern as this one. (B) Normal palmar horny layer. The spots of 1\*, 9\* and 10/11\* correspond to degraded products of keratins 1, 9, and 10/11 respectively. The spot pattern may be included in that of (A), for the horny layer is included in the whole epidermis. (C) Keratotic plugs of the patient. The spot pattern resembles that of (A), except for absence of 0\* and 10/11\*, and for the characteristic presence of Nos. 6 and 16.

#### Electron microscopy

Biopsy specimens revealed that the horny layer of the plug was markedly thickened and contained numerous pyknotic nuclei, granular debris and degraded cytoplasmic organelles of various sizes. Granular cells contained keratohyalin granules that were rarely absent, even though basophilic material was virtually absent within the granular layer as seen, by light microscopy. Keratin filaments, desmosomes, and lamellar bodies were present in normal quantities and appeared structurally unaltered.

#### Autoradiography

[<sup>3</sup>H]TdR-incorporated cells were seen along the basal cell layer, and some were located just above the basal layer. The labelled cells were seen much more frequently below the parakeratotic column (Fig. 2 A). To the specimens, [<sup>3</sup>H]TdR was added at 0, 24, 48 and 72 h of culture. All showed the same pattern by autoradiography, though epidermal layers grew rapidly around the dermal surface of the cultured explants and ultimately completely surrounded the explant (formation of an epiboly) after

3 days of culture. Formation of an epiboly caused epidermal cells to degenerate (data not shown). To assess the autoradiography data, the labelling index (L.I.) was examined in different parts of epidermis in autoradiographic preparations of cultured explants. L.I. values in the middle third and in both peripheral thirds of the whole length of the epidermal layer of an explant from an uninvolved area of the patient's palm did not differ significantly ( $p > 0.1$ ,  $7.8 \pm 1.1$  vs.  $6.7 \pm 1.2$ ); but L.I. values in both uninvolved and involved parts of epidermis in an explant from an involved area containing a keratotic plug did differ significantly ( $p < 0.01$ ,  $5.2 \pm 0.8$  vs.  $14.6 \pm 2.2$ ).

#### Two-dimensional gel electrophoresis

In whole epidermis of the normal palm as well as of uninvolved areas of the patient's palm, the following spots were constantly observed: Nos. 1, 2, 5, 9, 10, 11 and 14 (Fig. 3 A). In contrast, the horny layer of the normal palm contained fewer spots of keratin: 1\*, 9\* and 10/11\* (Fig. 3 B). Although the keratotic plugs in this report did not contain living cells, the spot pattern of extracted keratins (Fig. 3 C) resem-

bled that from the whole layer of palmar epidermis of normal persons as well as of the uninvolved area of the patient's palm, except for the prominent spots of Nos. 6 and 16, i.e., the latter were not clearly detected in living cell layers of normal palmar epidermis of 4 control persons or of the uninvolved area of the patient's palm in this report. The keratin patterns of whole palmar epidermis of normal control persons and the patient's uninvolved skin were identical.

## DISCUSSION

Friedman et al. (1) reviewed the published reports of what they called "music box spine" punctate keratotic lesions of the palms and soles, and found 6 cases (including their own 2 cases) (6, 7, 8, 9). Lestringant & Berge (2) commented that the keratotic plugs resembling "music box spines" in their case showed no lamellae as in porokeratosis of Mibelli, and the term columnar parakeratosis was a more accurate histological descriptive name for them than was cornoid lamella. In the present case, besides the clinical features, the absence of dyskeratosis under the 'columnar parakeratosis', of exaggerated clumping of keratin filaments, and of the altered basement membrane, confirmed that this case was distinct from porokeratosis.

Etiologically, some support a theory that intra-epidermal eccrine ducts or cells surrounding them might be responsible for the abnormal proliferation (10), but others refute this theory (6, 11). In the present case, no eccrine ducts were noticed in the keratotic plugs and epidermal layers below them. We observed by autoradiography that epidermal proliferation was enhanced around the basal layer under the keratotic plugs, and there were no proliferating cells in the middle and upper layers of the involved epidermis. There were also no [ $^3\text{H}$ ]TdR-incorporating cells around the intra-epidermal sweat ducts.

For the above reasons, we speculate that sweat ducts are not responsible for the lesion, but only basal cells below the keratotic plugs were stimulated to proliferate. Previously, we revealed that in a case of 'punctate porokeratosis' only basal cells of the epidermal layer beneath the cornoid lamella were stimulated to proliferate in organ culture (12), which case, the authors now consider, resembled the present case showing also 'music box spines'. In the present report, no heredity of the disease appeared

in her pedigree. In normal human epidermis, 6 cytokeratins have been identified (Nos. 1, 2, 5, 10, 11 and 14), but an additional large cytokeratin, No. 9, has been found only in the palms and soles (13, 14), although the biological function of the cytokeratin No. 9 remains obscure. In two-dimensional gel electrophoresis, we demonstrated previously by polypeptide mapping analysis that keratins of spots 1\*, 9\* and 10/11\* were degraded products of keratin Nos. 1, 9 and 10/11, respectively (15). Keratins 6 and 16 are regarded as marker polypeptides of proliferating cells, and are detected also in normal foot sole epidermis (5), but in previous (15) and present reports they were not detected in normal palmar epidermis of 4 control persons or in the uninvolved palmar epidermis of our patient. This suggests that there may be some difference in the polypeptide composition between keratins from palmar epidermis and sole epidermis. Keratotic plugs in our case contained keratins 6 and 16 and quantities of keratin polypeptides usually observed in living cells, indicating the hyperproliferation and incomplete keratinization (parakeratosis).

## REFERENCES

1. Friedman SJ, Herman PS, Pittelkow MR, Su WPD. Punctate porokeratotic keratoderma. *Arch Dermatol* 1988; 124: 1678-1682.
2. Lestringant GG, Berge T. Porokeratosis punctata palmaris et plantaris. A new entity? *Arch Dermatol* 1989; 125: 816-819.
3. Kondo S. Maintenance of epidermal structure of psoriatic skin in organ culture. *J Dermatol (Tokyo)* 1986; 13: 242-249.
4. Achtstaetter T, Hatzfeld M, Quinlan RA, Parmelee DC, Franke WW. Separation of cytokeratin polypeptides by gel electrophoresis and chromatographic techniques and their identification by immunoblotting. *Methods Enzymol* 1986; 134: 355-371.
5. Moll R, Franke WW, Shiller DL. The catalog of human cytokeratins: Patterns of expression in normal epithelia, tumors and cultured cells. *Cell* 1982; 31: 11-24.
6. Brown FC. Punctate keratoderma. *Arch Dermatol* 1971; 104: 682-683.
7. Herman PS. Punctate porokeratotic keratoderma. *Dermatologica* 1973; 147: 206-213.
8. Sakas LE, Gentry RH. Porokeratosis punctata palmaris et plantaris. *J Am Acad Dermatol* 1985; 13: 908-912.
9. Schiff BL, Hughes D. Palmoplantar keratosis acuminata with facial sebaceous hyperplasia. *Arch Dermatol* 1974; 109: 86-87.
10. Coupe R, Usher B. Keratosis punctata palmaris et plantaris. *Arch Dermatol* 1963; 87: 131-135.

11. Scott MJ, Costello MJ, Simuangno S. Keratosis punctata palmaris et plantaris. *Arch Dermatol Syphilol* 1951; 64: 301-308.
12. Aso K, Kondo S, Watanabe S, Kiyokawa T. A case of punctate porokeratosis. *Rinsho Hifuka* 1984; 38: 151-155 [in Japanese].
13. Fuchs E, Green H. Changes in keratin gene expression during terminal differentiation of the keratinocytes. *Cell* 1980; 19: 1033-1042.
14. Moll R, Franke WW, Volc-Platzer B, Krepler R. Different keratin polypeptides in epidermis and other epithelia of human skin: a specific cytokeratin of molecular weight 46,000 in epithelia of the pilosebaceous tract and basal cell epitheliomas. *J Cell Biol* 1982; 95: 285-295.
15. Shimoura T, Hozumi Y, Aso K. Characteristics of cytokeratins from stratum corneum of palms. *J Dermatol (Tokyo)* 1989; 16: 276-283.