

# Cutaneous Adverse Events to Targeted Therapies and Immunotherapies in Children: A Retrospective Study of 103 Patients from Two Tertiary Haemato-Oncology Referral Centres

Ayelet OLLECH<sup>1,2#</sup>, Michal YALON<sup>2,3#</sup>, Gadi ABEBE-CAMPINO<sup>2,3</sup>, Vered MOLHO-PESSACH<sup>4</sup>, Eve FINKLESTEIN<sup>4</sup>, Hodaya Cohen<sup>5</sup>, Aviv BARZILAI<sup>1,2</sup>, Shani CASPI<sup>2,3#</sup> and Shoshana GREENBERGER<sup>1,3#</sup>

<sup>1</sup>Department of Dermatology, Pediatric Dermatology Service, Sheba Medical Center, Tel-Hashomer, <sup>2</sup>Sackler Faculty of Medicine, Tel Aviv University, Tel Aviv, <sup>3</sup>Department of Pediatric Hemato-Oncology, Sheba Medical Center, Tel-Hashomer, <sup>4</sup>Faculty of Medicine, Hebrew University of Jerusalem, Pediatric Dermatology Service, Department of Dermatology, Hadassah Medical Center, Jerusalem and <sup>5</sup>Faculty of Medicine, Hebrew University of Jerusalem, Department of Hemato-Oncology, Hadassah Medical Center, Jerusalem, Israel

<sup>#</sup>These authors contributed equally.

**Targeted medications and immunotherapies are being developed to specifically target the pathways involved in tumours. There is limited experience with these new medications and their cutaneous side-effects in the paediatric population. A retrospective study of all paediatric oncological patients treated with targeted therapies and immunotherapies between 1 January 2013 and 1 August 2020 was carried out in 2 haemato-oncological referral centres. A total of 103 children were included in the study. The median (interquartile range) age was 13 years (8.4–16.9), male:female ratio 1.5:1, median (interquartile range) follow-up was 7 months (2–18). Fifty (48%) of the children developed cutaneous adverse events. Treatment was discontinued in only 3 (6%) cases and was altered in only (2%) 1 case due to a cutaneous adverse event. When targeted therapies and immunotherapies for tumours in children are used, there is an increased incidence of cutaneous adverse events. Nevertheless, treatment modification or discontinuation due to cutaneous side-effects is rarely needed.**

**Key words:** drug cutaneous adverse events; targeted therapies; immunotherapies; paediatrics; oncology.

Accepted Jul 6, 2021; Epub ahead of print Jul 7, 2021

Acta Derm Venereol 2021; 101: adv00501.

**Corr:** Ayelet Ollech, Pediatric Dermatology Clinic, Department of Dermatology, Sheba Medical Center, Tel-Hashomer, Israel. E-mail: ayelet.ollech@sheba.health.gov.il

There has been substantial development in cancer therapy in recent years. Targeted therapies aiming to inhibit molecular pathways that are critical to tumour growth, and immunotherapy that stimulates a host response that effectuates long-lived tumour destruction, are becoming commonplace (1).

Targeted therapies and immunotherapies may cause various adverse effects, including, cutaneous manifestations (2). In the paediatric population, due to the lower incidence of cancer than in the adult population (3), there is limited experience with these new medications and their cutaneous side-effects (4–8).

Available medications that target the MAP-K pathway include B-RAF inhibitors (such as vemurafenib and da-

## SIGNIFICANCE

Cutaneous adverse events to targeted medications and immunotherapies for oncological patients are well described in adults. There is limited experience with these new medications and their cutaneous side-effects in the paediatric population. This retrospective study reports on 103 children with an oncological disease treated with targeted therapies or immunotherapies. The cutaneous adverse events to these agents, and the course and treatment of the cutaneous disease are described. The findings indicate that cutaneous adverse events due to these treatments in children are frequent, but very rarely a cause for discontinuation of treatment. Patient education can help address these cutaneous adverse events.

brafenib), MEK inhibitors (such as trametinib), and ERK inhibitors, amongst others (9). These medications are in use to treat melanoma (10), neurogenic tumours (11) as well as for other indications (12). The mTOR inhibitors, sirolimus and everolimus, have been in use for complicated vascular tumours (13), angiomyolipoma, and neurogenic tumours of tuberous sclerosis complex (14, 15).

Available immunotherapies for cancer include the anti-PD-1/PD-L1 antibody and CTLA-4 checkpoint inhibitors, such as pembrolizumab, nivolumab, and ipilimumab, which are used for melanoma and other tumours (16).

The aim of this study is to describe the cutaneous side-effects of targeted therapies and immunotherapies in oncological paediatric patients in 2 tertiary referral centres in Israel.

## METHODS

A retrospective study was conducted on all paediatric oncological patients aged under 18 years at treatment initiation, who were treated with targeted therapies and immunotherapies in 2 tertiary medical centres between 1 January 2013 and 1 October 2020. All the patients are referred to the paediatric dermatology clinic before drug initiation and every month thereafter.

Data were collected on: age, sex, past medical history, past medical treatments, adverse event/s, cutaneous adverse event/s, time to rash appearance, severity, (according to the Common Terminology Criteria for Adverse Events Version 4.0 classification

(CTCAE)) (17) the disease course, the treatment for the cutaneous adverse event and the effect on the oncological treatment course.

Descriptive statistical analysis was performed. All data collected were summarized with the statistics appropriate to the metric of the variable. The study was approved by the local institutional review board committees.

## RESULTS

A total of 103 children with malignancy were included in the study. The median (interquartile range; IQR) age was 13 (8.4–16.9) years, male:female ratio 1.5:1. Median (IQR) follow-up was 7 (2–18) months.

Demographic data, oncological disease, and medications used are shown in **Table I**. Details of tumour-specific mutations and treatments are shown in Table S1<sup>1</sup>.

In 50 (48%) children there were cutaneous adverse events (AEs); AEs due to trametinib occurred in 14/15 (93%) patients, AEs due to dabrafenib and vemurafenib occurred in 13/18 (72%) patients, AEs due to trametinib and dabrafenib combination occurred in 3/5 (60%) patients, AEs due to everolimus and temsirolimus occurred in 5/17 (29%) patients, AEs due to tyrosine kinase inhibitors (TKIs) and others occurred in 5/11 (45%) patients, and AEs due to pemrolizumab, nivolumab or ipilimumab occurred in 10/38 (28%) patients.

Treatment was discontinued due to a cutaneous AEs in only one (1%) case and was altered in 3 (3%) cases ( $n = 103$ ), compromising 2% for drug cessation and 6% for drug alteration among the children who developed cutaneous AE ( $n = 50$ ).

**Table I. Patient demographics, oncological diagnosis, and treatment ( $n = 103$ )**

Characteristics	
Sex, $n$ (%)	
Female	41 (40)
Male	62 (60)
Age, years, median (range)	13 (8.4–16.9)
Oncological diagnosis, $n$ (%)	
Central nervous system	55 (53)
Germline	10 (9.7)
Sarcoma	11 (10.6)
Haematological	10 (9.7)
Renal angiomyolipoma	4 (3.8)
Bone	4 (3.8)
Histiocytosis	4 (3.8)
Solid	3 (2.9)
Vascular	2 (1.9)
Medication given, $n$ (%)	
Trametinib	15 (14.5)
Dabrafenib or vemurafenib	18 (17.5)
Trametinib and dabrafenib	5 (0.05)
Everolimus or temsirolimus	17 (16.5)
Tyrosine kinase inhibitors and others	11 (10.6)
Pembrolizumab, nivolumab or ipilimumab	37 (36)

The targeted medication and immunotherapies given, the number of patients treated with each medication, the cutaneous adverse events, and the course of adverse events causing treatment cessation/alteration are shown in **Table II**.

### MEK inhibitors: trametinib

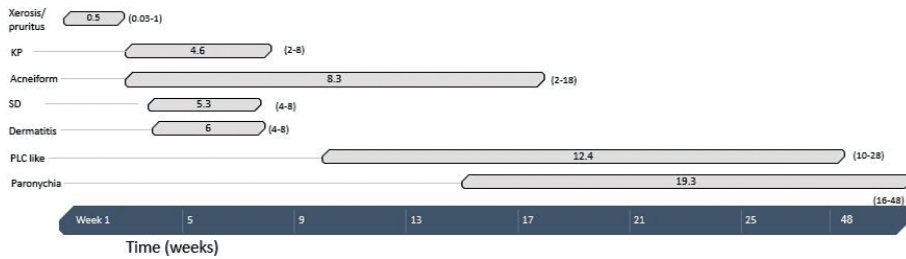
Fifteen patients were treated with trametinib. The mean  $\pm$  standard deviation (SD) treatment duration was 15.13 (9.8) months. Cutaneous adverse events to trametinib occurred in 14/15 patients. There were 31 side-effects, with a mean of 1.8 side-effects per patient. The

<sup>1</sup><https://www.medicaljournals.se/acta/content/abstract/10.2340/00015555-3867>

**Table II. Targeted and immunotherapies given, the number of patients treated, the cutaneous adverse events, and the adverse events causing treatment cessation /alteration**

Medication	Total number of patients (%)	Patients with cutaneous AEs, $n$ (%)	Cutaneous adverse events (number of patients)	Adverse events causing treatment cessation/alteration (cases)
MEK-I				
Trametinib	15 (14.5)	14 (93)	Acneiform eruption (8), seborrhoeic dermatitis (3), KP-like (2), dermatitis (3), paronychia (7), pruritus, PLC-like (3), insect bite-like reaction, xerosis, onychomycosis, urticaria (1 case each)	PLC-like eruption and severe paronychia (2) (stopped temporarily)
BRAF-I				
Dabrafenib, vemurafenib	18 (17.4)	13 (72)	Acneiform eruption (4), KP-like/follicular eruption (5), seborrhoeic dermatitis (1), curly (3) hair, hyperhidrosis (2), hyperkeratosis of the soles (2), panniculitis (2), eruptive nevi (2), pruritus, xerosis, tinea, photosensitivity (1 case each)	Bullous eruption (1) (stopped)
Trametinib and dabrafenib	5 (4.8)	3 (60)	Acneiform eruption, KP-like, hair loss, hyperkeratosis of palms and soles (1 case each)	–
mTOR inhibitors				
Sirolimus, Temsirolimus	17 (16.5)	5 (29)	Aphthous mucositis (5), hair loss, intertrigo, onychomycosis (1 case each)	–
TKIs and others	11 (10.6)	6 (45)	Hyperkeratosis of soles (2), KP-like/follicular rash (2), skin infections (furunculosis, ecthyma) (2), poliosis, xerosis, hair loss, eruptive naevi (1 case each)	Follicular rash (1) (dose decrease)
Checkpoint inhibitors				
Pembrolizumab, nivolumab, ipilimumab	37 (36)	10 (27)	Maculopapular rash (2), dermatitis (2), pruritus, acneiform eruption, seborrhoeic dermatitis, trachyonychia, lichenoid oral eruption, purpuric rash, and hair loss (1 case each)	
Total	103 (100)	50 (48)		Cessation 1/50 (2%) Alteration 3/50 (6%)

MEK-I: MEK inhibitors; BRAF-I: BRAF inhibitors; TKIs: tyrosine kinase inhibitors; KP: keratosis pilaris; PLC: pityriasis lichenoides chronica.

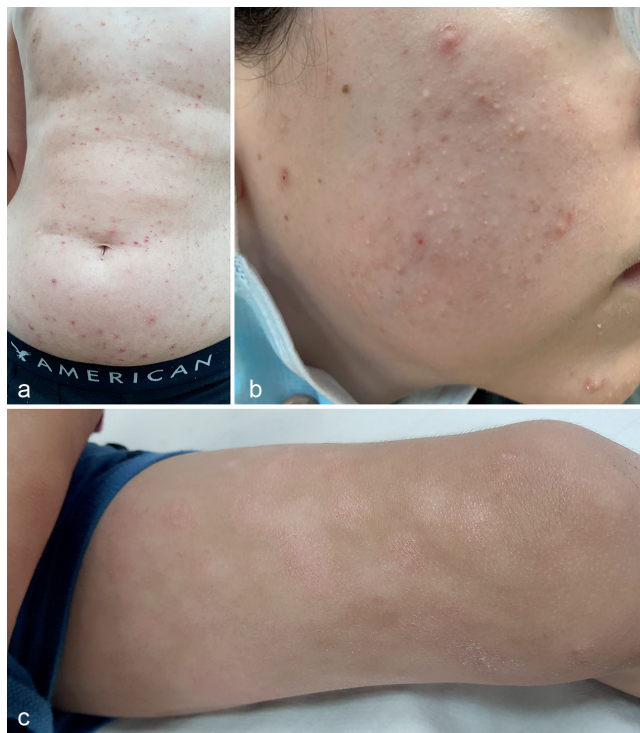

**Fig. 1. Trametinib: cutaneous adverse events, a timeline of appearance after treatment (median, range).**

severity of the side-effects was: 14 mild, 13 moderate, and 4 severe cases. In 2 cases treatment with trametinib was discontinued temporarily due to the cutaneous adverse event (grade 4, CTCAE). The onset of cutaneous side-effects occurred after a median (IQR) of 8 (4–15.5) weeks from drug administration. The onset of specific cutaneous AEs to trametinib is shown in **Fig. 1**.

Representative cutaneous side-effects due to trametinib are shown in **Fig. 2**. The side-effects that resulted in tem-

porary treatment cessations were a pityriasis lichenoides chronica (PLC)-like eruption and severe paronychia. The PLC-like eruption was treated with topical steroids and a macrolide antibiotic (roxithromycin) without resolution. Treatment was stopped for 1 month, which resulted in the resolution of the rash. Upon renewal of the medication at a lower dose, a milder rash recurred, which was well controlled on medium-strength topical steroids. Paronychia was initially treated with a topical steroid and antibiotic combination, then with surgical intervention, followed by topical timolol application with initial improvement, but for a short time only. Due to severely disabling pain, trametinib treatment was temporarily discontinued with complete resolution of the paronychia. Trametinib was re-initiated at a lower dose without recurrence.



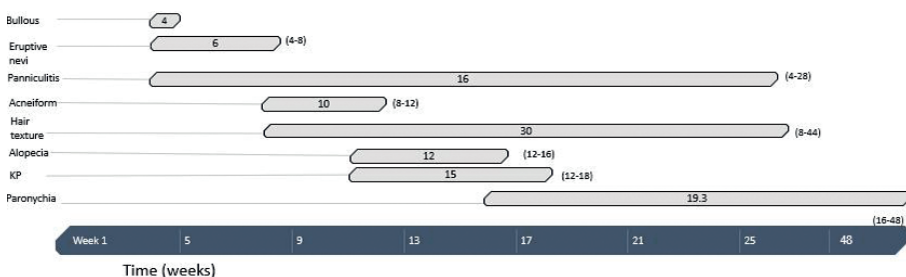
**Fig. 2. Cutaneous adverse events of trametinib.** (A) Diffuse pityriasis lichenoides chronica (PLC)-like eruption. (B) Keratosis pilaris/follicular eruption (C) Dermatitis.

*BRAF inhibitors: dabrafenib and vemurafenib*

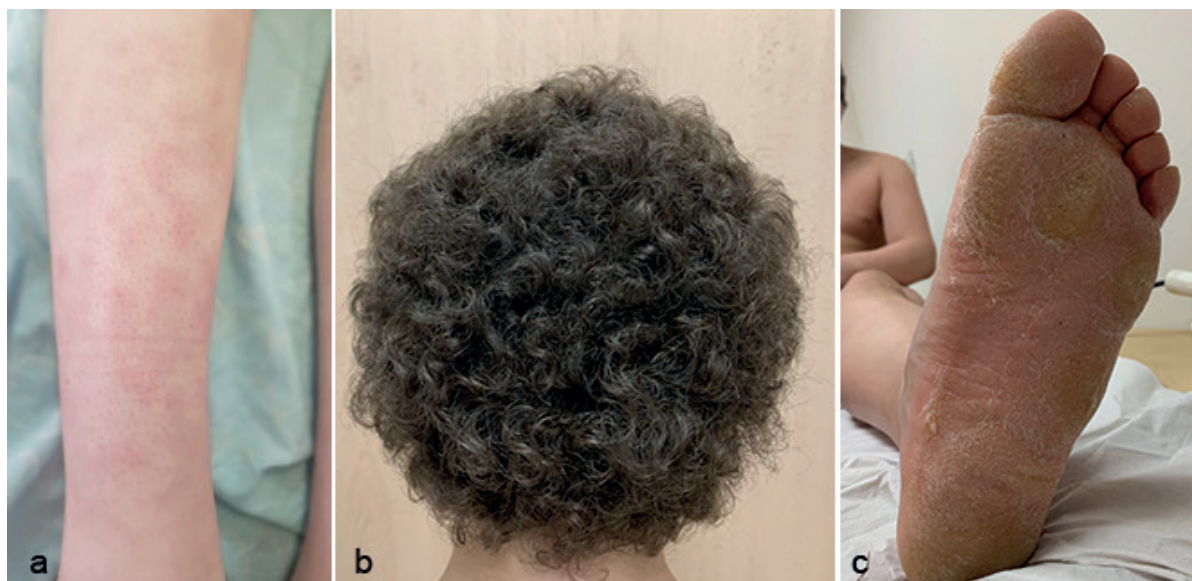
Fifteen patients were treated with dabrafenib and 3 with vemurafenib. The mean  $\pm$  SD treatment duration was  $12.14 \pm 5.5$  months. Cutaneous adverse events to the BRAF-I occurred in 13/18 patients. The onset of cutaneous side-effects occurred after a median (interquartile range (IQR) of 14 (8–28) weeks from drug administration. The time course of onset of specific cutaneous AEs to dabrafenib is shown in **Fig. 3**.

There were 28 side-effects, with an mean of 2 side-effects per patient. The severity of the side-effects recorded were: 22 mild, 4 moderate and 1 severe. In one case the treatment with dabrafenib was discontinued due to the cutaneous adverse event (grade 4 CTCAE).

Representative cutaneous side-effects due to dabrafenib are shown in **Fig. 4**. The side-effect resulting in treatment cessation was a bullous eruption presenting within weeks of initiation of dabrafenib. Initially, the bullous eruption was treated with potent topical steroids



**Fig. 3. Dabrafenib: cutaneous adverse events, a timeline of appearance after treatment (median, range).**



**Fig. 4. Cutaneous adverse effects of dabrafenib.** (A) Panniculitis. (B) Curly hair. (C) Keratoderma.

and oral antihistamine (dimethindene maleate) without resolution, which led to discontinuation of treatment. Panniculitis due to dabrafenib was treated with a high potency topical steroid and non-steroidal anti-inflammatory drugs (NSAID) (naproxen) with good results.

#### *Trametinib and dabrafenib combination therapy*

Five patients were treated with trametinib and dabrafenib combination therapy. The mean  $\pm$  SD treatment duration was  $17.35 \pm 10.2$  months. Cutaneous adverse events to trametinib and dabrafenib occurred in 3/5 patients. There was a total of 4 side-effects, with a mean of 1.5 side-effects per patient. The side-effects were mild in 3 cases and moderate in 2 cases. Treatment with trametinib and dabrafenib combination was not discontinued due to the cutaneous adverse event/s.

The onset of cutaneous side-effects occurred after mean  $\pm$  SD of  $19.6 \pm 7$  weeks from administration of the medications.

#### *mTOR inhibitors: everolimus and temsirolimus*

Sixteen patients were treated with everolimus and one with temsirolimus. The mean  $\pm$  SD treatment duration was  $3.11 \pm 1.9$  months. The onset of cutaneous side-effects occurred after a median of 4 weeks from the initiation of the drug administration. Cutaneous adverse events to everolimus occurred in 6/16 patients. There were 7 side-effects, with a mean of 1.5 side-effects per patient. The severity of the cutaneous side-effects was mild in 6 cases and severe in one case.

The aphthosis was treated with dexamethasone mouthwash and/or triamcinolone acetonide and lidocaine topical preparation with a good response.

#### *Tyrosine kinase inhibitors and others*

The TKIs included: sorafenib-3 cases, pazopanib, cabozantinib-2 cases and regorafenib-1 case. Other medications classes included asciminib and larotrectinib – one case each.

Mean  $\pm$  SD treatment duration was  $10.7 \pm 8$  months. Cutaneous adverse events to medications occurred in 6/13 patients. There were 9 side-effects, with a mean of 2 side-effects per patient. The severity of cutaneous side-effects was: 8 mild, 2 moderate and 5 severe. In none of the cases was the treatment with the TKIs discontinued due to the cutaneous adverse events. In one case treatment was altered. The onset of cutaneous side-effects occurred after a median (IQR) of 4 (3.5–21) weeks from drug administration.

The side-effects resulting in treatment changes were the onset of a follicular rash that resulted in dose reduction. A follicular rash due to sorafenib was treated with medium-high potent steroids without resolution, and thereafter the dose was decreased with improvement.

#### *Checkpoint inhibitors pembrolizumab, nivolumab and ipilimumab*

A total of 33 patients were treated with pembrolizumab, 4 with nivolumab and 1 with ipilimumab. Mean  $\pm$  SD treatment duration was  $6.6 \pm 6.5$  months. Cutaneous adverse events to pembrolizumab occurred in 10/33 (30%) patients. There were no cutaneous adverse events to nivolumab or ipilimumab. The onset of cutaneous side-effects occurred after a median (IQR) of 11 (7–9) weeks from drug administration. There were 10 cutaneous side-effects, with a mean of 1.2 side-effects per patient. The severity of the side-effects included: 4 mild and 6 moderate.

Maculopapular eruption occurred after a mean of 5 weeks (range 3–7 weeks) after treatment initiation and was moderate in severity (grade 2 CTCAE). Prednisone treatment was initiated at 0.5 mg/kg dose, with tapering occurring over 3 weeks together with antihistamines that resulted in resolution of the rash. Treatment with pembrolizumab was not discontinued due to the cutaneous adverse events.

#### *Treatment of cutaneous adverse events*

Treatment of the cutaneous AEs was given according to the specific presentation and severity of the reaction: acneiform eruptions were treated with a facial wash, topical antibiotics (erythromycin, clindamycin), benzoyl peroxide, topical retinoic acid, or a combination of treatments, with good results. Keratosis pilaris (KP)-like rash was treated with urea-containing moisturizers and retinoic acid preparations. Paronychia was treated with iodine-diluted soaks, combination antibiotic antifungal and steroid creams, and oral antibiotics or surgical intervention, if needed. For a more recalcitrant case, topical timolol was given with partial response. Seborrhoeic dermatitis was treated with bifonazole and selenium sulphide shampoos, and a topical steroid was applied for inflammatory rashes. Hyperkeratosis of the soles was treated with moisturizers that contained urea, salicylic acid ointments, and topical steroids of medium-to-high strengths. Pruritus was treated with moisturizers and antihistamines, as needed, and dermatitis was treated with medium-to-strong potency topical steroids, and moisturizers.

## DISCUSSION

This study describes the largest cohort of paediatric patients treated with targeted therapies and immunotherapies for various oncological indications. The strengths of this study include a large number of patients with a prolonged follow-up period of 7 (IQR 2–18) months. The study reported on all paediatric patients receiving the medications, and not only the ones referred to dermatology for consultation, thus an estimate of the incidence of AEs was possible. Also, cutaneous AEs to PD-1 inhibitors have been infrequently reported in the paediatric population.

Cutaneous side-effects were found in 48% of all patients. Drug classes with a high incidence of cutaneous side-effects include the MEK-I trametinib and the BRAF-I dabrafenib (93% and 86%, respectively). The study did not find any skin cancer (non-melanotic skin cancer (NMSC) or malignant melanoma) and only a few cases of benign eruptive naevi in BRAF-I monotherapy. This is in line with previous studies in this age population (4–7). In adult patients treated with BRAF-I 18–36% of patients developed cutaneous SCCs, keratoacanthomas,

or both (18–20). The lack of NMSC in the current study, over a relatively long follow-up period, may suggest that frequent routine clinic-dermoscopic examination is not indicated in paediatric patients receiving BRAF-I.

Blockage of both the BRAF and MEK pathways has shown to have an improved profile of cutaneous AEs, mainly decreased incidence of squamous cell carcinomas (SCCs) in adults taking the combination therapy (21). In the current study, 60% of the patients treated with both trametinib and dabrafenib had cutaneous side-effects, which is a lower incidence than when each agent was given alone. Since only 5 patients were on the combination of medications, it cannot be concluded that the combination also has a lower incidence of cutaneous adverse effects in children, and further studies are warranted.

Boull et al. (6) reported on 99 paediatric patients in the USA and Canada with side-effects to the BRAFI and MEKI medications for any indication. Three patients (0.03%) discontinued treatment due to a cutaneous reaction. Treatment was altered in 27–39.5% of patients, compared with 6% in the current study.

Song et al. (7) described a cohort of 22 patients with a median age at the visit of 11 years (range 3–19) on trametinib, dabrafenib, or everolimus for central nervous system (CNS) tumours. Ninety-six percent (21/22) of all patients had at least one skin reaction.

In our study, a slightly higher rate (1%) of affected patients on all medication classes had to stop treatment, but only 6% needed treatment alteration, which is much lower than described by other authors. The reason for these lower rates may be attributed to the frequent follow-up visits that we have with the oncological patients in our institutions, which may aid in the early recognition and treatment of the AE.

Belum et al. (4) conducted a literature search of clinical trials involving targeted anticancer therapies, in children, which reported dermatological AEs in their pooled data, from 19 clinical studies investigating 11 targeted anticancer agents and including 955 patients. The indications and medications studied were variable and included leukaemia (alemtuzumab, imatinib, dasatinib, sorafenib) CNS (erlotinib cabozantinib, pazopanib, everolimus, temsirolimus), and solid tumours. The most frequently encountered dermatological AEs were rash (unspecified) (19%), xerosis (18%), mucositis (17%) and pruritus (7%). Other AEs included pigmentary abnormalities of the skin/hair (13%), hair disorders (14%), urticaria (7%) and palmoplantar erythrodysesthesia (7%). They reported that rash usually appears in a dose-dependent fashion, varies by tumour type, and is perhaps dose-limiting.

In the current study, TKIs (including sorafenib, pazopanib, and cabozantinib, which act on multiple protein tyrosine kinases receptors) and other targeted therapies including larotrectinib (tropomyosin kinase receptors; Trk), asciminib (ABL myristoyl pocket STAMP antago-

nist) caused cutaneous side-effects in 45% of the patients. The study included a small number of patients on each medication, and therefore conclusions on incidence and course were limited.

Cutaneous adverse effects for pembrolizumab are reported in the adult population in 30% of patients (22). Most commonly reported are immune-related side-effects, including bullous eruptions and vitiligo, and non-immune responses, including dermatitis, lichenoid reactions, and pruritus (22–24). Literature on cutaneous side-effects of this medication in children is emerging, as the medication is also given more in this population. Cutaneous AEs reported in association with PD-1 inhibitors in children included macular and papular rash, occurring in 12% of 85 paediatric patients treated with nivolumab (24). Another phase I–II study of 154 paediatric patients receiving pembrolizumab for solid tumours or lymphomas found that 8% developed a rash, 2% developed pruritus, and <1% had photosensitivity (25).

In the current study, treatment with the immune checkpoint inhibition anti-PD-1 with pembrolizumab resulted in cutaneous AEs in 30% of patients, similar to the adult population. The current cohort included oncology patients with severe and progressive disease who failed multiple previous therapies and were being treated with checkpoint inhibitors as a last-line resort. Hence treatment duration was shorter in this group, for a mean of only 7 (2–18) months, mostly due to fatalities (18/37 in this cohort). The true incidence of skin AEs to pembrolizumab in children may be underestimated.

In the current study, almost all of the cutaneous AE were controlled by mild skincare and topical treatments and only 3 cases required advanced treatments or discontinuation of the medication.

In conclusion, targeted and immunotherapies for tumours in children have an increased frequency of cutaneous adverse events, notably for BRAF-I and MEK-I, followed by small molecule inhibitors, PD-1 antagonists, and mTOR inhibitors.

These cutaneous adverse events are usually not severe and can be controlled with topical or oral medications. Examination of these patients at an early stage of treatment is beneficial and may prevent the discontinuation of treatment due to the cutaneous side-effects.

Good patient education, including gentle skincare, emollients application, and avoidance of sun exposure, is warranted. Providing a summary of expected skin AE and timeline of the appearance of the rash, as provided in this study, may help the patient and their family in preparing for possible AE.

Larger studies are needed to confirm these observations.

*The authors have no conflicts of interest to declare.*

## REFERENCES

1. Hadjadj D, Deshmukh S, Jabado N. Entering the era of precision medicine in pediatric oncology. *Nat Med* 2020; 26: 1684–1685.
2. Reyes-Habito CM, Roh EK. Cutaneous reactions to chemotherapeutic drugs and targeted therapy for cancer: part II. targeted therapy. *J Am Acad Dermatol* 2014; 71: 217e1–e11; quiz 27–8.
3. Kaatsch P. Epidemiology of childhood cancer. *Cancer Treat Rev* 2010; 36: 277–285.
4. Belum VR, Washington C, Pratilas CA, Sibaud V, Boralevi F, Lacouture ME. Dermatologic adverse events in pediatric patients receiving targeted anticancer therapies: a pooled analysis. *Pediatr Blood Cancer* 2015; 62: 798–806.
5. Carlberg VM, Davies OMT, Brandling-Bennett HA, Leary SES, Huang JT, Coughlin CC, Gupta D. Cutaneous reactions to pediatric cancer treatment part II: targeted therapy. *Pediatr Dermatol* 2021; 38: 18–30.
6. Boull C, Hook K, Moertel C, Maguiness S. Cutaneous reactions in children treated with the mitogen-activated protein kinase extracellular signal-regulated kinase inhibitor trametinib for neural tumors. *Pediatr Dermatol* 2017; 34: 90–94.
7. Song H, Zhong CS, Kieran MW, Chi SN, Wright KD, Huang JT. Cutaneous reactions to targeted therapies in children with CNS tumors: a cross-sectional study. *Pediatr Blood Cancer* 2019; 66: e27682.
8. Boull CL, Gardeen S, Abdali T, Li E, Potts, J, Rubin N, et al. Cutaneous reactions in children treated with MEK inhibitors, BRAF inhibitors, or combination therapy: a multi-center study. *J Am Acad Dermatol* 2021; 84: 1554–1561.
9. Yaeger R, Corcoran RB. Targeting alterations in the RAF-MEK pathway. *Cancer Discov* 2019; 9: 329–341.
10. McArthur GA, Chapman PB, Robert C, Larkin J, Haanen JB, Dummer R, et al. Safety and efficacy of vemurafenib in BRAF(V600E) and BRAF(V600K) mutation-positive melanoma (BRIM-3): extended follow-up of a phase 3, randomised, open-label study. *Lancet Oncol* 2014; 15: 323–332.
11. Rizzo D, Ruggiero A, Amato M, Maurizi P, Riccardi R. BRAF and MEK inhibitors in pediatric glioma: new therapeutic strategies, new toxicities. *Expert Opin Drug Metab Toxicol* 2016; 12: 1397–1405.
12. Bjornsti MA, Houghton PJ. The TOR pathway: a target for cancer therapy. *Nat Rev Cancer* 2004; 4: 335–348.
13. Hammill AM, Wentzel M, Gupta A, Nelson S, Lucky A, Elluru R, et al. Sunitinib for the treatment of complicated vascular anomalies in children. *Pediatr Blood Cancer* 2011; 57: 1018–1024.
14. Hutt-Cabezas M, Karajannis MA, Zagzag D, Shah S, Horakayne-Szakaly I, Rushing EJ, et al. Activation of mTORC1/mTORC2 signaling in pediatric low-grade glioma and pilocytic astrocytoma reveals mTOR as a therapeutic target. *Neuro Oncol* 2013; 15: 1604–1614.
15. Bissler JJ, Franz DN, Frost MD, Belousova E, Bebin EM, Sparagana S, et al. The effect of everolimus on renal angiomyolipoma in pediatric patients with tuberous sclerosis being treated for subependymal giant cell astrocytoma. *Pediatr Nephrol* 2018; 33: 101–109.
16. Luke JJ, Flaherty KT, Ribas A, Long GV. Targeted agents and immunotherapies: optimizing outcomes in melanoma. *Nat Rev Clin Oncol* 2017; 14: 463–482.
17. Chen AP, Setser A, Anadkat MJ, Cotliar J, Olsen EA, Garden BC, Lacouture ME. Grading dermatologic adverse events of cancer treatments: The Common Terminology Criteria for Adverse Events Version 4.0. *J Am Acad Dermatol* 2012; 67: 1025–1039.
18. Anforth R, Fernandez-Penas P, Long GV. Cutaneous toxicities of RAF inhibitors. *Lancet Oncol* 2013; 14: e11–e18.
19. Anforth RM, Blumetti TC, Kefford RF, Sharma R, Scolyer RA, Kossard S, et al. Cutaneous manifestations of dabrafenib (GSK2118436): a selective inhibitor of mutant BRAF in

- patients with metastatic melanoma. *Br J Dermatol* 2012; 167: 1153–1160.
20. Lacouture ME, Duvic M, Hauschild A, Prieto VG, Robert C, Schadendorf D, et al. Analysis of dermatologic events in vemurafenib-treated patients with melanoma. *Oncologist* 2013; 18: 314–322.
  21. Carlos G, Anforth R, Clements A, Menzies AM, Carlino MS, Chou S, Fernandez-Peñas P. Cutaneous toxic effects of BRAF inhibitors alone and in combination with MEK inhibitors for metastatic melanoma. *JAMA Dermatol* 2015; 151: 1103–1109.
  22. Sibaud V. Dermatologic reactions to immune checkpoint inhibitors: skin toxicities and immunotherapy. *Am J Clin Dermatol* 2018; 19: 345–361.
  23. Sanlorenzo M, Vujic I, Daud A, Algazi A, Gubens M, Luna SA, et al. Pembrolizumab cutaneous adverse events and their association with disease progression. *JAMA Dermatol* 2015; 151: 1206–1212.
  24. Davis KL, Fox E, Merchant MS, Reid JM, Kudgus RA, Liu, X, et al. Nivolumab in children and young adults with relapsed or refractory solid tumors or lymphoma (ADVL1412): a multicentre, open-label, single-arm, phase 1–2 trial. *Lancet Oncol* 2020; 21: 541–550.
  25. Georger B, Kang HJ, Yalon-Oren M, Marshall LV, Vezina C, Pappo A, et al. Pembrolizumab in paediatric patients with advanced melanoma or a PD-L1-positive, advanced, relapsed, or refractory solid tumor or lymphoma (KEYNOTE-051): interim analysis of an open-label, single-arm, phase 1-2 trial. *Lancet Oncol* 2020; 21: 121–133.
  26. Cacciotti C, Choi J, Alexandrescu S, Zimmerman MA, Cooney TM, Chordas C, et al. Immune checkpoint inhibition for pediatric patients with recurrent/refractory CNS tumors: a single institution experience. *J Neurooncol* 2020; 149: 113–122.