

Paradoxical Reaction in a Patient with Hidradenitis Suppurativa Undergoing Adalimumab Treatment

Soichiro IKEYA¹, Takuya TAKEICHI^{1*}, Tomoki TAKI¹, Yoshinao MURO¹, Tomoo OGI² and Masashi AKIYAMA¹

¹Department of Dermatology, Nagoya University Graduate School of Medicine, 65 Tsurumai-cho, Showa-ku, Nagoya 466-8550 and ²Department of Genetics, Research Institute of Environmental Medicine, Nagoya University, Nagoya, Japan. *E-mail: takeichi@med.nagoya-u.ac.jp
Accepted May 26, 2021; Epub ahead of print May 27, 2021

A paradoxical psoriasiform reaction has been reported as a common side-effect of tumour necrosis factor alpha (TNF- α) inhibitors. Although anti-TNF inhibitors are highly effective for treating psoriasis, 2–5% of treated patients with PV develop a paradoxical psoriasiform reaction (1). The most widely proposed putative pathomechanism of paradoxical psoriasiform reaction in PV is a disruption of the balance between TNF and TNF- α (2). Paradoxical psoriasiform reaction is caused by the absence of TNF, and represents an ongoing type-I interferon-driven innate inflammation that fails to elicit T-cell autoimmunity and lacks memory T cell-mediated relapses (3, 4). In 2018, Dequidt et al. (5) reported paradoxical psoriasiform reaction in 8 of 41 (20%) cases of severe hidradenitis suppurativa (HS) treated with TNF- α inhibitors.

However, *MEFV* mutations also have been observed in patients with HS (6). We report here a case of HS with a paradoxical reaction caused by anti-TNF- α treatment. Interestingly, this patient has compound heterozygous variants in *MEFV*.

reappeared when it was resumed. The eruptions were diagnosed as a paradoxical psoriasiform reaction, although the possibility that the psoriasiform eruptions appeared coincidentally cannot be completely excluded.

After informed consent was obtained, a genomic DNA sample from the peripheral blood leukocytes of patient was used for whole-exome sequencing analysis (7). No potentially pathogenic mutations were identified in the genes associated with γ -secretase subunits. However, heterozygous rare variants, c.605G>A (p.Arg202Gln, rs224222) and c.1772T>C (p.Ile591Thr, rs11466045), were detected in *MEFV*, the gene implicated in familial Mediterranean fever. Additional Sanger sequencing in the parents confirmed that p.Ile591Thr and p.Arg202Gln were paternal and maternal, respectively.

Immunohistochemical analyses were conducted with anti-IL17A antibody (NBP1-76337, Novus Biologicals, LLC, Centennial, CO, USA) and anti-human myxovirus resistance protein 1 (MxA) antibody (sc-166412, Santa Cruz Biotechnology, Santa Cruz, CA, USA) in skin samples from an HS lesion and the paradoxical psoriasiform reaction in the present patient, and from a psoriatic plaque lesion from another patient with typical PV. Fig. 1d, e and f show a stronger expression of IL17A in the HS skin than in the paradoxical psoriasiform reaction of the patient and the control PV skin. MxA was expressed in the cytoplasm

CASE REPORT

A teenage boy presented to our dermatology clinic for the evaluation of tender cystic lesions on the groin and axilla 3 years ago. He had no previous history of plaque psoriasis. Physical examination revealed scattered erythematous cystic papules and nodules on the axilla, the lower abdomen and the groin (Fig. 1a). The patient was categorized as Hurley Severity Grade Stage II. He was treated with oral minocycline, 200 mg/day, oral prednisolone, 10 mg/day, cyclosporine, 100 mg/day, and topical nadifloxacin solution in combination. However, treatment was ineffective, hence the cyclosporine was increased to 150 mg/day. The disease progressed and the therapy was changed to adalimumab 1 year ago.

After a few weeks of adalimumab treatment, scaly hyperkeratotic plaques appeared around the patient's neck (Fig. 1b). A punch biopsy specimen from a plaque on the neck revealed parakeratosis, elongation of thick rete ridges, and infiltration of lymphocytes and neutrophils into the superficial dermis, suggesting a psoriasiform reaction (Fig. 1c). The eruptions on the neck disappeared when adalimumab was stopped, and

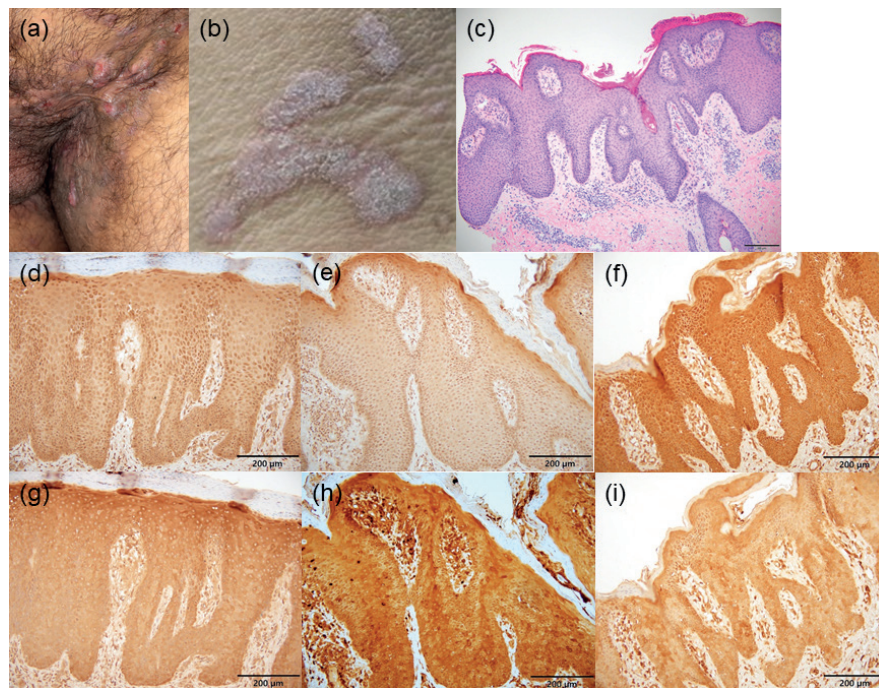


Fig. 1. Clinical and histological features of the patient with hidradenitis suppurativa (HS). (a) Eruptions of HS on the groin. (b) Psoriasiform plaques on the neck. (c–i) Histological features. (c) Histopathological features of the psoriasiform skin lesion on the neck (haematoxylin-eosin stain). Skin samples from the psoriasiform eruption on (e, h) the neck and (f, i) an HS lesion on the groin in the current patient and (d, g) a lesional skin sample from a control, non-tumour necrosis factor- α inhibitor-induced psoriasis vulgaris patient were stained with (d–f) anti-interleukin-17A antibodies and (g–i) anti-myxovirus resistance protein 1 antibodies. Scale bars: (c–i) 200 μ m.

of keratinocytes more strongly in the lesion of the paradoxical psoriasiform reaction (Fig. 1h) than in the HS lesion or in the control PV lesion (Fig. 1g, i).

DISCUSSION

Recently, Nomura summarized that, in the autoinflammatory aspect of HS, *MEFV* mutations might contribute to the pathogenesis of HS (8, 9). In addition, HS can present as a component of systemic autoinflammatory syndromes caused by mutations in *PSTPIP1*, which encodes PSTPIP1 (8). Shoham et al. (10) elucidated the interaction between 2 leukocyte proteins: pyrin, which is encoded by *MEFV*, and PSTPIP1. The mutations in *PSTPIP1* underlying PAPA syndrome led to the hyperphosphorylation of PSTPIP1 and a marked increase in its interaction with pyrin (10). Increased pyrin-PSTPIP1 binding may, in turn, modulate the normal immunoregulatory function of pyrin by preventing its interaction with other proteins (10). Pyrin is also known to play a role in the regulation of innate immunity and the inflammatory response to interferon (IFN)- γ , as well as in the degradation of other inflammasome components. Interestingly, the current patient has 2 known rare variants in *MEFV*. Thus, the *MEFV* variants might have been potential predisposing factors for the paradoxical reactions of the *MEFV* variants in this patient. To our knowledge, there are no reports of patients with HS associated with *MEFV* variants showing paradoxical psoriasiform reactions. These findings suggest that the autoinflammation related to the variants in autoinflammatory genes might play a role(s), not only in the pathomechanisms of HS (11), but also in the generation of paradoxical psoriasiform reaction.

The current study found IL17A to be more strongly expressed in the HS lesion than in the paradoxical psoriasiform reaction lesion in the present patient. These expression patterns were observed in previous reports (12, 13). In contrast, higher expression of MxA was revealed in the paradoxical psoriasiform reaction than in the HS lesion or the control psoriatic lesion from the patient with typical PV, similarly to previously reported findings (5, 14). MxA is a key mediator of the interferon-induced antiviral response against a wide range of viruses, and is specifically induced by IFN. Thus, MxA might be a marker for type 1 IFN activity in the lesions of paradoxical psoriasiform reaction, although the exact role of MxA in the pathogenesis of paradoxical psoriasiform reaction remains unknown. TNF- α silences the production of IFN- α by forcing pDC maturation (2). In paradoxical psoriasiform reaction, the blockade of TNF- α by a TNF- α inhibitor results in an excess of IFN- α , which induces T-cell migration to the skin (2). These findings suggest that MxA induced by IFN may play a pivotal role in the pathogenesis of paradoxical psoriasiform reaction in patients with HS.

ACKNOWLEDGEMENTS

This research was supported by the Japan Agency for Medical Research and Development under grant number JP20ek0109488. The study was also supported in part by JSPS KAKENHI grant number 20K08648 to T. Takeichi, a Nakatomi Foundation grant to T. Takeichi, grants from the Maruho Takagi Dermatology Foundation to T. Takeichi, the Hori Science and Arts Foundation to T. Takeichi, and the Japanese Dermatological Association Dermatological Research Fund, supported by ROHTO Pharmaceutical Co., Ltd to T. Takeichi.

The authors have no conflicts of interest to declare.

REFERENCES

1. Conrad C, Domizio JD, Mylonas A, Belkhdja C, Demaria O, Navarini AA, et al. TNF blockade induces a dysregulated type I interferon response without autoimmunity in paradoxical psoriasis. *Nat Commun* 2018; 9: 25.
2. Collamer AN, Guerrero KT, Henning JS, Battafarano DF. Psoriatic skin lesions induced by tumor necrosis factor antagonist therapy: a literature review and potential mechanisms of action. *Arthritis Rheum* 2008; 59: 996–1001.
3. Mylonas A, Conrad C. Psoriasis: classical vs. paradoxical. The yin-yang of TNF and type I interferon. *Front Immunol* 2018; 9: 2746.
4. Morelli M, Scarponi C, Madonna S, Albanesi C. Experimental methods for the immunological characterization of paradoxical psoriasis reactions induced by TNF- α biologics. *Methods Mol Biol* 2021; 2248: 155–165.
5. Dequidt L, Cogrel O, Guillet S, Milpied B, Darrigade A S, Beylot-Barry M, et al. Paradoxical psoriasiform reactions to antitumor necrosis factor- α drugs in hidradenitis suppurativa. *Br J Dermatol* 2018; 178: 281–283.
6. Vural S, Gündoğdu M, Gökpınar IE, Durmaz CD, Vural A, Steinmüller-Magin L, et al. Association of pyrin mutations and autoinflammation with complex phenotype hidradenitis suppurativa: a case-control study. *Br J Dermatol* 2019; 180: 1459–1467.
7. Nakazawa Y, Sasaki K, Mitsutake N, Matsuse M, Shimada M, Nardo T, et al. Mutations in UVSSA cause UV-sensitive syndrome and impair RNA polymerase II processing in transcription-coupled nucleotide-excision repair. *Nat Genet* 2012; 44: 586–592.
8. Nomura T. Hidradenitis suppurativa as a potential subtype of autoinflammatory keratinization disease. *Front Immunol* 2020; 11: 847.
9. Marzano AV, Damiani G, Ceccherini I, Berti E, Gattorno M, Cugno M. Autoinflammation in pyoderma gangrenosum and its syndromic form (pyoderma gangrenosum, acne and suppurative hidradenitis). *Br J Dermatol* 2017; 176: 1588–1598.
10. Shoham NG, Centola M, Mansfield E, Hull KM, Wood G, Wise CA, et al. Pyrin binds the PSTPIP1/CD2BP1 protein, defining familial Mediterranean fever and PAPA syndrome as disorders in the same pathway. *Proc Natl Acad Sci USA* 2003; 100: 13501–13506.
11. Nishimori N, Hayama K, Kimura K, Fujita H, Fujiwara K, Terui T. A novel NCSTN gene mutation in a Japanese family with hidradenitis suppurativa. *Acta Derm Venereol* 2020; 100: adv00283.
12. Kelly G, Hughes R, McGarry T, van den Born M, Adamzik K, Fitzgerald R, et al. Dysregulated cytokine expression in lesional and nonlesional skin in hidradenitis suppurativa. *Br J Dermatol* 2015; 173: 1431–1439.
13. Fania L, Morelli M, Scarponi C, Mercurio L, Scopelliti F, Cattani C, et al. Paradoxical psoriasis induced by TNF- α blockade shows immunological features typical of the early phase of psoriasis development. *J Pathol Clin Res* 2020; 6: 55–68.
14. de Gannes GC, Ghoreishi M, Pope J, Russell A, Bell D, Adams S, et al. Psoriasis and pustular dermatitis triggered by TNF- α inhibitors in patients with rheumatologic conditions. *Arch Dermatol* 2007; 143; 2: 223–231.