

## Transient Increase in Circulating Basophils and Eosinophils in Dupilumab-associated Conjunctivitis in Patients with Atopic Dermatitis

Michie KATSUTA<sup>1</sup>, Yoza ISHIIJI<sup>1\*</sup>, Hiroyuki MATSUZAKI<sup>1</sup>, Ken-ichi YASUDA<sup>1</sup>, Budiman KHARMA<sup>2</sup>, Yoshimasa NOBEYAMA<sup>1</sup>, Takaaki HAYASHI<sup>3</sup>, Yoshiki TOKURA<sup>4</sup> and Akihiko ASAHINA<sup>1</sup>

<sup>1</sup>Department of Dermatology, The Jikei University School of Medicine, 25-8 Nishi-Shimbashi 3-chome, Minato-ku, Tokyo 105-8461, Japan, <sup>2</sup>Genomik Solidaritas Indonesia Laboratory, Jakarta, Indonesia, <sup>3</sup>Department of Ophthalmology, The Jikei University School of Medicine, Tokyo, Japan and <sup>4</sup>Department of Cellular & Molecular Anatomy, Hamamatsu University School of Medicine, Hamamatsu, Japan. \*E-mail: yozaishiuji@gmail.com

Accepted May 26, 2021; Epub ahead of print May 27, 2021

Dupilumab is effective and safety for the patients with atopic dermatitis (AD), but 8.6–38.2% of patients experience conjunctivitis during treatment (1,2). Thus, physicians who treat AD need to be able to predict the occurrence of dupilumab-associated conjunctivitis (DAC).

The aim of this study was to investigate predictive or relevant circulating leukocyte populations in DAC in patients with AD.

### MATERIALS AND METHODS

To delineate the clinical parameters associated with the occurrence of DAC, this study retrospectively investigated the clinical course of 28 patients with AD who were treated with dupilumab and completed a 6-months period of treatment between August 2018 and May 2019. The study was approved by Institutional Review Board (IRB) of The Jikei University School of Medicine. All patients were treated with dupilumab (300 mg every other week). DAC was defined as the presence of conjunctival hyperaemia, tearing and pruritus (3, 4). Notably, the patients were strictly monitored for ocular manifestations every 2 weeks over a period of 6 months, with no missing data.

To determine the characteristics of the patients who developed DAC, patients with DAC were compared those without DAC for various clinical parameters. The presence of a previous history of ocular disease was checked, and the severity of facial eczema was assessed using the head and neck portions of the Eczema Area and Severity Index (EASI) score was recorded at the initiation of dupilumab treatment. To evaluate the chronological changes in individual leukocyte subsets, the ratio to the pre-treatment basal level was calculated at each time-point. The peripheral blood examination was performed just before and at 1, 2, 3 and 6 months after initiation of dupilumab treatment. The correlation between the severity, evaluated according to conjunctival hyperaemia, and the basophil ratio in the DAC group at 3 months was examined (4). Statistical analysis was performed with commercially available software, SPSS version 22 (SPSS Japan, Tokyo, Japan). Friedman test was used to determine whether value change was dependent on time. Mann–Whitney *U* test was used to determine differences in values between patients with AD with conjunctivitis and

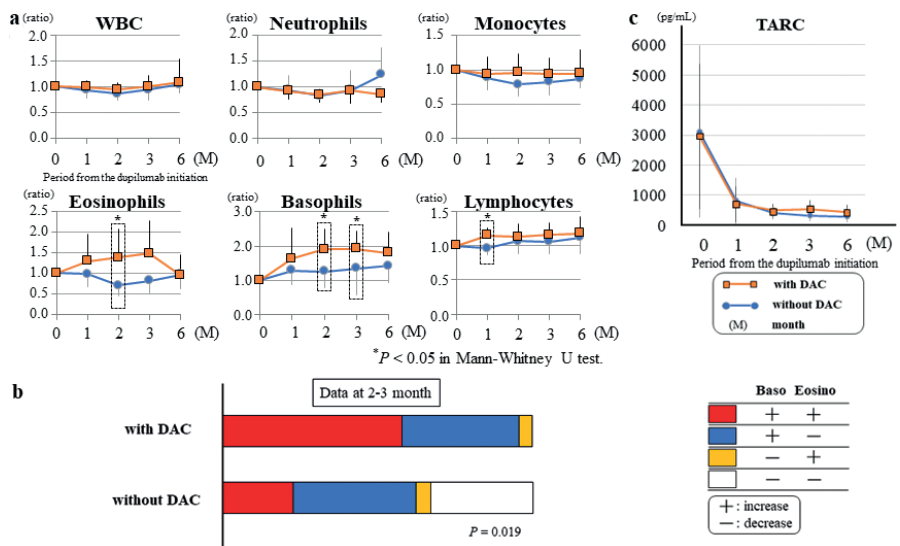
those without conjunctivitis.  $p < 0.05$  was considered statistically significant.

### RESULTS AND DISCUSSION

DAC occurred in 61% (17/28) of patients. The mean  $\pm$  standard deviation (SD) of the duration from the dupilumab initiation to the onset of ocular symptoms was  $1.63 \pm 2.77$  months (range 0.5–5.5 months) (Fig. S1<sup>1</sup>). Due to the transient nature of DAC, discontinuation of dupilumab treatment was unnecessary. Our patients with DAC showed pronounced palpebral hyperaemia (Fig. S2<sup>1</sup>). The higher incidence of DAC in the current study compared with previous research (1, 2) is probably due to the detailed evaluation, including the identification of minor DAC.

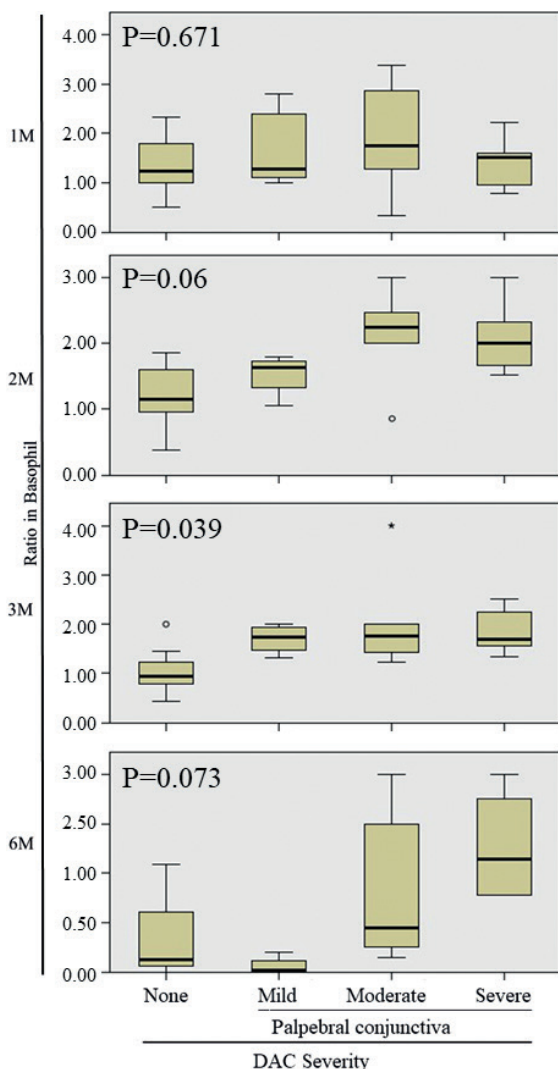
Fifty-nine percent (10/17) of the patients with DAC had a previous history of ocular complications, compared with

<sup>1</sup><https://www.medicaljournals.se/acta/content/abstract/10.2340/00015555-3842>



**Fig. 1. Dynamic of circulating leukocyte subsets and serum Thymus and activation-regulated chemokine (TARC) level during dupilumab treatment.** (a) Time-course of numerical changes of each subset of peripheral blood leukocytes. The ratio to the pre-treatment basal level was calculated at each time-point. Vertical bars indicate standard deviation (SD). (b) Incidence of dupilumab-induced elevation of circulating basophils and eosinophils in patients with atopic dermatitis with or without dupilumab-associated conjunctivitis (DAC). (+) and (-) indicate increase and decrease of individual leukocyte subsets compared with the baseline values, respectively. (c) Time-course changes in serum TARC/CCL17 level in DAC and non-DAC groups. Vertical bars indicate SD. Horizontal axis indicates period from the initiation of dupilumab administration.

18% (2/11) of those without DAC (Table S1<sup>1</sup>), suggesting that DAC occurs in ocular complication-prone individuals (odds ratio (OR)=6.4, 95% CI 1.051–39.329). Allergic conjunctivitis and atopic keratoconjunctivitis are potentially associated with pre-existing dry eyes accompanied by goblet cell (GC) depletion (5, 6). Dogru et al. (7), reported that ocular surface disorders of AD, characterized by GC loss and conjunctival hyperaemia, showed low breakup time (BUT). BUT is a test to evaluate eye dryness, which is recorded as time between the last blink and appearance of the first dry spot in the tear film coloured with fluorescein. Also, patients with DAC were reported to have a shortened BUT (8). The suppression of goblet cell proliferation and mucin secretion by dupilumab (9, 10) may contribute to the development of DAC. Conjunctiva-dominated hyperaemia in DAC may be the reason that the conjunctival area, in which higher density of goblet cells are located, are affected by dupilumab (11).



**Fig. 2. Severity of conjunctival hyperaemia and ratio in basophil.** Vertical axes indicate values of the severity of conjunctival hyperaemia. Horizontal axes indicate a ratio in basophil. Severe: impossible to distinguish individual blood vessels; Moderate: dilatation of many vessels; Mild: dilatation of several vessels. M: months.

These findings raise the possibility that a previous history of dry eye-related ocular diseases is related to GC abnormalities, which are further exaggerated by dupilumab. In line with this notion, the high incidence of DAC is notably seen only in AD and is less likely in other allergic diseases, such as asthma or nasal polyps (1).

To elucidate the changes in circulating parameters through dupilumab treatment, the ratio of each differential leukocyte count based on the data before the dupilumab treatment was compared between the groups with and without DAC (Fig. 1a). The transient elevation of blood eosinophils during dupilumab treatment is well documented, possibly due to inhibition of eosinophil infiltration to the skin (12). The current study found that the increase in eosinophils was more obvious in patients with DAC than those without DAC, and their ratio was significantly higher at 2 months. Indeed, Bakker et al. (8) reported that conjunctival infiltration of numerous lymphocytes and eosinophils with marked depletion of goblet cells.

More importantly, the current study found a significant elevation of circulating basophils at 2 and 3 months after initiation of dupilumab treatment in patients with DAC compared with those without DAC (Fig. 1a). There were no studies focusing on blood basophils in patients with AD treated with dupilumab. The peak of circulating basophil ratio coincided with the occurrence of DAC (Fig. 1a and Fig. S1<sup>1</sup>). In most of the cases with DAC, both basophils and eosinophils, or basophils alone, were increased, and elevation of eosinophils alone was rarely seen (Fig. 1b). The serum level of Th2 chemokine, thymus and activation-regulated chemokine (TARC)/CCL17, was rapidly and dramatically decreased in both groups (Fig. 1c), and there was no association of TARC with the basophil fluctuation. The current study also found that the basophil ratio was significantly higher in the severe DAC group compared with the mild group at 3 months (Fig. 2). Furthermore, there was a tendency for an increase in absolute basophil count with the severity of ocular hyperaemia at 3 months, which was statistically not significant (data not shown). Imai et al. reported that basophils could modulate eosinophil involvements in the pathogenesis of AD through interleukins 5 and 33(13). These data strongly suggest that basophils have critical roles in the development of DAC.

In conclusion, this study suggests that a history of ocular disease is important to predict the occurrence of DAC. The change of circulating basophils may serve as a novel surrogate marker for monitoring DAC.

*The authors have no conflicts of interest to declare.*

## REFERENCES

1. Akinlade B, Guttman-Yassky E, de Bruin-Weller M, Simpson EL, Blauvelt A, Cork MJ, et al. Conjunctivitis in dupilumab clinical trials. *Br J Dermatol* 2019; 181: 459–473.
2. Faiz S, Giovannelli J, Podevin C, Jachiet M, Bouaziz JD, Reguiai Z, et al. Effectiveness and safety of dupilumab for the treatment of atopic dermatitis in a real-life French multicenter adult cohort. *J Am Acad Dermatol* 2019; 81: 143–151.

3. Nahum Y, Mimouni M, Livny E, Bahar I, Hodak E, Leshem YA. Dupilumab-induced ocular surface disease (DIOSD) in patients with atopic dermatitis: clinical presentation, risk factors for development and outcomes of treatment with tacrolimus ointment. *Br J Ophthalmol* 2020; 104: 776–779.
4. Takamura E, Uchio E, Ebihara N, Ohno S, Ohashi Y, Okamoto S, et al. Japanese guidelines for allergic conjunctival diseases 2017. *Allergol Int* 2017; 66: 220–229.
5. Toda I, Shimazaki J, Tsubota K. Dry eye with only decreased tear break-up time is sometimes associated with allergic conjunctivitis. *Ophthalmology* 1995; 102: 302–309.
6. Chen JJ, Applebaum DS, Sun GS, Pflugfelder SC. Atopic keratoconjunctivitis: A review. *J Am Acad Dermatol* 2014; 70: 569–575.
7. Dogru M, Katakami C, Nakagawa N, Tetsumoto K, Yamamoto M. Impression cytology in atopic dermatitis. *Ophthalmology* 1998; 105: 1478–1484.
8. Touhouche AT, Cassagne M, Berard E, Giordano-Labadie F, Didier A, Fournie P, et al. Incidence and risk factors for dupilumab associated ocular adverse events: a real-life prospective study. *J Eur Acad Dermatol Venereol* 2021; 35: 172–179.
9. Bakker DS, Ariens LFM, van Luijk C, van der Schaft J, Thijs JL, Schuttelaar MLA, et al. Goblet cell scarcity and conjunctival inflammation during treatment with dupilumab in patients with atopic dermatitis. *Br J Dermatol* 2019; 180: 1248–1249.
10. Voorberg AN, den Dunnen WFA, Wijdh RHJ, de Bruin-Weller MS, Schuttelaar MLA. Recurrence of conjunctival goblet cells after discontinuation of dupilumab in a patient with dupilumab-related conjunctivitis. *J Eur Acad Dermatol Venereol* 2020; 34: e64–e66.
11. Kessing SV. Mucous gland system of the conjunctiva. A quantitative normal anatomical study. *Acta Ophthalmol (Copenh)* 1968: Suppl 95: 91+.
12. Wollenberg A, Beck LA, Blauvelt A, Simpson EL, Chen Z, Chen Q, et al. Laboratory safety of dupilumab in moderate-to-severe atopic dermatitis: results from three phase III trials (LIBERTY AD SOLO 1, LIBERTY AD SOLO 2, LIBERTY AD CHRONOS). *Br J Dermatol* 2020; 182: 1120–1135.
13. Imai Y, Yasuda K, Nagai M, Kusakabe M, Kubo M, Nakanishi K, et al. IL-33-induced atopic dermatitis-like inflammation in mice is mediated by group 2 innate lymphoid cells in concert with basophils. *J Invest Dermatol* 2019; 139: 2185–2194.e3.