

# Locoregional Treatments for Digital Ulcers in Systemic Sclerosis: A Systematic Review

Ingrid COSTEDOAT<sup>1#</sup>, Maeva MASSON<sup>2#</sup>, Thomas BARNETCHE<sup>2</sup>, Pierre DUFFAU<sup>3,5</sup>, Estibaliz LAZARO<sup>3,4</sup>, Christophe RICHEZ<sup>2,3</sup>, Julien SENESCHAL<sup>1§</sup> and Marie-Elise TRUCHETET<sup>2,3§</sup>

<sup>1</sup>Department of Dermatology and Paediatric Dermatology, National Reference Center for Rare Skin Diseases, Saint-André Hospital, <sup>2</sup>Department of Rheumatology, Pellegrin Hospital, <sup>3</sup>Immunology Laboratory, ImmunoConcept, UMR CNRS 5164, University Hospital of Bordeaux, Bordeaux, <sup>4</sup>Department of Internal Medicine, Haut-Lévêque, University Hospital of Bordeaux, Pessac and <sup>5</sup>Department of Internal Medicine, Saint-André Hospital, University of Bordeaux, Bordeaux, France

<sup>#</sup>These authors contributed equally to the study. <sup>§</sup>These authors contributed equally to the study.

**The management of digital ulcers in systemic sclerosis is difficult. While the 2017 European League Against Rheumatism (EULAR) guidelines clearly defined the use of systemic therapies for digital ulcers, little is known about the efficacy of locoregional treatments. The aim of this review is to systematically assess the spectrum of published locoregional therapies for digital ulcers. A total of 58 studies were included. Among the different locoregional treatment strategies described, injections of fat-derived cells and botulinum toxin showed promising results in the reduction of pain and the number of digital ulcers. By contrast, this review found that sympathectomy yielded disappointing results, with low rates of effectiveness and frequent recurrence. For other treatments, such as hyperbaric oxygen therapy, phototherapy (ultraviolet A), low-level light therapy, intermittent compression, Waon therapy, extracorporeal shockwave, vitamin E gel, and topical dimethyl sulphoxide, the conflicting results or limited published data reflected the low level of evidence. Larger randomized clinical trials are required to confirm the validity of promising techniques.**

**Key words:** systemic sclerosis; digital ulcers; systematic review; botulinum toxin; fat-derived cells.

Accepted May 26, 2021; Epub ahead of print May 27, 2021

Acta Derm Venereol 2021; 101: adv00478.

**Corr:** Marie Elise Truchetet, Department of Rheumatology, University Hospital of Bordeaux, Place Amélie Raba Léon, FR-33000 Bordeaux. E-mail: marie-elise.truchetet@chu-bordeaux.fr

Systemic sclerosis (SSc) is a chronic, systemic autoimmune disease associated with high morbidity and mortality. The disease is characterized by fibrosis of the skin and internal organs associated with vascular abnormalities and increased activation of the immune system. One of the first symptoms of SSc is the development of secondary Raynaud's phenomenon (RP) followed by digital ulcers (DUs), which occur in almost 50% of patients (1). DUs are a major burden for patients with SSc as they greatly impair quality of life and are associated with significant morbidity, including increased risk of cutaneous infection and osteitis. In a previous systematic review and meta-analysis, we showed that the presence of DUs may be associated with a higher

## SIGNIFICANCE

The management of digital ulcers associated with systemic sclerosis is difficult. In addition to systemic therapies, several locoregional treatments have been proposed, but their efficacy remains poorly established. This systematic review provides evidence that injections of fat-derived cells or botulinum toxin show promising results that need to be confirmed in larger studies.

mortality in patients with SSc (2). The management of vascular DUs is difficult and time-consuming, as healing typically requires >2 months (3). In addition to local treatment, the latest European League Against Rheumatism (EULAR) recommendations propose the use of calcium channel blockers and endothelin receptor antagonist (Bosentan) for the prevention of new DUs (strength of recommendation A), and prostacyclin analogue (Iloprost) and anti-phosphodiesterase 5 for healing (strength of recommendation A) (4, 5). However, the results of these approaches are often disappointing. Indeed, large randomized studies have suggested that approximately two-thirds of patients with new ulcers will experience recurrence within 16–24 weeks (6, 7), and no drug has demonstrated a positive effect on refractory DUs.

This therapeutic deficit has generated interest in the development of locoregional treatments, but the efficacy is less well established than for conventional treatments.

In this context, a systematic review was conducted to assess the effectiveness of locoregional therapy of DUs in patients with SSc. Two outcome measures were defined: DU healing and pain improvement. The safety of the examined treatments was also reported.

## METHODS

This systematic review was conducted in accordance with the PRISMA guidelines and is registered with PROSPERO (CRD42019132912).

### Data source and search strategy

A literature search was conducted using PubMed and Embase for studies published until February 2019 with no research start limit. The searches were limited to findings in humans. There were no

limitations regarding publication dates, study type, or age. Only studies published in English, French, or Spanish were considered. The following keywords were used: ((systemic sclerosis) AND digital ulcers) AND treatment for PubMed, and (“systemic sclerosis”/exp AND “finger ulcer”/exp AND (“therapy”/exp OR therapeutics)), excluding Medline records for Embase. An additional search was performed for each treatment found through the initial search. In addition, the reference lists of identified articles and grey literature sources were searched manually, including the databases of ClinicalTrials.gov, the American College of Rheumatology (ACR), EULAR, American Academy of Dermatology (AAD), and the European Academy of Dermatology and Venereology (EADV) Congress.

#### Selection criteria

Included in this review were randomized and non-randomized controlled trials (RCTs and NRCTs, respectively), prospective and retrospective studies, case series and case reports. Articles were included if they presented results of the treatment of DUs in patients with SSc and mixed connective tissue disease (MCTD) with a scleroderma phenotype. Abstracts and trials from proceedings were included when they contained the necessary data. The exclusion criteria were; involvement other than DUs and systemic treatment. After the removal of duplicate articles, 2 independent authors (IC and MM) reviewed all titles and abstracts and then the full texts of the potentially relevant articles. Disagreements were resolved by consensus or by a third party (MET and JS).

#### Data extraction

Data were extracted from the selected studies independently by 2 of the authors (IC and MM) using a standardized file. The following data were extracted from each article: number of patients, SSc characteristics (diffuse or limited form, prior treatment), study details (name of the first author, year of publication, name of the journal), study design, duration of follow-up, outcome measurements (healing time, reduction in DU, blood flow, blood flow assessment method, local temperature, visual analogue scale (VAS), amputation), and adverse events.

#### Quality and risk-of-bias assessment

Two reviewers (IC and MM) independently determined the quality and risk of bias of the selected studies. Quality assessment of randomized, controlled studies was performed using the Cochrane risk of bias tool (Fig. S1<sup>1</sup>), which addresses the following: method of sequence generation, method of allocation concealment, blinding of investigators and participants, blinding of outcome assessors, presence of incomplete outcome data, presence of selective reporting, and other biases, such as baseline imbalance. For each study, each domain was categorized as “low”, “high” or “unclear” risk of bias. Quality assessment of other individual studies was performed using the Newcastle-Ottawa Scale for cohort studies. Any discrepancies were addressed by joint re-evaluation of the original article (Fig. S2<sup>1</sup>).

#### Data analysis and synthesis

The following main outcomes were extracted: the healing time of the DU, the number of DUs, and pain improvement using the VAS. The following secondary outcomes were extracted when available: recurrence of DUs, local temperature, and adverse events were

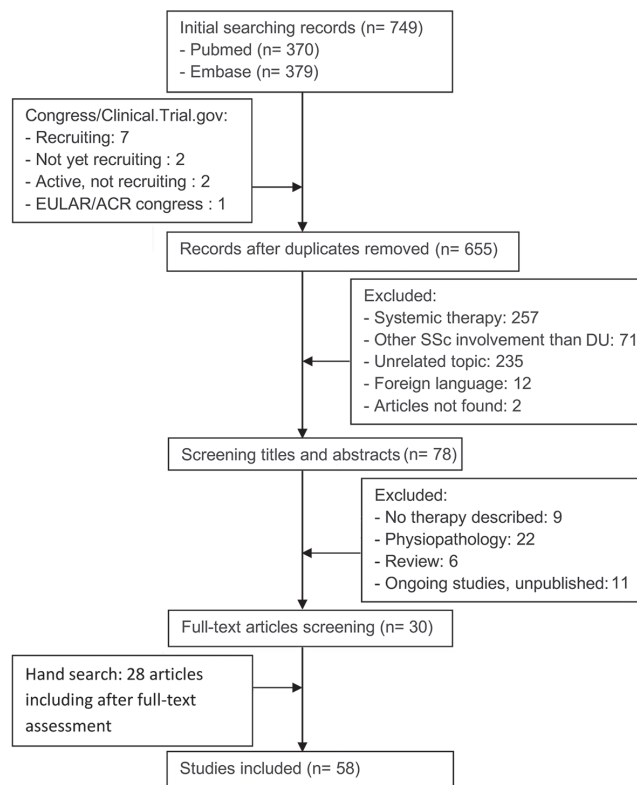
also reported. A paragraph and a table were dedicated to each technique, for which at least 5 studies were included in the review.

## RESULTS

### Search results and characteristics of eligible studies

The electronic database searches identified 749 citations (Fig. 1); after eliminating duplicates and adding grey literature, 655 articles were identified. After screening the abstracts, 577 studies were excluded due to irrelevance. An additional 48 studies were excluded after full-text assessment. Twenty-eight additional studies were identified by manual searching. Finally, 58 publications that fulfilled the inclusion criteria were selected.

The Cochrane risk of bias tool was used to assess the quality and risk of bias of the selected studies (Fig. S2<sup>1</sup>). The review included 5 RCTs (8–12) and 1 NRCT (13). The study quality was high for 2 studies (8, 9). Three RCTs were double-blind (8, 9, 12) and 1 single-blind (10). Three RCT were placebo-controlled (8, 9, 12). Thirty-two studies were evaluated with the Newcastle-Ottawa Scale, corresponding to 31 poor and 1 fair-quality studies according to Agency for Healthcare Research and Quality (AHR) standards. The remaining 21 studies were individual case reports and small case series.



**Fig. 1. Flow chart of study selection showing strategy used to include publications.** SSc: systemic sclerosis; EULAR/ACR: European League Against Rheumatism/American College of Rheumatology.

<sup>1</sup><https://www.medicaljournals.se/acta/content/abstract/10.2340/00015555-3839>

**Table I. Local implantation of autologous progenitor cells for treatment of digital ulcers (DUs) in systemic sclerosis**

Reference	Patients <i>n</i>	Study design	Results
Kamata et al. 2007 (18)	6	Uncontrolled cohort	Reduction in NRS in 4/6 patients at 1 month ( <i>the authors did not use VAS in their evaluations</i> )
Takahashi et al. 2009 (14)	22	Uncontrolled cohort	Improvement in ischaemic pain and DUs in 20/23 (87.0%) digits/limbs ( <i>the evaluation timeframes are not specified in this study</i> )
Neskaya et al. 2009 (16)	2	Case report	Reduction in VAS at 1 month of follow-up Complete healing of 7/10 DUs at 1 month of follow-up
Ishigatsubo et al. 2010 (17)	8	Uncontrolled cohort	Reduction in VAS in 6/8 patients at 6 months Complete healing in all patients (upper limb in 2 months and 6 months for lower limb)
Takagi et al. 2014 (15)	11 <sup>a</sup>	Uncontrolled cohort	VAS score significantly improved ( $p < 0.01$ ) at 1 month of follow-up

<sup>a</sup>Exclusion of arteriosclerosis obliterans.  
NRS: numerical rating scale; VAS: visual analogue scale.

### Results by technique

**Local implantation of autologous mononuclear cells.** Bone marrow and peripheral blood-derived mononuclear cells injections were examined in 5 studies involving 49 patients with DUs (including 23 patients in Takahashi et al. (14)), 4 uncontrolled cohorts, and one case report) and are summarized in **Table I**. The reported doses and injection techniques were highly variable, from 20 to 70 intramuscular injections into the ischaemic limb (14–18).

The main outcome of those studies was pain, and all reported an improvement. In the pilot study of Takahashi et al. (14), improvements in ischaemic pain and ulcers were reported in 87.0% of the digits/limbs of patients with SSc. In the patients evaluated by Takagi et al. (15), the VAS score decreased significantly, from 93 to 11 ( $p < 0.01$ ).

Ulcer healing was reported in only 2 pilot studies. In Nevskaya et al. (16), ulcer healing was reported in 7 out of 10 cases within 1 month of treatment.

No serious adverse events occurred, but the safety and efficacy of the local implantation of autologous progenitor cells have yet to be established. A double-blind RCT assessing the safety and potential efficacy of mesenchymal stromal cells for DUs is ongoing (19).

**Local implantation of adipose tissue-derived cells.** Seven studies involving 94 patients with DUs evaluated auto-

logous progenitor cell injection: 1 RCT, 6 uncontrolled cohorts (8, 20–25) and are summarized in **Table II**. The injection techniques and cell subtypes used varied.

In 3 of the preliminary studies, the VAS score decreased significantly. In an uncontrolled trial of 12 patients (20), the patients were treated with adipose tissue-derived stromal vascular fraction (AD-SVF) and the VAS score decreased by 41.7% at 6 months ( $p < 0.001$ ). Long-term follow-up data (22–30 months) for the endpoint of hand pain showed a 33.1% improvement over baseline (21).

In Del Papa et al. (22), 15 patients unresponsive to previous systemic and local treatment received a regional injection of autologous adipose tissue-derived cells. A rapid and significant reduction in pain intensity was reported at months 1, 3 and 6. Pain relief was rapid because, after one month, all patients had stopped their painkillers.

These studies on fat cell injection also demonstrated a decrease in the number of DUs. Granel et al. (20) reported a reduction in DU number (from 15 to 7) at 6 months in 12 patients with SSc. Del Papa et al. (22) indicated that grafting with autologous adipose tissue was effective for inducing healing of chronic DUs in all 15 patients (mean time to healing of the cardinal ulcer: 4.23 weeks). The effect was maintained during the following 6-month period, and no new DUs were observed.

**Table II. Loco-regional implantation of adipose tissue-derived cells for treatment of digital ulcers (DUs) in systemic sclerosis**

Reference	Patients <i>n</i>	Study design	Results
Bene et al. 2014 (25)	9 (15 DUs)	Uncontrolled cohort	Reduction in pain (allowing a reduction in analgesics) in 7 of 9 patients Complete healing of 10/15 DUs at 3 months
Del Papa et al. 2015 (22)	15 (15 DUs)	Uncontrolled cohort	Reduction in the VAS score at 1 month and 6 months ( $p < 0.001$ ) Complete healing of 15/15 DUs and no recurrence at 6 months Increased number of capillaries at 1 month ( $p < 0.0002$ ) and 6 months ( $p < 0.0001$ )
Faggioli et al. 2015 (24)	9 (10 DUs)	Uncontrolled cohort ( <i>Congress abstract</i> )	Complete healing of 6/10 DUs at 1 month
Bank et al. 2014 (23)	11 (14 DUs) <sup>a</sup>	Uncontrolled cohort	Pain results not interpretable because 2 patients with primary RP were included. Complete healing of 14/27 DUs (the healing assessment date is not specified in the article)
Granel et al. 2015 (20)	12 (15 DUs)	Uncontrolled cohort	Decrease in the VAS of 41.7% from the baseline at 6 months ( $p = 0.001$ ) Complete healing of 8/15 DUs at 6 months Capillaroscopy evaluation showed no significant change in the number of nail-fold capillary loops from baseline to 6 months
Daumas et al. 2017 (21)	12 (15 DUs) <sup>b</sup>	Uncontrolled cohort	At 24 months, a 33.1% decrease in the VAS score from baseline Complete healing of 9/15 DUs at last visit (> 24 months)
Del Papa et al. 2019 (8)	38 (38 DUs)	RCT	Placebo controlled-trial Reduction in the VAS score after 4 and 8 weeks ( $p < 0.0001$ ) Complete healing of 23/25 DUs after fat graft and 1/13 after the same procedure at 8 weeks ( $p < 0.0001$ ). Increase in capillary numbers in the affected finger after 4 and 8 weeks ( $p < 0.0001$ )

<sup>a</sup>Exclusion of patients with primary Raynaud phenomenon (RP). <sup>b</sup>Patients included in Granel's study – long-term follow-up (22–30 months after treatment)  
RCT: randomized controlled trial; VAS: visual analogue scale.

Del Papa et al. (8) confirmed their initial results in a randomized double-blind, placebo-controlled study, of 38 patients (25 who received autologous adipose tissue-derived cells and 13 a saline solution). Patients in the treatment group reported a significant reduction in pain (50% decrease in VAS score compared with baseline in 21/25 patients after 8 weeks of follow-up). DU healing was observed after 8 weeks in 23/25 patients vs 1/13 patients in the control group ( $p < 0.0001$ ). Twelve patients in the control group required rescue adipose tissue grafting, with DU healing achieved after 8 weeks in all of them. Patients in the treatment group also had a partial restoration of the capillary bed in the treated digits, as shown at weeks 4 and 8 by an increase in capillary numbers using nail-fold video capillaroscopy ( $p < 0.0001$ ).

The tolerance of the intervention was good, and side-effects were mild, including haematomas at the graft site, cellulitis at the fat donor site, and a transient numbness of the fingers (23). The injection technique used by Granel et al. (20) caused paraesthesia in one patient and finger pain in another, both of which resolved spontaneously.

Two randomized double-blind, placebo-controlled trials of local implantation of AD-SVF are currently being conducted (NCT02558543/NCT02396238).

**Botulinum toxin injection.** Eight studies including 159 patients, 73 with DUs (2 RCTs, 2 uncontrolled cohorts, 2 retrospective cohorts, and 2 case series) (9, 10, 26–31) and 4 case reports (32–35) analysed the efficacy and

tolerance of botulinum toxin (BT) injection, and are summarized in **Table III**. Both the number of BT units injected, and the injections sites differed between studies. Toxin A was used in most of the studies, and toxin B was used in one RCT (10) and one case report (32). In both RCTs, DU healing and a decrease in pain were assessed as secondary outcomes. Bello et al. (9) included 18 patients with DUs. The primary outcome was the change in blood flow from baseline at the 1-month follow-up examination. Blood flow decreased in BT-treated hands, but less than in placebo hands ( $p = 0.024$ ). The relative risk (RR) of developing new DUs was 1.27 (95% confidence interval: 0.68, 6 2.37), but it was not significant. Neither the healing time nor the number of DUs at the end of follow-up was reported. The change in the VAS pain score from baseline was not significantly different between the groups ( $p = 0.683$  at 1-month). In the second RCT (10), the primary outcome was the improvement of RP, using the RP score at week 4. Patients were divided into 4 groups (no-treatment, 250, 1,000 or 2,000 IU BT). The groups treated with BT injection had significantly lower RP scores than the control group ( $p < 0.05$  for 250 IU,  $p < 0.01$  for 1,000 and 2,000 IU BT). The number of DUs in the groups treated with 1,000 and 2,000 IU BT was significantly lower than in the control group at weeks 4 and 16. While 7 new DUs developed at week 16 in the control group, no new DUs were observed in the group treated

**Table III. Toxin botulinum injection for treatment of digital ulcers (DUs) in systemic sclerosis (SSc)**

Reference	Patients <i>n</i>	Study design	Results
Bello et al. 2017 (9)	40	Double-blind RCT	Placebo-controlled trial, 50 IU of BT-A No significant reduction in DUs at 1 month ( $p = 0.697$ ) and 4 months ( $p = 0.572$ ), likewise or VAS ( $p = 0.121$ and $p = 0.585$ , respectively)
Motegi et al. 2017 (10)	45	Single-blind RCT	Control group, and 3 treatment groups, using 250, 1,000 or 2,000 IU of BT-B Significant reduction in DUs and VAS at week 16 ( $p < 0.01$ )
Serri et al. 2013 (26)	18	Uncontrolled cohort	100 IU of BT-A Complete healing at 3 months Reduction in VAS: mean 6 at baseline, 2 at month 3
Uppal et al. 2014 (27)	20	Uncontrolled cohort	100 IU of BT-A Complete healing among 3 patients in 4 in 60 days No significant reduction in VAS
Fregene et al. 2009 (29)	7 SSc/MCTD among 26 patients	Retrospective cohort	100 IU of BT-A Complete healing among 11 patients in 60 days Follow-up between 1 and 45 months
Medina et al. 2018 (28)	9 SSc among 15 patients	Retrospective cohort	24 to 48 IU of BT-A Significant reduction in VAS ( $p < 0.005$ )
Motegi et al. 2016 (30)	10	Case series	10 IU of BT-A Complete healing in all patients with at month 12 Iloprost as additional treatment Decrease of VAS from a mean of 10 to 2
Van Beek et al. 2006 (31)	10 SSc/MCTD among 11 patients	Case series	40 to 50 IU of BT-A Complete healing of all small DUs Iloprost as additional treatment Reduction in VAS
Souk et al. 2019 (33)	2	Case report	10 IU of BT-A Complete healing in 5 weeks for the 1 <sup>st</sup> patient and 7 for the 2 <sup>nd</sup> one
Motegi et al. 2018 (32)	2	Case report	1,600 IU of BT-B Complete healing in 16 and 24 weeks Reduction in VAS from 10 in both patients to 1 and 2
Blaise et al. 2017 (35)	1	Case report	20 IU of BT-A Complete healing in 16 weeks Reduction in VAS
Berk-Krauss et al. 2018 (34)	1	Case report	100 IU of BT-A Partial healing

RCT: randomized controlled trial; VAS: visual analogue scale; MCTD: mixed connective tissue disease; BT: botulinum toxin; IU: International Unit.

with 1,000 and 2,000 IU BT. A significant impact of BT injection on the VAS score was also determined ( $p < 0.01$  with 1,000 and 2,000 IU) at 4 weeks, and the effect was maintained at 16 weeks.

Data extracted from other studies (10, 26–28, 30–33) showed healing in 87% patients, between day 30 and day 168 after injection. The safety of BT injection was good. The most common adverse event reported was pain for a few days after injection, and some patients reported transient muscle weakness. Two RCTs are currently being conducted to determine the efficacy and safety of local injection of BT: a phase II trial using BT type B for the management of DUs in SSc (NCT03007004) and a phase III trial using BT type A for the management of RP in SSc, in which DU healing and number are secondary outcomes (NCT03717961).

**Hyperbaric oxygen therapy and ozone therapy.** Only case series and case reports were available on the use of hyperbaric oxygen therapy (HOT) (36–41), which are summarized in **Table IV**. Among the 11 patients, complete healing was observed in 6 (36, 37, 39, 41), and partial healing was documented in 2 (35, 40). The number of required treatment sessions varied from 30 to 53, and the time to healing ranged from 21 to 240 days. HOT was associated with decreased pain (37, 41). Adverse events included 2 cases of barotraumatic otitis (38, 40) and a transient myopia lasting 3 weeks (41). No further adverse events were described. In 1 patient, the disease course was marked by infection and bone necrosis leading to amputation (41).

Oxygen-ozone therapy for the management of DUs associated with SSc was evaluated in 1 RCT (11) in which 50 patients were randomized to either the oxygen-ozone or the control group. All patients were treated with calcium channel blockers. The experimental group received non-invasive oxygen-ozone therapy for 30 min per day for 20 days. Ulcer healing was the primary outcome. At baseline, 25 DUs were present in each group. At day 20, wound healing was achieved for 7 DUs in the oxygen/ozone group vs 3 in the control group; the difference

was significant ( $p = 0.032$ ). The VAS score at day 20 was significantly lower in the oxygen/ozone group (7.98 vs 4.04,  $p < 0.05$ ). However, the follow-up period in that study was only 20 days.

**Sympathectomy.** Surgical treatment of DUs included thoracic, cervical and digital sympathectomy. RCTs evaluating this technique have yet to be conducted. Cervicothoracic sympathectomy was described in 2 studies (42, 43), but the long-term results were discouraging, as demonstrated in a retrospective study (44). In the 8 patients who underwent surgery, complete healing of already established DUs was not achieved and the formation of new DUs was not prevented.

Thirteen studies (4 prospective uncontrolled cohorts, 9 retrospective cohorts), including a total of 128 patients with DUs, and 5 case reports analysed the efficacy and tolerance of digital sympathectomy (45–62) and are summarized in **Table V**. In Ruch et al. (45), among the 22 patients, only 6 remained ulcer free after a mean follow-up of 31 months. Amputation was performed in 6 patients. Hartzell et al. (46) conducted a retrospective study of 20 patients with SSc and MCTD. Complete healing was observed in 15 patients, but 11 of the 42 (26%) digits required amputation. Momeni et al. (47) published a retrospective analysis of 17 patients (26 hands); complete healing was obtained in all of them, with DU recurrence 6 months after the procedure reported in 2 patients.

Based on the data obtained from all studies, the time to obtain complete healing ranged from 26 days to 1 year. The recurrence rate 1 year after surgery was 23%. Sympathectomy provided a subjective pain decrease, but only temporarily. A pain scale was used only in 2 studies. In Stratton et al. (48) the scale ranged from 0 to 4, with patients reporting a decrease from 3.9 before surgery to 3.2 after surgery. In Tomaino et al. (49), the VAS score decreased from 9 (range 4–10) before surgery to 1 (range 0–3) at month 6 and 2 (range 0–5) at final review (mean 2.5 years). Amputation was required in 10% of the patients (data reported in 12 studies) (42, 44, 49–53, 55, 57, 59–61).

**Table IV. Hyperbaric oxygen therapy for treatment of digital ulcers (DUs) in systemic sclerosis (SSc)**

Reference	Patients, <i>n</i>	Study design	Results
Hassanien et al. 2018 (11)	50	RCT	All patients treated by calcium channel blockers Higher rate of complete healing at day 20 ( $p = 0.032$ ) No effect on VAS ( $p = 0.16$ ) Follow-up <1 month
Mirasoglu et al. 2017 (36)	6	Case series	1 session per day, 5 days a week Complete healing in 4 patients after 40 mean sessions Partial healing for 2 patients after 42 mean sessions
Ueno et al. 2014 (38)	1 SSc (among 29 patients)	Case series	30% reduction in DUs size
Dowling et al. 1967 (41)	6	Case series	2 sessions per day 4 patients with DUs Complete healing for 2 patients in 3 weeks, relapse for another one, amputation for the last one
Poirier et al. 2017 (37)	1	Case report	DU healing at month 8
Gerodimos et al. 2013 (39)	1	Case report	DUs healing in 1 month No relapse at month 6
Markus et al. 2006 (40)	1	Case report	Complete healing for 1 DU, partial for the second one at the end of treatment Persistence of 1 DU at month 6

RCT: randomized controlled trial; VAS: visual analogue scale.

**Table V. Sympathectomy for treatment of digital ulcers (DUs) in systemic sclerosis (SSc)**

Reference	Patients <i>n</i>	Study design	Results
Ruch et al. 2002 (45)	22	Uncontrolled cohort	Mean follow-up: 46 months Complete healing in 6/22 patients 4 amputations in 3 patients
Tham et al. 1997 (52)	6	Uncontrolled cohort	Reduction in pain in 18 patients Complete healing in 2/3 DUs Mean of healing time for 27 days No recurrence during follow-up (12–29 weeks)
Ward et al. 1995 (50)	7	Uncontrolled cohort	Complete healing in 6 weeks Recurrence in 2 patients (3 hands) Persistent pain in 3 patients
O'Brien et al. 1992 (51)	11 SSc among 13 patients	Uncontrolled cohort	Complete healing in all patients Recurrence in 4 patients
Momeni et al. 2015 (47)	16	Retrospective cohort	Complete healing in all patients Recurrence in 2 patients at month 6 and year 4, respectively 3 wound infections, 2 wound openings, 2 stitch abscesses
Hartzell et al. 2009 (46)	17 SSc/3MCTD	Retrospective cohort	Complete healing in 28/42 DUs 11 digital amputations Mean follow-up: 90 months
Agarwal et al. 2005 (59)	6	Retrospective cohort	Complete healing in 9 of 11 DUs at month 20 Relief of pain
Tomaino et al. 2001 (49)	6	Retrospective cohort	Decrease of VAS from a mean of 9 to 1 at month 6 7 digital amputations 2 wound delay healing
McCall et al. 1999 (54)	4 SSc among 7 patients	Retrospective cohort	Complete healing in all patients, recurrence in 2 patients Mean healing time: 14 weeks Recurrent infection in 1 patient
Stratton et al. 1997 (48)	13	Retrospective cohort	No reduction in number of DUs. Mean follow-up: 19 months Pain reduction from 3.9 to 3.2 (scale from 0 to 4)
Koman et al. 1995 (61)	6	Retrospective cohort	Complete healing in 6/7 DUs at month 6 Pain relief in all patients
Jones et al. 1987 (53)	5	Retrospective cohort	Data on DU or pain not available. 2 partial amputations in 1 patient
Gahhos et al. 1984 (44)	59 (8 operations)	Retrospective cohort	No symptomatic relief in 3 patients No healing, appearance of new DUs
Flatt et al. 1980 (55)	2 SSc/MCTD among 8 patients	Retrospective cohort	Partial healing Pain relief, raised local temperature
Wasserman et al. 2010 (57)	1	Case report	Complete healing in 3 months No recurrence within 1 year
Volchok et al. 2005 (43)	1	Case report	Complete healing at 1 year, no recurrence
Greengrass et al. 2003 (42)	1	Case report	Nerve block of ropivacaine, no recurrence
Tomaino et al. 2002 (62)	2	Case report	Complete healing in 6 weeks for patient 1, 14 for patient 2 Patient 1: wound haematoma and dehiscence
Hafner et al. 1997 (58)	2	Case report	Patient 1: pain relief, recovery of digital systolic pressure, no follow-up Patient 2: pain relief, complete healing in 4 weeks, no recurrence at year 2
Van Den Broecke et al. 1997 (56)	1	Case report	Recurrence in 2 fingertips, 1 phalangeal amputation
El Gammal et al. 1991 (60)	1	Case report	No healing or pain reduction 1 finger amputation

RCT: randomized controlled trial; VAS: visual analogue scale; MCTD: mixed connective tissue disease.

The main adverse events were infection and the delayed healing of surgical scars. Data on complications/adverse events, excluding amputations, were not reported in 8 studies. There was a large discrepancy among and within studies regarding the length of follow-up after surgery (3–96 months).

**Other treatments.** Four other techniques were described in the included studies, but few data were available regarding their efficacy and tolerance.

An observational study and one case report described the use of ultraviolet A (UVA) phototherapy in a total of 12 patients (63, 64). In the clinical case report, complete healing was achieved in a patient treated 3 times per week for 4 weeks, with a cumulative dose of 23 J/cm<sup>2</sup>. In the observational study, patients had a 50% decrease in pain, but the data were insufficient to draw conclusions regarding healing of the DUs.

Shock-wave therapy was administered to 9 patients in an observational study including 9 patients and 60 patients in a NRCT (30 patients in the shock-wave therapy arm and 30 in the conventional treatment arm

or standard of care) (13, 65). The NRCT data were reported only in an abstract and were therefore limited. A significant decrease in the number of DUs at week 8 was reported with a mean decrease in the number of DUs of 4.47 in the active group, compared with 0.83 in the conventional treatment group ( $p < 0.0001$ ). In the observational study, 9 patients were treated once a week for 9 weeks while also receiving conventional treatments (intravenous prostaglandin or oral vasodilators). The initial efficacy with respect to wound healing and pain at week 9 was evaluated. The mean number of DUs decreased from 5.4 to 1.1 at week 9 ( $p < 0.02$ ), but the results were not maintained over time. At 20 weeks, a mean of 2.2 DUs had reappeared in 4 patients.

The efficacy of locally dimethyl sulphoxide (DMSO) was evaluated in a randomized, double-blind trial of 84 patients assigned to the placebo, 2% DMSO or 70% DMSO group (12). The results were consistently negative, with no reduction in the number of DUs and poor skin tolerance.

Eight patients were treated with low-level light therapy (combining infrared, red, and violet light) twice

a week for 3 weeks (66). The VAS pain score improved by  $-7.1$  (95% confidence interval 8.6–5.7) units at each visit ( $p < 0.001$ ) and at the final study visit (week 8), the reduction in VAS compared with baseline was 82.8%.

Several techniques used to treat DUs, did not meet the criteria for inclusion in our review. For the record, these included topical vitamin E (67), Waon therapy (68), topical glyceryl trinitrate (69), iontophoresis (70–72), and transdermal nitroglycerine (73).

## DISCUSSION

This is the first systematic review to evaluate the efficacy and safety of locoregional therapy in the management of DUs in patients with SSc. Among the evaluated treatments 2 techniques were highlighted: the local implantation of progenitor cells or adipose tissue derived cells and botulinum toxin injection.

Fat cell injections may be a promising technique. Coleman et al. (74) proposed the use of fat grafting based on its potential tissue regenerating properties. Indeed, studies have shown that AD-SVF is a valuable source of cells expressing the multipotent, angiogenic, antifibrotic, and immunomodulatory properties, important for tissue repair (75–77). In addition, adipose tissue can be obtained relatively easily and offers an abundance of stem/stroma cells. These features suggest adipose-derived cell therapy as an attractive option, particularly for patients with ischaemic manifestations (78). While Granel et al. (20) and Del Papa et al. (8, 22) showed similar results in the use of fat cells to reduce pain and in ulcer healing, although 2 different techniques were used to purify the cells, namely AD-SVF fractionation and autologous adipose tissue-derived cells without the digestion of fat tissue, respectively (79–81). To date, the cellular composition and/or soluble factors important for achieving clinical benefits have yet to be fully defined. Moreover, the results are preliminary and remain to be validated in the ongoing RCTs (NCT02558543/NCT02396238).

Another promising technique is BT injection, as suggested by the results of an RCT (10). BT is produced by *Clostridium botulinum*, a Gram-positive anaerobic bacterium and binds presynaptically to high-affinity recognition sites on the cholinergic nerve terminals. In addition to decreasing the release of acetylcholine, BT suppresses the release of norepinephrine and the expression of adrenergic receptors on the vessel wall. Studies in animal models have reported that BTX-A causes an increase in blood flow (82, 83). There are 7 BTs that differ antigenically and serologically, but toxin A is the most commonly used in studies. Another RCT (9) included in the current review did not find significant reduction in DUs or pain improvement, but the BT injection site was more proximal and patients had larger vessel disease, such as radial or ulnar artery occlusion. Two RCTs are currently underway to assess the efficacy of BT injection

in patients with SSc (NCT03007004/NCT03717961). Importantly, BT injections are well tolerated, with few side-effects.

However, for all of the techniques their indications in the management of DUs in SSc must still be precisely defined in the context of conventional therapies, including whether they are best used alone or in combination with conventional treatments, and regarding possible side-effects/failures and/or contraindications.

This systematic review also showed that sympathectomy, while well documented in the literature, is not a reliable technique to manage DUs in SSc, based on its low rate of efficacy and the high rate of DU recurrence. Moreover, it is associated with high rates of side-effects. Thus, in the choice of techniques for the treatment of refractory DUs, sympathectomy should be placed at the bottom of the decision tree.

This study had several limitations. First, there was considerable heterogeneity across studies in terms of outcomes, evaluation criteria, procedures and protocols, which prevented combining the studies into a meta-analysis. Secondly, only 4 RCTs were identified. Among the studies with a low risk of bias, their limitations included a lack of blinding, the use of non-standardized outcome measures, small sample sizes and short follow-up times, all of which are potential sources of bias, suggesting potential bias. The remaining studies included in the current review were case reports that only suggested possible treatments. While they may guide future research, they cannot prove effectiveness. Finally, adverse reactions were rarely reported.

In conclusion, this review highlights 2 techniques: adipose cell derived and BT injections, which, in addition to conventional treatments, should be considered in the therapeutic options used to treat refractory DUs in patients with SSc.

*The authors have no conflicts of interest to declare.*

## REFERENCES

- Denton CP, Khanna D. Systemic sclerosis. *Lancet* 2017; 390: 1685–1699.
- Meunier P, Dequidt L, Barnette T, Lazaro E, Duffau P, Richez C, et al. Increased risk of mortality in systemic sclerosis-associated digital ulcers: a systematic review and meta-analysis. *J Eur Acad Dermatol Venereol* 2019; 33: 405–409.
- Hughes M, Herrick AL. Digital ulcers in systemic sclerosis. *Rheumatol Oxf Engl* 2017; 56: 14–25.
- Kowal-Bielecka O, Landewé R, Avouac J, Chwiesko S, Miniati I, Czirjak L, et al. EULAR recommendations for the treatment of systemic sclerosis: a report from the EULAR Scleroderma Trials and Research group (EUSTAR). *Ann Rheum Dis* 2009; 68: 620–628.
- Kowal-Bielecka O, Fransen J, Avouac J, Becker M, Kulak A, Allanore Y, et al. Update of EULAR recommendations for the treatment of systemic sclerosis. *Ann Rheum Dis* 2017; 76: 1327–1339.
- Korn JH, Mayes M, Matucci Cerinic M, Rainisio M, Pope J, Hachulla E, et al. Digital ulcers in systemic sclerosis: prevention by treatment with bosentan, an oral endothelin receptor antagonist. *Arthritis Rheum* 2004; 50: 3985–3993.

7. Matucci-Cerinic M, Denton CP, Furst DE, Mayes MD, Hsu VM, Carpentier P, et al. Bosentan treatment of digital ulcers related to systemic sclerosis: results from the RAPIDS-2 randomised, double-blind, placebo-controlled trial. *Ann Rheum Dis* 2011; 70: 32–38.
8. Del Papa N, Di Luca G, Andracco R, Zaccara E, Maglione W, Pignataro F, et al. Regional grafting of autologous adipose tissue is effective in inducing prompt healing of indolent digital ulcers in patients with systemic sclerosis: results of a monocentric randomized controlled study. *Arthritis Res Ther* 2019; 21: 7.
9. Bello RJ, Cooney CM, Melamed E, Follmar K, Yenokyan G, Leatherman G, et al. The therapeutic efficacy of botulinum toxin in treating scleroderma-associated Raynaud's phenomenon: a randomized, double-blind, placebo-controlled clinical trial. *Arthritis Rheumatol* 2017; 69: 1661–1669.
10. Motegi S-I, Uehara A, Yamada K, Sekiguchi A, Fujiwara C, Toki S, et al. Efficacy of botulinum toxin B injection for Raynaud's phenomenon and digital ulcers in patients with systemic sclerosis. *Acta Derm Venereol* 2017; 97: 843–850.
11. Hassani M, Rashad S, Mohamed N, Elawamy A, Ghaly MS. Non-invasive oxygen-ozone therapy in treating digital ulcers of patients with systemic sclerosis. *Acta Reumatol Port* 2018; 43: 210–216.
12. Williams HJ, Furst DE, Dahl SL, Steen VD, Marks C, Alpert EJ, et al. Double-blind, multicenter controlled trial comparing topical dimethyl sulfoxide and normal saline for treatment of hand ulcers in patients with systemic sclerosis. *Arthritis Rheum* 1985; 28: 308–314.
13. Ishii T, Kawaguchi Y, Ishikawa O, Takasaawa N, Koderia T, Yasuoka H, et al. Non-randomized controlled trial to evaluate the effect of extracorporeal shock wave therapy on digital ulcers in systemic sclerosis. Available from: <https://acrabstracts.org/abstract/non-randomized-controlled-trial-to-evaluate-the-effect-of-extracorporeal-shock-wave-therapy-on-digital-ulcers-in-systemic-sclerosis/>.
14. Takahashi M, Izawa A, Ishigatsubo Y, Fujimoto K, Miyamoto M, Horie T, et al. Therapeutic neovascularization by the implantation of autologous mononuclear cells in patients with connective tissue diseases. *Curr Pharm Des* 2009; 15: 2778–2783.
15. Takagi G, Miyamoto M, Tara S, Kirinoki-Ichikawa S, Kubota Y, Hada T, et al. Therapeutic vascular angiogenesis for intractable macroangiopathy-related digital ulcer in patients with systemic sclerosis: a pilot study. *Rheumatology* 2014; 53: 854–859.
16. Nevskaya T, Ananieva L, Bykovskaia S, Eremin I, Karandashov E, Khrennikov J, et al. Autologous progenitor cell implantation as a novel therapeutic intervention for ischaemic digits in systemic sclerosis. *Rheumatol Oxf Engl* 2009; 48: 61–64.
17. Ishigatsubo Y, Ihata A, Kobayashi H, Hama M, Kirino Y, Ueda A, et al. Therapeutic angiogenesis in patients with systemic sclerosis by autologous transplantation of bone-marrow-derived cells. *Mod Rheumatol* 2010; 20: 263–272.
18. Kamata Y, Takahashi Y, Iwamoto M, Matsui K, Murakami Y, Muroi K, et al. Local implantation of autologous mononuclear cells from bone marrow and peripheral blood for treatment of ischaemic digits in patients with connective tissue diseases. *Rheumatology (Oxford)* 2007; 46: 882–884.
19. Van Rhijn-Brouwer FCC, Gremmels H, Fledderus JO, Schuurman AH, Bonte-Mineur F, Vonk MC, et al. A randomised placebo-controlled double-blind trial to assess the safety of intramuscular administration of allogeneic mesenchymal stromal cells for digital ulcers in systemic sclerosis: the MANUS Trial protocol. *BMJ Open* 2018; 8: e020479.
20. Granel B, Dumas A, Jouve E, Harlé J-R, Nguyen P-S, Chabannon C, et al. Safety, tolerability and potential efficacy of injection of autologous adipose-derived stromal vascular fraction in the fingers of patients with systemic sclerosis: an open-label phase I trial. *Ann Rheum Dis* 2015; 74: 2175–2182.
21. Dumas A, Magalon J, Jouve E, Truillet R, Casanova D, Gi-raudo L, et al. Long-term follow-up after autologous adipose-derived stromal vascular fraction injection into fingers in systemic sclerosis patients. *Fundam Clin Pharmacol* 2017; 31: 65.
22. Del Papa N, Di Luca G, Sambataro D, Zaccara E, Maglione W, Gabrielli A, et al. Regional implantation of autologous adipose tissue-derived cells induces a prompt healing of long-lasting indolent digital ulcers in patients with systemic sclerosis. *Cell Transplant* 2015; 24: 2297–2305.
23. Bank J, Fuller SM, Henry GI, Zachary LS. Fat grafting to the hand in patients with Raynaud phenomenon: a novel therapeutic modality. *Plast Reconstr Surg* 2014; 133: 1109–1118.
24. Faggioli P, Saporiti E, Falaschi M, Mazzone A, Moscatelli A. Autologous fat grafting as treatment of scleroderma-induced digital ulcers and perioral sclerosis. Experience of a single center. *Ann Rheum Dis* 2015; 74: 1139.
25. Bene MD, Pozzi MR, Rovati L, Mazzola I, Erba G, Bonomi S. Autologous fat grafting for scleroderma-induced digital ulcers. An effective technique in patients with systemic sclerosis. *Handchir Mikrochir Plast Chir* 2014; 46: 242–247.
26. Serri J, Legré R, Veit V, Guardia C, Gay A-M. Intérêt de la toxine botulinique de type A dans le traitement des syndromes de Raynaud sévères secondaires à la sclérodémie systémique. *Ann Chir Plast Esthét* 2013; 58: 658–662.
27. Uppal L, Dhaliwal K, Butler PE. A prospective study of the use of botulinum toxin injections in the treatment of Raynaud's syndrome associated with scleroderma. *J Hand Surg Eur Vol* 2014; 39: 876–880.
28. Medina S, Gómez-Zubiaur A, Valdeolivas-Casillas N, Polo-Rodríguez I, Ruíz L, Izquierdo C, et al. Botulinum toxin type A in the treatment of Raynaud's phenomenon: a three-year follow-up study. *Eur J Rheumatol* 2018; 5: 224–229.
29. Fregene A, Ditmars D, Siddiqui A. Botulinum toxin type A: a treatment option for digital ischemia in patients with Raynaud's phenomenon. *J Hand Surg* 2009; 34: 446–452.
30. Motegi S, Yamada K, Toki S, Uchiyama A, Kubota Y, Nakamura T, et al. Beneficial effect of botulinum toxin A on Raynaud's phenomenon in Japanese patients with systemic sclerosis: a prospective, case series study. *J Dermatol* 2016; 43: 56–62.
31. Van Beek AL, Lim PK, Gear AJL, Pritzker MR. Management of vasospastic disorders with botulinum toxin A. *Plast Reconstr Surg* 2007; 119: 217–226.
32. Motegi S-I, Sekiguchi A, Saito S, Ishibuchi H, Kishi C, Yasuda M, et al. Successful treatment of Raynaud's phenomenon and digital ulcers in systemic sclerosis patients with botulinum toxin B injection: assessment of peripheral vascular disorder by angiography and dermoscopic image of nail fold capillary. *J Dermatol* 2018; 45: 349–352.
33. Souk J-W, Kim H-S. Effects of botulinum toxin injection on systemic sclerosis-related digital ulcers. *Korean J Intern Med* 2019; 34: 1169–1170.
34. Berk-Krauss J, Christman MP, Franks A, Sicco KL, Liebman TN. Botulinum toxin for treatment of Raynaud phenomenon in CREST syndrome. *Dermatol Online J* 2018; 24: 13030/qt9zr1318w.
35. Blaise S, Roustit M, Forli A, Imbert B, Cracowski J-L. Non-healing ischaemic digital ulcer in a systemic sclerosis patient: a challenging clinical case. *Int Wound J* 2017; 14: 978–981.
36. Mirasoglu B, Bagli BS, Aktas S. Hyperbaric oxygen therapy for chronic ulcers in systemic sclerosis – case series. *Int J Dermatol* 2017; 56: 636–640.
37. Poirier E, Wind H, Cordel N. Efficacité de l'oxygénothérapie hyperbare dans le traitement d'un ulcère nécrotique d'orteil au cours d'une sclérodémie systémique. *Ann Dermatol Vénérologie* 2017; 144: 55–59.
38. Ueno T, Omi T, Uchida E, Yokota H, Kawana S. Evaluation of hyperbaric oxygen therapy for chronic wounds. *J Nippon Med Sch* 2014; 81: 4–11.
39. Gerodimos C, Stefanidou S, Kotsiou M, Melekos T, Mesimeris T. Hyperbaric oxygen treatment of intractable ulcers in a systemic sclerosis patient. *Aristotle University Med* 2013; 40: 4.
40. Markus YM, Bell MJ, Evans AW. Ischemic scleroderma wounds successfully treated with hyperbaric oxygen therapy. *J Rheumatol* 2006; 33: 1694–1696.
41. Dowling GB, Copeman PW, Ashfield R. Raynaud's phenome-



- non in scleroderma treated with hyperbaric oxygen. *Proc R Soc Med* 1967; 60: 1268–1269.
42. Greengrass RA, Feinglass NG, Murray PM, Trigg SD. Continuous regional anesthesia before surgical peripheral sympathectomy in a patient with severe digital necrosis associated with Raynaud's phenomenon and scleroderma. *Reg Anesth Pain Med* 2003; 28: 354–358.
  43. Volchok J, Santamarina R, Sadighi P. Transaxillary thorascopically assisted sympathectomy for nonhealing ulcers in scleroderma: a case report of successful treatment. *Curr Surg* 2005; 62: 348–350.
  44. Gahhos F, Ariyan S, Frazier WH, Cuono CB. Management of sclerodermal finger ulcers. *J Hand Surg Am* 1984; 9: 320–327.
  45. Ruch DS, Holden M, Smith BP, Smith TL, Koman LA. Periarterial sympathectomy in scleroderma patients: intermediate-term follow-up. *J Hand Surg Am* 2002; 27: 258–264.
  46. Hartzell TL, Makhni EC, Sampson C. Long-term results of periarterial sympathectomy. *J Hand Surg Am* 2009; 34: 1454–1460.
  47. Momeni A, Sorice SC, Valenzuela A, Fiorentino DF, Chung L, Chang J. Surgical treatment of systemic sclerosis – is it justified to offer peripheral sympathectomy earlier in the disease process? *Microsurgery* 2015; 35: 441–446.
  48. Stratton R, Howell K, Goddard N, Black C. Digital sympathectomy for ischaemia in scleroderma. *Br J Rheumatol* 1997; 36: 1338–1339.
  49. Tomaino MM, Goitz RJ, Medsger TA. Surgery for ischemic pain and Raynaud's phenomenon in scleroderma: a description of treatment protocol and evaluation of results. *Microsurgery* 2001; 21: 75–79.
  50. Ward WA, Van Moore A. Management of finger ulcers in scleroderma. *J Hand Surg Am* 1995; 20: 868–872.
  51. O'Brien BM, Kumar PA, Mellow CG, Oliver TV. Radical microarteriolytic treatment of vasospastic disorders of the hand, especially scleroderma. *J Hand Surg Br* 1992; 17: 447–452.
  52. Tham S, Grossman JA. Limited microsurgical arteriolytic treatment for complications of digital vasospasm. *J Hand Surg Br* 1997; 22: 359–361.
  53. Jones NF, Imbriglia JE, Steen VD, Medsger TA. Surgery for scleroderma of the hand. *J Hand Surg Am* 1987; 12: 391–400.
  54. McCall TE, Petersen DP, Wong LB. The use of digital artery sympathectomy as a salvage procedure for severe ischemia of Raynaud's disease and phenomenon. *J Hand Surg Am* 1999; 24: 173–177.
  55. Flatt AE. Digital artery sympathectomy. *J Hand Surg Am* 1980; 5: 550–556.
  56. Van den Broeck D, Coessens BC, Peretz A. On surgical microarteriolytic treatment of Raynaud's phenomenon in scleroderma. *Br J Rheumatol* 1997; 36: 706–707.
  57. Wasserman A, Brahn E. Systemic sclerosis: bilateral improvement of Raynaud's phenomenon with unilateral digital sympathectomy. *Semin Arthritis Rheum* 2010; 40: 137–146.
  58. Hafner J, Santa DD, Zuber C, Christen Y, Bounameaux H. Digital sympathectomy (microarteriolytic) in the treatment of severe Raynaud's phenomenon secondary to systemic sclerosis. *Br J Dermatol* 1997; 137: 1019–1020.
  59. Agarwal J, Zachary L. Digital sympathectomy of the lower extremity: a novel approach to toe salvage. *Plast Reconstr Surg* 2005; 116: 1098–1102.
  60. El-Gammal TA, Blair WF. Digital periarterial sympathectomy for ischaemic digital pain and ulcers. *J Hand Surg* 1991; 16: 382–385.
  61. Koman LA, Smith BP, Pollock FE, Smith TL, Pollock D, Russell GB. The microcirculatory effects of peripheral sympathectomy. *J Hand Surg Am* 1995; 20: 709–717.
  62. Tomaino MM, King J, Medsger T. Rationale for and efficacy of digital arterial reconstruction in scleroderma: report of two cases. *J Reconstr Microsurg* 2002; 18: 263–268.
  63. Comte C, Bessis D, Picot E, Peyron J-L, Guillot B, Dereure O. Traitement des acrosyndromes des connectivites par phototherapie UVA-1. Etude ouverte de 11 cas. *Ann Dermatol Venereol* 2009; 136: 323–329.
  64. Inoue T, Yamaoka T, Murota H, Yokomi A, Tanemura A, Igawa K, et al. Effective oral psoralen plus ultraviolet a therapy for digital ulcers with revascularization in systemic sclerosis. *Acta Derm Venereol* 2014; 94: 250–251.
  65. Saito S, Ishii T, Kamogawa Y, Watanabe R, Shirai T, Fujita Y, et al. Extracorporeal shock wave therapy for digital ulcers of systemic sclerosis: a phase 2 pilot study. *Tohoku J Exp Med* 2016; 238: 39–47.
  66. Hughes M, Moore T, Manning J, Wilkinson J, Watson S, Samraj P, et al. A feasibility study of a novel low-level light therapy for digital ulcers in systemic sclerosis. *J Dermatolog Treat* 2019; 30: 251–257.
  67. Fiori G, Galluccio F, Braschi F, Amanzi L, Miniati I, Conforti ML, et al. Vitamin E gel reduces time of healing of digital ulcers in systemic sclerosis. *Clin Exp Rheumatol* 2009; 27: 51–54.
  68. Nishijima C, Inaoki M. Digital ulcer in systemic sclerosis successfully treated with Waon therapy. *Int J Rheum Dis* 2013; 16: 102–104.
  69. Hughes M, Moore T, Manning J, Wilkinson J, Dinsdale G, Roberts C, et al. Reduced perfusion in systemic sclerosis digital ulcers (both fingertip and extensor) can be increased by topical application of glyceryl trinitrate. *Microvasc Res* 2017; 111: 32–36.
  70. Murray AK, Moore TL, King TA, Herrick AL. Vasodilator iontophoresis a possible new therapy for digital ischaemia in systemic sclerosis? *Rheumatology* 2008; 47: 76–79.
  71. Chung L, Fiorentino D. A pilot trial of treprostinil for the treatment and prevention of digital ulcers in patients with systemic sclerosis. *J Am Acad Dermatol* 2006; 54: 880–882.
  72. Roustit M, Gaillard-Bigot F, Blaise S, Stanke-Labesque F, Cracowski C, Seinturier C, et al. Cutaneous iontophoresis of treprostinil in systemic sclerosis: a proof-of-concept study. *Clin Pharmacol Ther* 2014; 95: 439–445.
  73. Generali JA, Cada DJ. Off-label drug uses: nitroglycerin (transdermal): Raynaud phenomenon. *Hosp Pharm* 2012; 47: 924–926.
  74. Coleman SR. Structural fat grafting: more than a permanent filler. *Plast Reconstr Surg* 2006; 118: 108S–120S.
  75. Zuk PA, Zhu M, Ashjian P, De Ugarte DA, Huang JI, Mizuno H, et al. Human adipose tissue is a source of multipotent stem cells. *Mol Biol Cell* 2002; 13: 4279–4295.
  76. Nguyen A, Guo J, Banyard DA, Fadavi D, Toranto JD, Wirth GA, et al. Stromal vascular fraction: a regenerative reality? Part 1: Current concepts and review of the literature. *J Plast Reconstr Aesthet Surg* 2016; 69: 170–179.
  77. Griffin M, Ryan CM, Pathan O, Abraham D, Denton CP, Butler PEM. Characteristics of human adipose derived stem cells in scleroderma in comparison to sex and age matched normal controls: implications for regenerative medicine. *Stem Cell Res Ther* 2017; 8: 23.
  78. Daumas A, Eraud J, Hautier A, Sabatier F, Magalon G, Granel B. Potentialités et intérêt du tissu adipeux dans la sclérodémie. *Rev Med Interne* 2013; 34: 763–769.
  79. Magalon G, Daumas A, Sautereau N, Magalon J, Sabatier F, Granel B. Regenerative approach to scleroderma with fat grafting. *Clin Plast Surg* 2015; 42: 353–364.
  80. Magalon J, Daumas A, Veran J, Magalon G, Rossi P, Granel B, et al. Autologous adipose tissue-derived cells: are we talking about adipose derived stem cells, stromal vascular fraction, or Coleman fat grafting? *Cell Transplant* 2015; 24: 2667–2668.
  81. Del Papa N, Di Luca G, Sambataro D, Zaccara E, Maglione W, Gabrielli A, et al. Reply to J. Magalon et al. *Cell Transplant* 2015; 24: 2669–2670.
  82. Stone AV, Koman LA, Callahan MF, Eckman DM, Smith BP, Plate JF, et al. The effect of botulinum neurotoxin-A on blood flow in rats: a potential mechanism for treatment of Raynaud phenomenon. *J Hand Surg Am* 2012; 37: 795–802.
  83. Schweizer DF, Schweizer R, Zhang S, Kamat P, Contaldo C, Rieben R, et al. Botulinum toxin A and B raise blood flow and increase survival of critically ischemic skin flaps. *J Surg Res* 2013; 184: 1205–1213.