

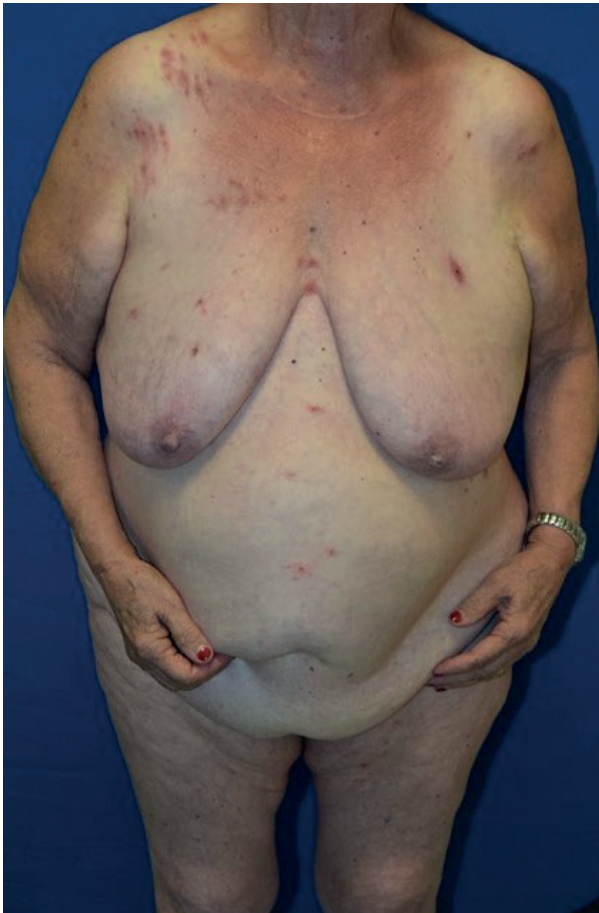**A Poultry Disease Mimicking Pediculosis Corporis Diagnosed By Dermoscopy: A Quiz**

Davide Francesco PUGLISI, Anna Elisa VERZÌ, Enrico PANEBIANCO, Giuseppe MICALI\* and Francesco LACARRUBBA  
 Dermatology Clinic, University of Catania, Via Santa Sofia, 78, IT-95123, Catania, Italy. E-mail: cldermct@gmail.com

An 80-year-old woman presented with a 3-week history of diffuse pruritus with nocturnal worsening. She denied any comorbidities or drug use. Dermatological examination revealed erythematous-purple macules and excoriated lesions localized on her trunk, upper limbs, and genitals

(Fig. 1). Similar symptoms and lesions were also present in close family members and the suspected diagnosis was scabies. Dermoscopy was negative for scabies, but during the examination a small red-black coloured mite (<1 mm) was observed moving on the patient’s back skin (Video 1<sup>1</sup>). Dermoscopy of the mite is shown in Fig. 2.

*What is your diagnosis? See next page for answer.*



**Fig. 1.** Clinical examination showing itchy purpuric excoriated macules and papules on the trunk.



**Fig. 2.** (A) Dermoscopic aspect (×30) of a mite from the patient’s back. (B) At high magnification (×150) the mite appears red-brown in colour with 4 pairs of limbs, and an ovoidal body engorged with blood.

<sup>1</sup><https://www.medicaljournals.se/acta/content/abstract/10.2340/00015555-3768>

## ANSWERS TO QUIZ

## A Poultry Disease Mimicking Pediculosis Corporis Diagnosed By Dermoscopy: A Commentary

Acta Derm Venereol 2021; 101: adv00417.

### Diagnosis: Infestation with *Dermanyssus gallinae*

The mite identified on the patient skin is *Dermanyssus gallinae*, a haematophagous ectoparasite that affects birds and, occasionally, a range of mammals, including humans (1, 2). Reservoirs are poultry farming, but also pigeons that live in urban environments, and bird's nests. In domestic environments, *Dermanyssus gallinae* may lose its parasitic specificity and may infest humans. In recent years, reports of human transmission in urban contexts have become more frequent (1, 3). Diffusion of mites may occur through windows and air conditioning systems (4–6). The current patient kept numerous hens in her garden. Given the high occurrence among farmers and veterinarians, this dermanyssosis may generally be considered an “occupational infestation”.

Adult mites measure approximately 400–700 µm in length and have a circular greyish-white coloured body and 4 pairs of limbs; their size may increase to more than 1 mm and the colour may typically become red-to-black after feeding (“red mite”). Their life cycle typically requires 2 weeks to complete and runs through egg to 1 larval stage, 2 nymphal and adult (3). Moving on clothes and then on the skin, mites bite, causing an inflammatory reaction characterized by erythematous/oedematous itchy papules. An irritating sensation of “walking on the skin” is often

reported by patients during the night-time (7, 8). The main differential diagnosis is represented by other parasitosis, such as scabies and pediculosis corporis. In the current patient, dermoscopy was negative for scabies and the main mite anatomical features differed from those of *Pediculus corporis* or body louse (Fig. 3), which presents a flattened body, measures approximately 2.5–3.5 mm and has 3 pairs of limbs, each forming a clamp at the end that allows attachment to the host's hair. Also, the head of *Pediculus corporis* appears smaller and elongated with 2 antennae.


As red mites are temporary visitors on humans, eradication of the infection reservoir is generally enough to interrupt the mite reproductive cycle. The current patient was advised to remove the source of infestation, and treated with topical permethrin 5% twice a week for one week.

Although this avian mite dermatitis is becoming progressively more common in the urban environment, we believe it is still underdiagnosed. Scant awareness among physicians may cause diagnostic delays with negative consequences for proper management and prevention. Dermoscopy is useful for the easy and rapid identification of cutaneous parasitoses (7–9).

*The authors have no conflicts of interest to declare.*

### REFERENCES

1. Cafiero MA, Barlaam A, Camarda A, Radeski M, Mul M, Sparagano O, et al. *Dermanyssus gallinae* attacks humans. Mind the gap! Avian Pathol 2019; 48: S22–S34.
2. Haag-Wackernagel D, Bircher A. Ectoparasites from feral pigeons affecting humans. Dermatology 2009; 220: 82–92.
3. Sparagano OA, George DR, Harrington DW, Giangaspero A. Significance and control of the poultry red mite, *Dermanyssus gallinae*. Annu Rev Entomol 2014; 59: 447–466.
4. Bellanger AP, Bories C, Foulet F, Bretagne S, Botterel F. Nosocomial dermatitis caused by *Dermanyssus gallinae*. Infect Control Hosp Epidemiol 2008; 29: 282–283.
5. Stolf HO, Reis RD, Espósito ACC, Haddad Júnior V. Acute prurigo simplex in humans caused by pigeon lice. An Bras Dermatol 2018; 93: 285–287.
6. Waap H, Nunes T, Mul MF, Gomes J, Bartley K. Survey on the prevalence of *Dermanyssus gallinae* in commercial laying farms in Portugal. Avian Pathol 2019; 48: S2–S9.
7. Cinotti E, Labeille B, Bernigaud C, Fang F, Chol C, Chermette R, Guillot J, Cambazard F, Perrot JL. Dermoscopy and confocal microscopy for in vivo detection and characterization of *Dermanyssus gallinae* mite. J Am Acad Dermatol 2015; 73: e15–e16.
8. Toukabri N, Souissi A, Abidi H, Mokni M. Dermoscopy aspects in *Dermanyssus gallinae* infestation. Int J Dermatol 2019; 58: e159–e160.
9. Verzi AE, Lacarrubba F, Dinotta F, Micali G. Dermoscopy of parasitic and infectious disorders. Dermatol Clin 2018; 36: 349–358.



**Fig. 3.** A graphic comparison of (A) *Dermanyssus gallinae* and (B) *Pediculus corporis*.