

Giant Condyloma Acuminatum Treated Successfully with Mild Local Hyperthermia: Two Case Reports

Zhen-Dong WEI^{1#}, Yu-Zhe SUN^{2#}, Rui-Qun QI¹, Ming-Zhu JIN¹ and Xing-Hua GAO^{1*}

¹Department of Dermatology, The First Hospital of China Medical University and Key Laboratory of Immunodermatology, Ministry of Health and Ministry of Education, Shenyang and ²Department of Dermatology, Dermatology Hospital, Southern Medical University, Guangdong, China. *E-mail: gaobarry@hotmail.com

#These authors contributed equally to this work and should be considered as first authors.

Accepted Feb 2 2021; Epub ahead of print Feb 8, 2021

Condyloma acuminatum (CA) is a common sexually transmitted disease (STD) resulting from human papillomavirus (HPV) infection. Under certain conditions, this disease may result in a huge cauliflower-like neoplasm, known as a giant condyloma acuminatum (GCA) or Buschke–Löwenstein tumour (BLT). Compared with that of typical CA, GCA is refractory to conventional treatments, including ablative, keratolytic, cytotoxic agents and surgical excision (1, 2).

Local hyperthermia (44°C for 30 min), a non-invasive treatment, has proved successful in treating common warts, with a cure rate of 53.8% and negligible rates of recurrence (3). However, reports on the efficacy of this treatment for GCA are relatively rare. We report here 2 cases of GCA that were treated successfully using a patented hyperthermia device (patent number ZL200720185403.3, China Medical University, Shenyang, China) (4). Signed informed consent was obtained from both patients.

CASE REPORTS

Case 1. A 52-year-old, otherwise healthy, woman was referred to our clinic, with a rough wart that had been present on her perineal region for the past 4 months. The neoplasm had proliferated and gradually formed a large protruding verrucous plaque. She was otherwise asymptomatic. On physical examination, a large exophytic cauliflower-like vulvar tumour, measuring 10 × 6 × 2.5 cm, extended over the perineal and perianal regions with a foul-smelling discharge on the surface (Fig. 1a). Histopathological examination revealed exophytic neoplasm with compact hyperkeratosis, extensive epidermal hyperplasia and vacuolated keratinocytes, consistent with CA (Fig. S1¹). HPV type 6 was identified from samples

of the lesion, assessed using flow hybridization (data not shown).

The patient refused any surgical/ablative laser procedures for fear of scars or pigmentation on the treated sites, but agreed to hyperthermia treatment. A 2-cm diameter circular area of hyperthermia was directed at the centre of the tumour (Fig. S2¹). Local hyperthermia treatment, at 44°C, was applied, using a standard protocol, which included 30 min of treatment per day for 3 consecutive days, followed by 2 additional consecutive days of treatment one week later, and then a maintenance regimen of one treatment per week (4). After one month of treatment, the tumour gradually decreased in size from the periphery to the centre, and the surface thinned, along with a reduction in the foul-smelling discharge. After 6 months of treatment, the tumour had completely cleared. There were no signs of recurrence at 1-year follow-up (Fig. 1b).

Case 2. A 16-year-old, otherwise healthy, female acquired a slight laceration on the vulvar surface when exercising approximately 6 months previously. Subsequently, a cauliflower-like mass developed at the wound site, which gradually increased in size, eventually extending over the entire vulva and perianal area. She had not received any treatment prior to being seen at our clinic. Physical examination revealed a large (15 × 5 × 4 cm), foul-smelling tumour on her vulva, involving bilateral labia majora, which extended anteriorly to the mons pubis and posteriorly to the perianal region (Fig. 2a). Biopsy results were consistent with CA (data not shown).

This patient refused surgery for fear of scarring and loss of sexual function. Local hyperthermia treatment was applied using the same protocol as that described above for case 1. The massive tumour gradually reduced in size over time, and resolved completely after 12 months, leaving several soft, smooth and small protrusions on the labia majora (Fig. 2b). These protrusions did not respond to subsequent hyperthermia treatments and remained stable over a 6-month follow-up (Fig. S3¹). The authors speculate that these small protrusions were expanded and loose vulvar tissue, possi-

¹<https://www.medicaljournals.se/acta/content/abstract/10.2340/00015555-3759>

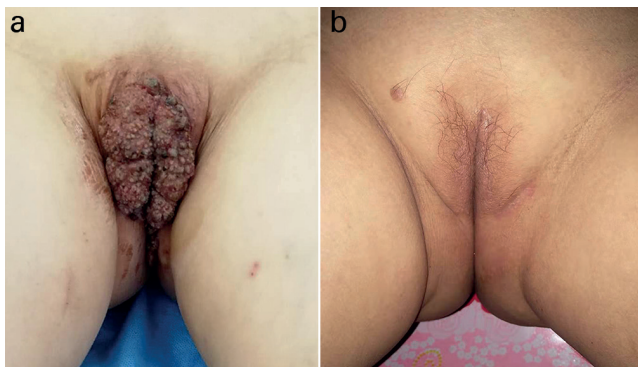


Fig. 1. Case 1. (a) Pretreatment appearance of giant condyloma acuminatum. (b) Follow-up one year after the final treatment.

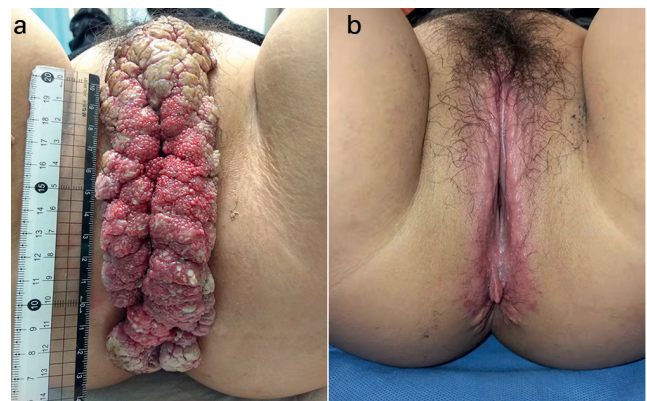


Fig. 2. Case 2. (a) Pretreatment appearance of giant condyloma acuminatum. (b) Recovery after 1 year of hyperthermia therapy.

bly due to overgrowth of underlying dermal tissues. The patient refused biopsy of the residual lesions.

DISCUSSION

GCA, first described in 1925, is a rare disease, which affects 0.1% of the population (5). Immunocompromised conditions, such as HIV infection, diabetes, malignancy and post-transplantation, seem to increase the risk of GCA (6). HPV, commonly the low-risk strains (6 and 11) and occasionally the high-risk strains (16 and 18), are the underlying cause of GCA (7). GCA is characterized by a high recurrence rate after treatment (30–70%) and a risk of malignant transformation to squamous cell carcinoma (8). Due to its rarity and a lack of data from controlled studies, optimal treatment for GCA has yet to be established, and treatment failures in response to both surgical and non-surgical modalities are common (2). In addition, the potential for secondary infections, induced by invasive treatment, poor wound healing and scar formation, represent problems that can further hinder positive responses (1, 2). Therefore, a more effective non-invasive therapy is needed.

Local hyperthermia, at 44°C, has been recommended for the treatment of recalcitrant warts (9). One of the underlying therapeutic mechanisms of local hyperthermia involves the stimulation of specific immune responses against HPV infection, including the promotion of Langerhans cells migrational maturation (10), and the induction of endogenous interferon production (11). Due to the involvement of these mechanisms, hyperthermia directed at a single lesion in patients with multiple warts has the potential to resolve all other untreated lesions (9). For GCA, as in the present cases, targeting the centre of the lesion simultaneously induced remission of surrounding lesions, suggesting activation of a specific immune response. In addition, local hyperthermia may stimulate apoptosis of HPV-infected cells (12), a therapeutic effect that may also increase the release of virus components, which could then promote antigen presentation and immune responses against HPV.

In general, local hyperthermia at 44°C for 30 min, when used in treatments on the hands and feet, is typically well tolerated by most patients (3). The 2 patients described here experienced a tolerable burning sensation in the treated area during the procedure. No other signifi-

cant side-effects, such as blistering or dyspigmentation, were observed.

ACKNOWLEDGEMENT

This work was supported by National Natural Science Foundation of China under Grant (number 81673070) and (number 81703137).

The authors have no conflicts of interest to declare.

REFERENCES

1. Lee CN, Hsu CK, Lee JY. Recalcitrant extragenital giant condyloma acuminatum: a need for combination therapy. *Dermatol Ther* 2019; 32: e12867.
2. Nambudiri VE, Mutyambizi K, Walls AC, Fisher DC, Bleday R, Saavedra AP. Successful treatment of perianal giant condyloma acuminatum in an immunocompromised host with systemic interleukin 2 and topical cidofovir. *JAMA Dermatol* 2013; 149: 1068–1070.
3. Gao XH, Gao D, Sun XP, Huo W, Hong YX, Li XD, et al. Non-ablative controlled local hyperthermia for common warts. *Chin Med J (Engl)* 2009; 122: 2061–2063.
4. Huo W, Di ZH, Xiao BH, Qi RQ, Weiland M, Gao XH. Clearance of genital warts in pregnant women by mild local hyperthermia: a pilot report. *Dermatol Ther* 2014; 27: 109–112.
5. Spinu D, Radulescu A, Bratu O, Checherita IA, Ranetti AE, Mischianu D. Giant condyloma acuminatum – Buschke-Lowenstein disease – a literature review. *Chirurgia-Bucharest* 2014; 109: 445–450.
6. Loo GH, Lim LY, Zainuddin ZM, Fam XI. Staged resection in the management of HIV-related anogenital giant condyloma acuminatum. A case report. *Ann Med Surg (Lond)* 2019; 48: 73–76.
7. Combaud V, Verhaeghe C, El Hachem H, Legendre G, Descamps P, Martin L, et al. Giant condyloma acuminatum of the vulva: successful management with imiquimod. *JAAD Case Rep* 2018; 4: 692–694.
8. Indinnimeo M, Impagnatiello A, D’Ettore G, Bernardi G, Moschella CM, Gozzo P, et al. Buschke-Lowenstein tumor with squamous cell carcinoma treated with chemo-radiation therapy and local surgical excision: report of three cases. *World J Surg Oncol* 2013; 11: 231.
9. Hu L, Qi R, Hong Y, Huo W, Chen HD, Gao XH. One stone, two birds: managing multiple common warts on hands and face by local hyperthermia. *Dermatol Ther* 2015; 28: 32–35.
10. Li X, Gao XH, Jin L, Wang Y, Hong Y, McHepange UO, et al. Local hyperthermia could induce migrational maturation of Langerhans cells in condyloma acuminatum. *J Dermatol Sci* 2009; 54: 121–123.
11. Zhu LL, Gao XH, Qi R, Hong Y, Li X, Wang X, et al. Local hyperthermia could induce antiviral activity by endogenous interferon-dependent pathway in condyloma acuminata. *Antiviral Res* 2010; 88: 187–192.
12. Wang X, Gao XH, Li X, Hong Y, Qi R, Chen HD, et al. Local hyperthermia induces apoptosis of keratinocytes in both normal skin and condyloma acuminata via different pathways. *Apoptosis* 2009; 14: 721–728.