

Combination Treatment with Human Adipose Tissue Stem Cell-derived Exosomes and Fractional CO₂ Laser for Acne Scars: A 12-week Prospective, Double-blind, Randomized, Split-face Study

Hyuck Hoon KWON¹, Steven Hoseong YANG², Joon LEE¹, Byung Cheol PARK³, Kui Young PARK⁴, Jae Yoon JUNG¹, Youin BAE⁵ and Gyeong-Hun PARK⁵

¹Oaro Dermatology Institute, Seoul, Republic of Korea, ²Guam Dermatology Institute, Guam, USA, ³Department of Dermatology, Dankook University, College of Medicine, Cheonan, ⁴Department of Dermatology, Chung-Ang University, College of Medicine, Seoul, and ⁵Department of Dermatology, Dongtan Sacred Heart Hospital, Hallym University College of Medicine, Hwaseong, Republic of Korea

A variety of applications of human adipose tissue stem cell-derived exosomes have been suggested as novel cell-free therapeutic strategies in the regenerative and aesthetic medical fields. This study evaluated the clinical efficacy and safety of adipose tissue stem cell-derived exosomes as an adjuvant therapy after application of fractional CO₂ laser for acne scars. A 12-week prospective, double-blind, randomized, split-face trial was performed. A total of 25 patients received three consecutive treatment sessions of fractional CO₂ laser to the whole face, with a follow-up evaluation. Post-laser treatment regimens were applied; for each patient, one side of the face was treated with adipose tissue stem cell-derived exosomes gel and the other side was treated with control gel. Adipose tissue stem cell-derived exosomes-treated sides had achieved a significantly greater improvement than the control sides at the final follow-up visit (percentage reduction in échelle d'évaluation clinique des cicatrices d'acné scores: 32.5 vs 19.9%, $p < 0.01$). Treatment-related erythema was milder, and post-treatment downtime was shorter on the human adipose tissue stem cell-derived exosomes-treated side. In conclusion, the combined use of this novel material with resurfacing devices would provide synergistic effects on both the efficacy and safety of atrophic acne scar treatments.

Key words: adipose tissue stem cell-derived exosomes; acne scar; fractional laser.

Accepted Oct 15, 2020; Epub ahead of print Oct 19, 2020

Acta Derm Venereol 2020; 100: adv00310.

Corr: Gyeong-Hun Park, Department of Dermatology, Dongtan Sacred Heart Hospital, Hallym University College of Medicine, 7, Keunjaebong-gil, Hwaseong-si, Gyeonggi-do 18450, Republic of Korea. E-mail: borel-algebra@gmail.com

Facial atrophic acne scarring is a psychologically damaging condition that can cause social disability. Fractional laser resurfacing has widened therapeutic options and has become the current standard of care (1–3). While ablative fractional carbon dioxide laser (FCL) resurfacing has demonstrated clinical efficacy in acne scar treatment, patients still need better improvement of scars and sustain side-effects during post-procedural wound healing (4). Therefore, an adjuvant application

SIGNIFICANCE

Adipose tissue stem cell-derived exosomes possess the critical properties of mesenchymal stem cells in the repair of organ injuries. Furthermore, adipose tissue stem cell-derived exosomes can avoid the risks of stem cell therapy because they are cell-free. A double-blind, randomized, first-in-human, clinical trial was conducted to evaluate the efficacy and safety of highly purified adipose tissue stem cell-derived exosomes as an adjuvant therapy after fractional CO₂ laser application for acne scars. Application of adipose tissue stem cell-derived exosomes treatment yielded more favourable responses, a shorter recovery time, and fewer side-effects. The combined use of adipose tissue stem cell-derived exosomes with resurfacing devices could provide synergistic effects on the efficacy and safety of atrophic acne scar treatments.

of adipose-derived stem cell (ASC)-conditioned medium (CM) has been tried, with synergistic effects in augmenting treatment responses and reducing adverse effects through its potential to accelerate tissue regeneration and wound healing (5).

Because mesenchymal stem cells (MSCs) can differentiate into various cell types as multipotent stem cells, their unique self-renewal capacities have made them a promising cell-based therapy to treat several human diseases (6). However, there have been several drawbacks in the use of MSCs, such as poor engraftment efficiency, potential tumour formation, and difficulty in quality control (7). Furthermore, paracrine signalling of MSCs is reported to be essential for their beneficial effects on tissue regeneration and anti-inflammation.

Exosomes are lipid bilayer-enclosed extracellular vesicles, 30–200 nm in diameter, produced by almost all cells and present in all body fluids (8–10). They are regarded as an essential mediator of intercellular communication by transferring proteins and genetic material between cells (9). Several studies have shown that MSC-derived exosomes carry the essential properties of MSCs (11–13), suggesting that exosomes may be a compelling alternative to MSCs in regenerative and aesthetic medicine, as they would avoid most of the problems associated with live MSC-based therapy (14). Inter-

tingly, recent studies have shown that human adipose tissue stem cell-derived exosomes (ASCE) possess the critical properties of stem cells and are as potent as MSCs in the repair of various organ injuries (15, 16). In fact, a variety of applications for ASCE have been suggested as novel cell-free therapeutic strategies in regenerative and aesthetic medicine. These data strongly suggest the suitability of ASCE as an adjuvant treatment modality in combination with FCL for the treatment of acne scars.

Since most single treatment modalities for acne scars yield less than ideal results with regard to efficacy and safety, customized combination treatments with various therapeutic methods are needed for optimal outcomes. Therefore, the aim of this study was to evaluate the clinical efficacy and safety of ASCE as an adjuvant therapy after application of FCL for acne scars.

MATERIALS AND METHODS

Study design and patient enrollment

A 12-week prospective, double-blind, randomized, split-face, comparative study was conducted to evaluate the clinical efficacy of application of ASCE after FCL in the treatment of facial acne scars. The study was carried out in accordance with the Declaration of Helsinki and approved by our institutional review board. Informed consent was obtained from all subjects prior to enrollment. In this study, patients received 3 consecutive treatments of FCL on their whole face at an interval of 3 weeks, with a follow-up evaluation 6 weeks after their final treatment session. An independent researcher created the random allocation sequence by a computer-based random number generator, using block randomization with a block size of 4 to assign the post-laser treatment modality of each half of the face between ASCE and control gel. The allocation was concealed from subjects and investigators, and was preserved by using sequentially numbered, sealed envelopes.

Twenty-five Korean subjects (18 men and 7 women, age range 19–54 years, 12 with Fitzpatrick skin type III and 13 with type IV) with atrophic acne scars were enrolled between October and November 2019. The sample size was determined based on feasibility, because previous data for power analysis were not available. Patients whose échelle d'évaluation clinique des cicatrices d'acné (ECCA) scores were 50 or higher were eligible for inclusion (17). Patients were excluded from the study if they had active acne under treatment or if they had received any other treatments for acne scars during the 12 months prior to the first treatment. Other treatments, including chemical, mechanical, or laser resurfacing, were not permitted during the study period.

Exosome purification and preparation of adipose tissue stem cell-derived exosomes gel for clinical application

Exosomes in this study were acquired from human ASC-CM by ExoSCRT™ technology (ExoCoBio Inc., Seoul, Republic of Korea) as described previously (18). Briefly, CM was collected from ASCs cultured with serum-free Dulbecco's Modified Eagle's Medium (Thermo Fisher Scientific, Waltham, MA, USA) in a 5% CO₂ atmosphere at 37°C. Collected CM was filtered through a 0.2-µm filter to remove non-exosomal particles. Exosomes were further concentrated and purified by tangential-flow filtration with a 500-kDa molecular weight cut-off filter membrane cartridge. Quantification of exosomes was performed by nanoparticle tracking analysis (NTA).

ASCE were prepared as gel solutions at 2 different doses for clinical application. To prepare the ASCE gel, ASCE were prepared at 9.78×10^{10} particles/ml (for the day of FCL treatment) or 1.63×10^{10} particles/ml (for days subsequent to FCL treatment) in a gel solution containing 30% ASCE. Detailed information on the ASCE and control gel solution is described in Appendix S1¹. To maintain blinding of investigators and subjects, the ASCE and control gel solutions were prepared with identical syringes, labelled left and right.

Treatment protocol

The entire face of each patient was treated with 10,600-nm FCL (Fraxis, Ilooda, Suwon, Korea). The face was cleansed with mild soap and topical anaesthesia was applied using EMLA® cream (Astrazeneca, Södertälje, Sweden) to the entire face under occlusion for 30 min prior to laser therapy. The treatment parameters were determined based on each patient's condition and availability as follows: 7.2–9.0 mJ, 240–300 µs duration, and 0.8–1.0 mm density in FCL (coverage=20–25%, each pixel size=100 µm, and approximate depth=1,100–1,400 µm, treatment density 120–160 microthermal zones/cm²). Each treatment session encompassed the entire face for two passes.

Post-laser treatment regimens were applied as follows: all patients were treated with 1 ml of either ASCE gel or control gel on each half of the face according to random assignment just after finishing the laser treatment. For the next two consecutive days after each treatment, patients were instructed to apply each solution to the designated half of the face twice a day as described.

Clinical outcome assessment

All patients were photographed using a standardized digital camera (EOS 600D, Canon, Tokyo, Japan) under identical lighting conditions at each visit. Efficacy of scar improvement was assessed by the ECCA score at each visit, as well as the Investigator's Global Assessment (IGA) at the final follow-up visit (17). IGA was evaluated using a 5-point scale associated with the degree of improvement (grade 0=no improvement, 1=1–25% improvement, 2=26–50% improvement, 3=51–75% improvement, and 4=76–100% improvement) (19, 20). For ECCA scoring, atrophic acne scars were classified into specific subtypes including icepick (V-shaped), boxcar (U-shaped), and rolling scar (M-shaped) according to their shape and size (17, 21), and the ECCA score was determined according to the number of each subtype of scar, as previously described (17). Two experienced dermatologists rated ECCA scores and IGA on the basis of the photographs in a fully blinded manner. The primary efficacy outcome was the percentage change in total ECCA score at the final follow-up visit. Secondary outcomes were the percentage change in total ECCA at weeks 3 and 6, the change in ECCA score for each subtype of atrophic scar at weeks 3, 6, and 12, and IGA at week 12.

Meanwhile, patients recorded the post-treatment responses, including erythema, oedema, and dryness with a 0–3 severity scale (0=none, 1=mild, 2=moderate, and 3=severe), daily for 7 days after each treatment session. Daily pain scores for the first post-treatment week were also recorded with a 0–10 severity scale (0 for no pain, 10 for the worst imaginable pain) during each post-treatment period. Other post-procedural complaints, including hyperpigmentation and secondary scarring, were documented at the final follow-up visit. The overall duration of subjective downtime, defined as the time during which the patient felt that treatment meaningfully affected their quality of life, was also recorded after each treatment session.

¹<https://doi.org/10.2340/00015555-3666>

Three-dimensional (3D) image analysis

To provide supportive data for the objective evaluation of treatment efficacy, a 3D camera and software (Antera 3D[®] CS, Miravex, Dublin, Ireland) were used for 4 patients. Antera 3D[®] captures high-resolution images and provides images in 3 dimensions using optical methods and complex mathematical algorithms, which makes it possible to extract and quantify data on the 3-dimensional shape of the skin. The depressed volume of atrophic scars, mean volume of skin pores, and skin surface roughness at the selected area were objectively measured at each visit.

Statistical analysis

Baseline characteristics were presented as the mean \pm standard deviation (SD) and range for continuous variables, and as number and percentage for categorical variables. Baseline data and IGA were analysed using the Wilcoxon signed-rank test to compare between treatment sides. Linear mixed effect models were used to analyse ECCA scores, atrophic scar volume, mean pore volume, and skin surface roughness. The duration of downtime was evaluated using a generalized linear mixed model with generalized Poisson family. Post-treatment pain, erythema, oedema, and dryness were assessed using cumulative link mixed models. The McNemar test was used to compare the occurrence of post-treatment hyperpigmentation and scar formation between treatment sides. A *p*-value less than 0.05 was considered statistically significant. All statistical analyses were performed using R version 3.6.2 (R Foundation for Statistical Computing, Vienna, Austria). Further details are provided in Appendix S1¹.

RESULTS

A total of 25 enrolled patients completed the study. Baseline patient characteristics are summarized in **Table I**. There were no significant differences in total ECCA score or scores of the 3 major subtypes (V-, U-, and M-shaped) of atrophic scars at baseline between the ASCE-treated and control sides.

Characterization of exosomes applied in clinical trial

ASCE were analysed with an NTA instrument to measure particle size distribution and concentration. As shown in **Fig. 1A**, the mode size was approximately 117.4 nm, and

Table I. Baseline characteristics of participants

Characteristics	ASCE side	Control side	<i>p</i> -value
Age, years, mean \pm SD (range)	35.6 \pm 8.2 (19–54)		
Sex, <i>n</i> (%)			
Male	18 (72)		
Female	7 (28)		
Fitzpatrick skin type, <i>n</i> (%)			
Type III	12 (48)		
Type IV	13 (52)		
ECCA score, mean \pm SD (range)			
Total	88.4 \pm 35.2 (50–180)	81.6 \pm 33.0 (50–180)	0.14
V-type	31.2 \pm 8.6 (15–45)	30.6 \pm 8.1 (15–45)	> 0.99
U-type	35.2 \pm 11.9 (20–60)	32.0 \pm 11.5 (20–60)	0.13
M-type	22.0 \pm 24.3 (0–75)	19.0 \pm 24.2 (0–75)	0.50
Atrophic scar volume, mm ³	3.7 \pm 1.9 (1.9–6.2)	4.4 \pm 3.2 (2.4–9.1)	0.63
Mean pore volume, 10 ⁻³ mm ³ , mean \pm SD (range)	4.0 \pm 0.8 (3.0–5.0)	3.8 \pm 1.0 (3.0–5.0)	> 0.99
Skin surface roughness	10.7 \pm 2.3 (7.8–13.2)	10.2 \pm 2.4 (6.7–11.7)	0.88

ASCE: adipose tissue stem cell-derived exosomes, ECCA: échelle d'évaluation clinique des cicatrices d'acné; SD: standard deviation.

the concentration was 3.26×10^{11} particles/ml. Cryo-transmission electron microscopy analysis revealed ASCE that were spheres of 30–200 nm diameter and exhibited a clear lipid bilayer structure (**Fig. 1B**). Next, ASCE were stained with antibodies against well-established exosome surface markers (CD9, CD63, and CD81) and were analysed using bead-based flow cytometry. As shown in **Fig. 1C**, ASCE were positively stained with all 3 markers. The purity of the ASCE was determined by the absence of calnexin and cytochrome C, negative markers of exosomes. In line with the literature, ASCE exhibited low levels of calnexin and cytochrome C (**Fig. 1D**). To evaluate biological functions of ASCE in target cells, 4 *in vitro* potency assays were performed. As shown in Appendix S1; S**Fig. 1**¹, ASCE increased collagen synthesis, cell migration and proliferation in human dermal fibroblast and decreased inflammatory cytokine level in murine macrophage. These results indicate that ASCE isolated by ExoSCRT[™] technology exhibit typical characteristics of exosomes. Purified ASCE were used in ASCE solutions, and *in vitro* data were described in Appendix S1¹.

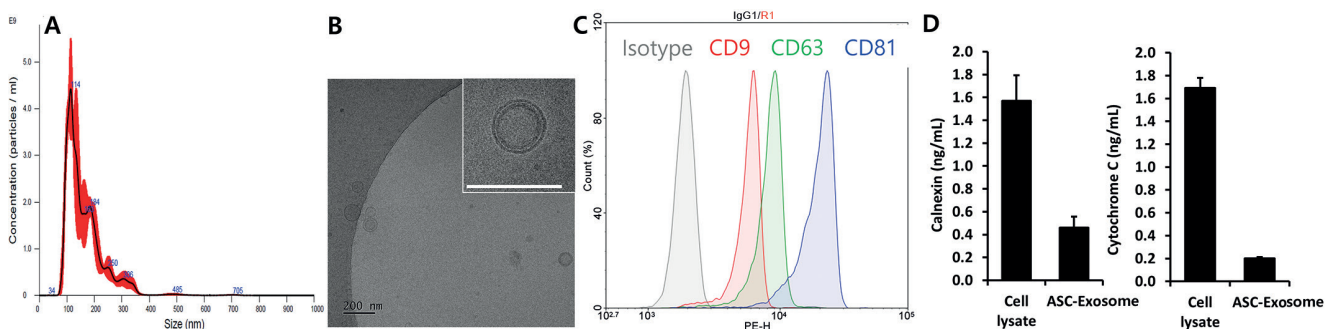


Fig. 1. Characterization of adipose tissue stem cell-derived exosomes (ASCE). (A) Representative plot of particle concentration and size distribution of ASCE, as measured by nanoparticle tracking analysis (NTA). (B) Cryo-transmission electron microscopy image of ASCE. Scale bar: 200 nm. (C) Signal intensities of exosome surface markers. ASCE were analysed using flow cytometry after staining with anti-CD9, -CD63, and -CD81 antibodies. (D) Levels of exosome exclusionary markers, calnexin and cytochrome C, in ASCE compared with cell lysate. Data are presented as the mean \pm standard deviation (SD) of 3 independent experiments.

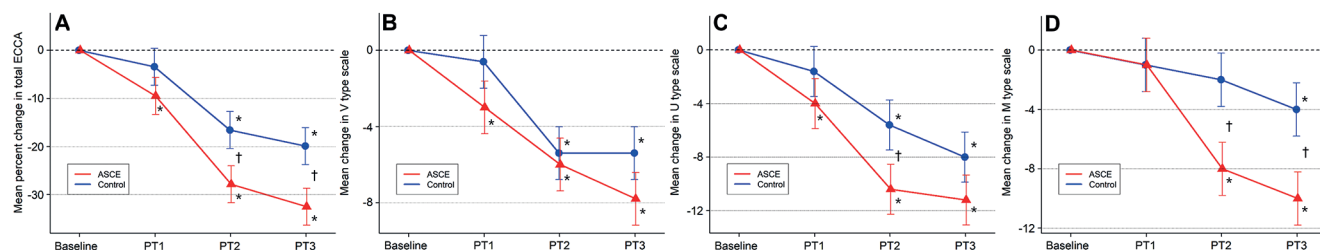


Fig. 2. Evaluation of scar improvement based on échelle d'évaluation clinique des cicatrices d'acné (ECCA) scores. (A) Mean percentage changes in total ECCA scores and mean changes in ECCA scores for (B) V-shaped (icepick), (C) U-shaped (boxcar), and (D) M-shaped (rolling) atrophic scars on the adipose tissue stem cell-derived exosomes (ASCE) and control sides. * $p < 0.05$ compared with baseline; † $p < 0.05$ between the 2 sides. Error bars indicate standard errors. PT: post-treatment.

Evaluation of scar improvement

A significant reduction in ECCA score from baseline was observed on the ASCE side beginning at the first post-treatment visit and on the control side from the second post-treatment visit (Fig. 2A). The difference in percent reduction of ECCA score between the two regimens was not significant at the first post-treatment visit, but became significant at the second post-treatment visit. At the final follow-up visit, the ECCA score was reduced by 32.5% (95% confidence interval [CI]: 24.8–40.2%) from baseline on the side treated with ASCE, which was significantly greater than the reduction of 19.9% (95% CI: 12.2–27.6%) on the control side ($p < 0.01$).

Mean reductions in ECCA score were also analysed for each subtype (V-, U-, and M-shaped) of atrophic scar (Fig. 2B–D). For both V- and U-shaped scars, significant decreases in ECCA score from baseline were observed on both sides, but the differences in the reduction of ECCA score between the two regimens were not statistically significant at the final follow-up visit. For M-shaped scars, the ECCA score was significantly decreased compared with baseline on both sides, and ASCE-treated sides

showed a significantly greater improvement than the control side at the final follow-up visit.

The IGA scores demonstrated comparable patterns to the ECCA evaluations. The grades 0, 1, 2, 3, and 4 were observed in 1, 8, 10, 5, and 1 facial sides treated with ASCE, respectively, and in 2, 11, 11, 1, and 0 facial sides with control, respectively. The ASCE-treated facial side demonstrated superior improvement based on IGA score compared with the control side after 3 sessions of each treatment ($p = 0.02$). Sixteen out of 25 facial sides achieved grade 2 or more improvements on the ASCE side, compared with 12 of the control-treated sides. Fig. 3 shows a representative case before and after each application.

Three-dimensional image analysis

The depressed volume of atrophic scars, mean volume of skin pores, and skin surface roughness were objectively measured using an Antera 3D[®] CS at baseline and post-treatment visits (Fig. 4). At the final follow-up visit, all of atrophic scar volume, mean pore volume, and skin surface roughness were significantly decreased from baseline on the ASCE side. In contrast, no significant decreases were observed on the control side.

Adverse effects

Various treatment-related side-effects, including post-treatment pain, erythema, oedema, and dryness, were experienced on both ASCE and control sides (Figs 5 and 6), but they were nearly resolved within 5 days. The severity of erythema during the first post-treatment week was significantly lower on the exosome side than on the control side ($p = 0.03$). Post-treatment pain, oedema, and dryness also tended to be milder on the exosome side, although not statistically significant. The mean duration of downtime was shorter on the ASCE side compared with the control side (4.1 (95% CI 3.5–4.8) days vs 4.3 (95% CI 3.7–5.1) days, $p = 0.03$). Two patients reported mild hyperpigmentation on the control side; one patient reported mild hyperpigmentation on the ASCE side ($p = 0.32$). No patient healed with scar formation or other permanent events.

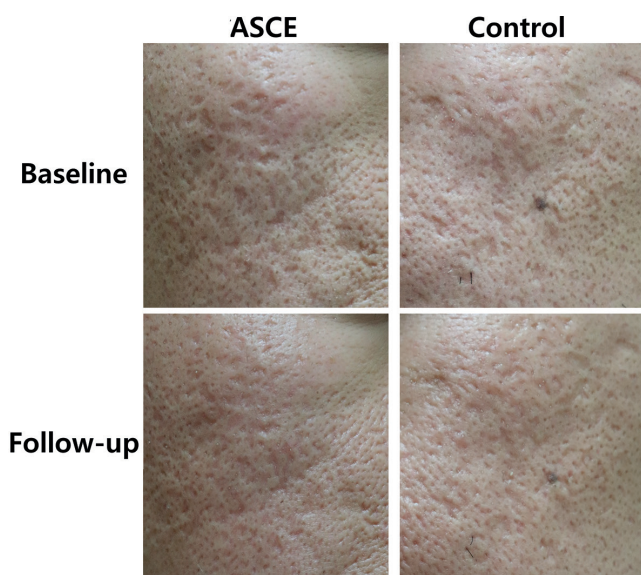


Fig. 3. Clinical photographs of the adipose tissue stem cell-derived exosomes (ASCE) and control sides at baseline and 6 weeks after 3 treatment sessions in a 30-year-old male.

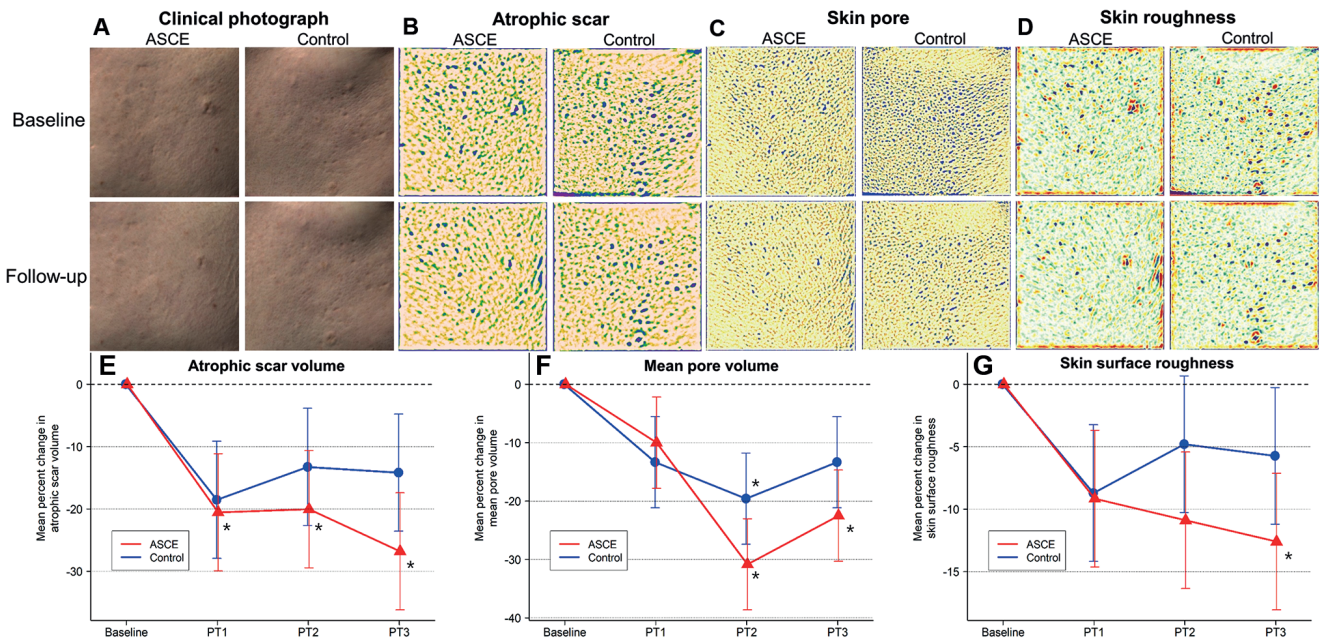


Fig. 4. Three-dimensional image analyses for atrophic scar, enlarged skin pore, and skin surface roughness using Antera 3D[®] CS. (A–D) Clinical photographs and analysed images of the adipose tissue stem cell-derived exosomes (ASCE) and control sides at baseline and at the final follow-up visit. (E) The depths of atrophic scars are shown as colours (white<yellow<green<blue<purple). (F) The depths of enlarged skin pores are shown as colours (white<yellow<orange<green<blue). (G) The vertical deviations of the skin surface are shown as colours: [downward] purple<blue<green<white<yellow<red [upward]. Mean percent changes in (E) atrophic scar volume, (F) mean pore volume, and (G) skin surface roughness on the ASCE and control sides. **p* < 0.05 compared with baseline. Error bars indicate standard errors. PT: post-treatment.

DISCUSSION

Atrophic acne scars are associated with an incomplete recovery of the dermal matrix damaged by chronic inflammation (22, 23). Therefore, most fractional resurfacing devices work by depositing a pixilated pattern of microscopic wounds surrounded by healthy tissue, which are then repaired by the natural recovery process (24). However, the regenerative capability of these controlled wounds may be limited in many cases, frequently leading to delayed healing with unsatisfactory results. This specific period is also associated with various treatment-related complications, necessitating a clinical adjuvant application of soothing biological materials (25–27).

This split-face study demonstrates the clinical benefits of the postoperative application of ASCE for acne scars. To the best of our knowledge, this is the first

study to use ASCE for human skin wound repair. The ASCE-treated side experienced significantly better improvement. Although both sides demonstrated steady improvement during treatment sessions, a significant difference between them was observed after completing the second session. Compared with other available adjuvant biological materials, the degree of additional improvement and relatively earlier onset time of ASCE were satisfactory (2, 4). The relative lack of efficacy of V- and U-subtypes suggests that the co-application of physical treatments including dot peeling or subcision is still needed with ASCE. From a safety perspective, ASCE-treated sides exhibited reduced post-procedural erythema and a shorter downtime.

When FCL is administered to the skin, the epidermis penetrated by the beams is instantly vaporized in micro-columns reaching down into the dermis; these columns

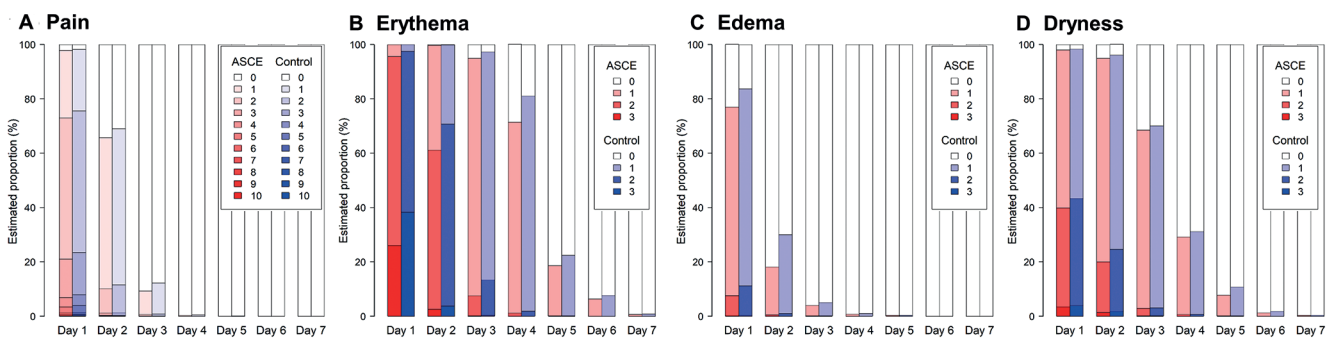


Fig. 5. Evaluation of: (A) pain, (B) erythema, (C) oedema, and (D) dryness on both adipose tissue stem cell-derived exosomes (ASCE) and control sides for post-treatment 7 days.

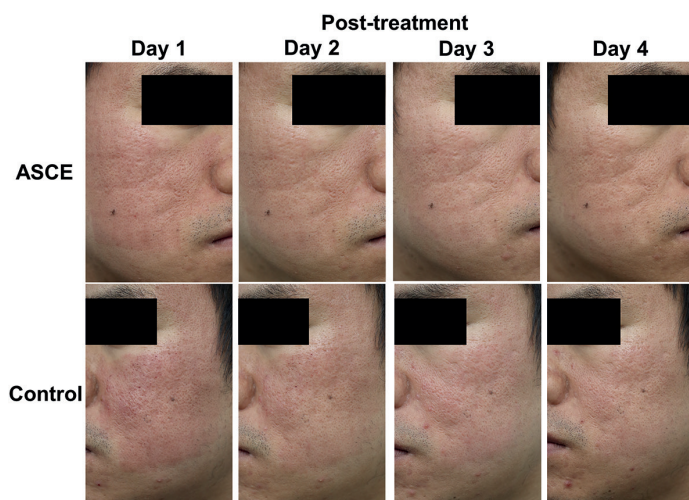


Fig. 6. Clinical photographs of the adipose tissue stem cell-derived exosomes (ASCE) and control sides for post-treatment 4 days in a 31-year-old male.

are called microablative columns (MACs) (28). MACs begin regeneration within several hours and complete re-epithelization is usually achieved within 2–3 days. During recovery, there is an accumulation of materials involved in wound remodelling, such as heat shock protein, procollagen, and dermal elastin (29). During this process, the temporarily formed vertical channel bypassing epidermal skin barriers allows an effective passage of microparticles, such as exosomes utilized in this study, into dermal tissues (30).

A mechanistic rationale for combining FCL and ASCE in acne scar treatment is the ability of ASCE to induce rapid healing after FCL ablation by supplying multiple anti-inflammatory and regenerative growth factors (31–35). Like ASCs, ASCE are also considered to optimize characteristics of fibroblasts, such as promoting the migration, proliferation, and collagen synthesis of fibroblasts (36–38), thereby accelerating wound healing of soft tissue with extracellular matrix remodelling (39, 40). ASCE also promote scarless cutaneous wound repair by regulating the ratios of collagen type III:type I, transforming growth factor (TGF)- β 3:TGF- β 1 and matrix metalloproteinase 3:tissue inhibitor of metalloproteinases-1, and by regulating fibroblast differentiation to mitigate scar formation (38). There is accumulating evidence that several signalling pathways related to skin regeneration and wound healing are stimulated by ASCE (34). A recent paper also demonstrates that ASCE can increase the *de novo* synthesis of ceramides to rebuild skin barrier (35). Compared with other biological materials, including platelet-rich plasma and stem cell-conditioned medium, ASCE have potential advantages as they are mass-produced, sterilized by filtration, and have a longer shelf-life.

As the exosomes used in this study were isolated from CM of ASCs from a healthy donor, there may be consideration of possible inter-individual variation. To make

consistent functionality of exosomes, standardized quality control (QC) for cells and exosomes was applied. Various tests such as phenotype (surface markers, differentiation potential, etc.) and growth kinetics, for stem cell itself were performed to ensure the quality of cells as the source of exosomes (41), as previously recommended (42–44). More importantly, QC for exosomes were also performed to compare the functional activities of ASCE according to the recommendation of the Korean Ministry of Food and Drug Safety (45) and the International Society for Extracellular Vesicles (46). Through the QC, *in vitro* potency assays have shown consistent results with low variations.

Furthermore, no specific immunity concerns have been raised regarding MSC-derived exosomes. Like their cellular source, MSC exosomes are hypo-immunogenic (47). They are negative for major histocompatibility complex (MHC) class I and II, and co-stimulatory molecules, such as B7-1 (CD80), B7-2 (CD86) and CD40 (48, 49). ASCE, used in the present study, were also negative for the human leukocyte antigens (HLA), the human MHCs, such as HLA-ABC and HLA-DRDPDQ (35, 41). In addition, the immunologic safety of MSC exosomes has been confirmed through various *in vitro* and *in vivo* studies (50–54).

There were some limitations to this study. First, all enrolled patients had a similar ethnic background. Secondly, further studies pursuing optimal ASCE application regimens are necessary.

In conclusion, treatment with ASCE afforded more favourable responses, a shorter recovery time, and fewer side-effects when utilized in combination with FCL for acne scarring. Therefore, co-treatment with this novel material with resurfacing devices may provide synergistic effects on both efficacy and safety for atrophic scar treatments.

ACKNOWLEDGEMENTS

Exosome and control solutions used in this study were manufactured, purified and provided by ExoCoBio Inc. (Seoul, Korea).

The authors have no conflicts of interest to declare.

REFERENCES

1. Wat H, Wu DC, Chan HH. Fractional resurfacing in the Asian patient: current state of the art. *Lasers Surg Med* 2017; 49: 45–59.
2. Jordan R, Cummins C, Burls A. Laser resurfacing of the skin for the improvement of facial acne scarring: a systematic review of the evidence. *Br J Dermatol* 2000; 142: 413–423.
3. Bradley JA, Bolton EM, Pedersen RA. Stem cell medicine encounters the immune system. *Nat Rev Immunol* 2002; 2: 859–871.
4. Kwon HH, Park HY, Choi SC, Bae Y, Kang C, Jung JY, et al. Combined fractional treatment of acne scars involving non-ablative 1,550-nm erbium-glass laser and micro-needling

- radiofrequency: a 16-week prospective, randomized split-face study. *Acta Derm Venereol* 2017; 97: 947–951.
5. Zhou BR, Zhang T, Bin Jameel AA, Xu Y, Xu Y, Guo SL, et al. The efficacy of conditioned media of adipose-derived stem cells combined with ablative carbon dioxide fractional resurfacing for atrophic acne scars and skin rejuvenation. *J Cosmet Laser Ther* 2016; 18: 138–148.
 6. Shin TH, Kim HS, Choi SW, Kang KS. Mesenchymal stem cell therapy for inflammatory skin diseases: clinical potential and mode of action. *Int J Mol Sci* 2017; 18.
 7. Lou G, Chen Z, Zheng M, Liu Y. Mesenchymal stem cell-derived exosomes as a new therapeutic strategy for liver diseases. *Exp Mol Med* 2017; 49: e346.
 8. Thery C, Zitvogel L, Amigorena S. Exosomes: composition, biogenesis and function. *Nat Rev Immunol* 2002; 2: 569–579.
 9. Colombo M, Raposo G, Thery C. Biogenesis, secretion, and intercellular interactions of exosomes and other extracellular vesicles. *Annu Rev Cell Dev Biol* 2014; 30: 255–289.
 10. Kalluri R, LeBleu VS. The biology, function, and biomedical applications of exosomes. *Science* 2020; 367: eaau6977.
 11. Golan K, Kumari A, Kollet O, Khatib-Massalha E, Subramaniam MD, Ferreira ZS, et al. Daily onset of light and darkness differentially controls hematopoietic stem cell differentiation and maintenance. *Cell Stem Cell* 2018; 23: 572–585e577.
 12. Pelizzo G, Avanzini MA, Icaro Cornaglia A, De Silvestri A, Mantelli M, Travaglio P, et al. Extracellular vesicles derived from mesenchymal cells: perspective treatment for cutaneous wound healing in pediatrics. *Regen Med* 2018; 13: 385–394.
 13. Ferreira ADF, Cunha PDS, Carregal VM, da Silva PC, de Miranda MC, Kunrath-Lima M, et al. Extracellular vesicles from adipose-derived mesenchymal stem/stromal cells accelerate migration and activate AKT pathway in human keratinocytes and fibroblasts independently of miR-205 activity. *Stem Cells Int* 2017; 2017: 9841035.
 14. Phinney DG, Pittenger MF. Concise review: MSC-derived exosomes for cell-free therapy. *Stem Cells* 2017; 35: 851–858.
 15. Lai RC, Yeo RW, Lim SK. Mesenchymal stem cell exosomes. *Semin Cell Dev Biol* 2015; 40: 82–88.
 16. Park JE, Tan HS, Datta A, Lai RC, Zhang H, Meng W, et al. Hypoxic tumor cell modulates its microenvironment to enhance angiogenic and metastatic potential by secretion of proteins and exosomes. *Mol Cell Proteomics* 2010; 9: 1085–1099.
 17. Dreno B, Khammari A, Orain N, Noray C, Merial-Kieny C, Mery S, et al. ECCA grading scale: an original validated acne scar grading scale for clinical practice in dermatology. *Dermatology* 2007; 214: 46–51.
 18. Cho BS, Kim JO, Ha DH, Yi YW. Exosomes derived from human adipose tissue-derived mesenchymal stem cells alleviate atopic dermatitis. *Stem Cell Res Ther* 2018; 9: 187.
 19. Kravvas G, Al-Niaimi F. A systematic review of treatments for acne scarring. Part 1: Non-energy-based techniques. *Scars Burn Heal* 2017; 3: 2059513117695312.
 20. Min S, Park SY, Moon J, Kwon HH, Yoon JY, Suh DH. Comparison between Er:YAG laser and bipolar radiofrequency combined with infrared diode laser for the treatment of acne scars: differential expression of fibrogenetic biomolecules may be associated with differences in efficacy between ablative and non-ablative laser treatment. *Lasers Surg Med* 2017; 49: 341–347.
 21. Boen M, Jacob C. A review and update of treatment options using the acne scar classification system. *Dermatol Surg* 2019; 45: 411–422.
 22. Moon J, Yoon JY, Yang JH, Kwon HH, Min S, Suh DH. Atrophic acne scar: a process from altered metabolism of elastic fibres and collagen fibres based on transforming growth factor-beta1 signalling. *Br J Dermatol* 2019; 181: 1226–1237.
 23. Holland DB, Jeremy AH, Roberts SG, Seukeran DC, Layton AM, Cunliffe WJ. Inflammation in acne scarring: a comparison of the responses in lesions from patients prone and not prone to scar. *Br J Dermatol* 2004; 150: 72–81.
 24. Alajlan AM, Alsuwaidan SN. Acne scars in ethnic skin treated with both non-ablative fractional 1,550 nm and ablative fractional CO2 lasers: comparative retrospective analysis with recommended guidelines. *Lasers Surg Med* 2011; 43: 787–791.
 25. Sundaram H, Cegielska A, Wojciechowska A, Delobel P. Prospective, randomized, investigator-blinded, split-face evaluation of a topical crosslinked hyaluronic acid serum for post-procedural improvement of skin quality and biomechanical attributes. *J Drugs Dermatol* 2018; 17: 442–450.
 26. Park GH, Rhee do Y, Moon HR, Won CH, Lee MW, Choi JH, et al. Effect of an epidermal growth factor-containing cream on postinflammatory hyperpigmentation after Q-switched 532-nm neodymium-doped yttrium aluminum garnet laser treatment. *Dermatol Surg* 2015; 41: 131–135.
 27. Uaboonkul T, Nakakes A, Ayuthaya PK. A randomized control study of the prevention of hyperpigmentation post Q-switched Nd:YAG laser treatment of Hori nevus using topical fucidic acid plus betamethasone valerate cream versus fucidic acid cream. *J Cosmet Laser Ther* 2012; 14: 145–149.
 28. Farkas JP, Richardson JA, Burrus CF, Hoopman JE, Brown SA, Kenkel JM. In vivo histopathologic comparison of the acute injury following treatment with five fractional ablative laser devices. *Aesthet Surg J* 2010; 30: 457–464.
 29. Kwon HH, Choi SC, Lee WY, Jung JY, Park GH. Clinical and histological evaluations of enlarged facial skin pores after low energy level treatments with fractional carbon dioxide laser in Korean patients. *Dermatol Surg* 2018; 44: 405–412.
 30. Choi JH, Shin EJ, Jeong KH, Shin MK. Comparative analysis of the effects of CO2 fractional laser and sonophoresis on human skin penetration with 5-aminolevulinic acid. *Lasers Med Sci* 2017; 32: 1895–1900.
 31. Ha DH, Kim HK, Lee J, Kwon HH, Park GH, Yang SH, et al. Mesenchymal stem/stromal cell-derived exosomes for immunomodulatory therapeutics and skin regeneration. *Cells* 2020; 9: 1157.
 32. Heo JS, Choi Y, Kim HO. Adipose-derived mesenchymal stem cells promote M2 macrophage phenotype through exosomes. *Stem Cells Int* 2019; 2019: 7921760.
 33. Li X, Xie X, Lian W, Shi R, Han S, Zhang H, et al. Exosomes from adipose-derived stem cells overexpressing Nrf2 accelerate cutaneous wound healing by promoting vascularization in a diabetic foot ulcer rat model. *Exp Mol Med* 2018; 50: 29.
 34. McBride JD, Rodriguez-Menocal L, Badiavas EV. Extracellular vesicles as biomarkers and therapeutics in dermatology: a focus on exosomes. *J Invest Dermatol* 2017; 137: 1622–1629.
 35. Shin KO, Ha DH, Kim JO, Crumrine DA, Meyer JM, Wakefield JS, et al. Exosomes from human adipose tissue-derived mesenchymal stem cells promote epidermal barrier repair by inducing de novo synthesis of ceramides in atopic dermatitis. *Cells* 2020; 9: 680.
 36. Hu L, Wang J, Zhou X, Xiong Z, Zhao J, Yu R, et al. Exosomes derived from human adipose mesenchymal stem cells accelerates cutaneous wound healing via optimizing the characteristics of fibroblasts. *Sci Rep* 2016; 6: 32993.
 37. Kim WS, Park BS, Sung JH, Yang JM, Park SB, Kwak SJ, et al. Wound healing effect of adipose-derived stem cells: a critical role of secretory factors on human dermal fibroblasts. *J Dermatol Sci* 2007; 48: 15–24.
 38. Wang L, Hu L, Zhou X, Xiong Z, Zhang C, Shehada HMA, et al. Exosomes secreted by human adipose mesenchymal stem cells promote scarless cutaneous repair by regulating extracellular matrix remodelling. *Sci Rep* 2017; 7: 13321.
 39. Buch AS, Schjerling P, Kjaer M, Jorgensen LN, Krarup PM, Agren MS. Impaired collagen synthesis in the rectum may be a molecular target in anastomotic leakage prophylaxis. *Wound Repair Regen* 2017; 25: 532–535.
 40. Kjaer M, Frederiksen AKS, Nissen NI, Willumsen N, van Hall G, Jorgensen LN, et al. Multinutrient supplementation increases collagen synthesis during early wound repair in a randomized controlled trial in patients with inguinal hernia. *J Nutr* 2020; 150: 792–799.
 41. Lee JH, Ha DH, Go HK, Youn J, Kim HK, Jin RC, et al. Reproducible large-scale isolation of exosomes from adipose tissue-derived mesenchymal stem/stromal cells and their application in acute kidney injury. *Int J Mol Sci* 2020; 21: 4774.
 42. Center for Biologics Evaluation and Research, Food and Drug Administration, U.S. Department of Health and Human Ser-

- vices. Guidance for industry: guidance for human somatic cell therapy and gene therapy. 1998. Available from: <https://www.fda.gov/media/72402/download>.
43. Center for Biologics Evaluation and Research, Food and Drug Administration, U.S. Department of Health and Human Services. Guidance for FDA reviewers and sponsors: content and review of chemistry, manufacturing, and control (CMC) information for human somatic cell therapy investigational new drug applications (INDs). 2008. Available from: <https://www.fda.gov/media/73624/download>.
 44. Trivedi A, Miyazawa B, Gibb S, Valanoski K, Vivona L, Lin M, et al. Bone marrow donor selection and characterization of MSCs is critical for pre-clinical and clinical cell dose production. *J Transl Med* 2019; 17: 128.
 45. Yi YW, Lee JH, Kim SY, Pack CG, Ha DH, Park SR, et al. Advances in analysis of biodistribution of exosomes by molecular imaging. *Int J Mol Sci* 2020; 21.
 46. Thery C, Witwer KW, Aikawa E, Alcaraz MJ, Anderson JD, Andriantsitohaina R, et al. Minimal information for studies of extracellular vesicles 2018 (MISEV2018): a position statement of the International Society for Extracellular Vesicles and update of the MISEV2014 guidelines. *J Extracell Vesicles* 2018; 7: 1535750.
 47. Zhang B, Yeo RWY, Lai RC, Sim EWK, Chin KC, Lim SK. Mesenchymal stromal cell exosome-enhanced regulatory T-cell production through an antigen-presenting cell-mediated pathway. *Cytotherapy* 2018; 20: 687–696.
 48. Pittenger MF, Mackay AM, Beck SC, Jaiswal RK, Douglas R, Mosca JD, et al. Multilineage potential of adult human mesenchymal stem cells. *Science* 1999; 284: 143–147.
 49. Yeo RWY, Lai RC, Tan KH, Lim SK. Exosome: a novel and safer therapeutic refinement of mesenchymal stem cell. *J Circulating Biomarkers* 2013; 1: 1–11.
 50. Kordelas L, Rebmann V, Ludwig AK, Radtke S, Ruesing J, Doeppner TR, et al. MSC-derived exosomes: a novel tool to treat therapy-refractory graft-versus-host disease. *Leukemia* 2014; 28: 970–973.
 51. Mendt M, Kamerkar S, Sugimoto H, McAndrews KM, Wu CC, Gagea M, et al. Generation and testing of clinical-grade exosomes for pancreatic cancer. *JCI Insight* 2018; 3: e99263.
 52. O'Loughlin AJ, Woffindale CA, Wood MJ. Exosomes and the emerging field of exosome-based gene therapy. *Curr Gene Ther* 2012; 12: 262–274.
 53. Qin J, Xu Q. Functions and application of exosomes. *Acta Pol Pharm* 2014; 71: 537–543.
 54. Sun L, Xu R, Sun X, Duan Y, Han Y, Zhao Y, et al. Safety evaluation of exosomes derived from human umbilical cord mesenchymal stromal cell. *Cytotherapy* 2016; 18: 413–422.