

Acquired Reactive Perforating Collagenosis Associated with Linear Immunoglobulin A Bullous Disease

Qi TAN¹, Li LIU^{1,2}, Jian ZHANG^{1,3} and Si-li NI^{1,4}

¹Department of Dermatology, Children's Hospital of Chongqing Medical University, No. 136, Zhongshan Er Rd, Yuzhong District, Chongqing, 400014, ²China International Science and Technology Cooperation Base of Child Development and Critical Disorders, ³Ministry of Education Key Laboratory of Child Development and Disorders and ⁴National Clinical Research Center for Child Health and Disorders, Chongqing, China. E-mail: tanqi@hospital.cqmu.edu.cn

Accepted Sep 15, 2020; Epub ahead of print Sep 18, 2020

Acquired reactive perforating collagenosis (ARPC) is an uncommon disease characterized by transepidermal elimination of altered collagen (1). ARPC has been described in the setting of many other conditions, including diabetes mellitus, chronic renal failure, malignancy, and drug induction, but association with a linear IgA dermatosis (LABD) is extremely rare. To our knowledge, we present here the first case of ARPC associated with LABD.

CASE REPORT

A 10-year-old girl presented with a 3-month history of mild pruritic vesicles and bullae, involving her scalp, trunk and extremities. She reported that the pruritic eruption had initially developed on the scalp and head and then became generalized. She was referred to a local hospital for further investigation. Biopsy specimens were obtained from lesions on the dorsal aspect of the left arm. Histopathological examination and direct immunofluorescence studies were consistent with the diagnosis of LABD. The patient received no treatment and exhibited spontaneous regression of bullae.

One month later, she experienced moderate pruritus accompanied by concurrent eruption of various sized, annular plaques with sharply demarcated borders. She presented to our clinic. The patient was healthy with no drug exposure. Basic laboratory findings and further biochemical testing, including tests for liver function, renal

function, thyroid hormones, and antinuclear antibodies, were unremarkable. On examination, there were solitary, well-demarcated and excoriated papules with umbilicated central regions scattered on the extremities and back (**Fig. 1**). Because the patient was diagnosed with LABD in the local hospital and there were no bullous lesions, the parents refused direct immunofluorescence examination.

Histopathological examination from the papule on the upper limb revealed a cup-shaped invagination and the formation of a channel for aggregates containing basophilic material along with degenerated collagen bundles and inflammatory cells. The degenerated collagen bundles were further confirmed by positive staining with Masson's trichrome (**Fig. 2a, b**). A diagnosis of ARPC was established. The patient was administered sulphapyridine, 60 mg/kg/day, and prescribed hydrocortisone, 2.5% cream, twice daily for the affected areas. The skin lesions and itching were markedly improved after 2 weeks of therapy. Therefore, the patient reduced the dosage slowly for 3 months and all the lesions resolved (**Fig. 2c, d**). A 6-month follow-up revealed no signs of recurrence.

DISCUSSION

Reactive perforating collagenosis is one of the 4 classical perforating dermatoses. ARPC can be divided into inherited variants with childhood onset and acquired variants with adult onset (2). While the pathogenesis of ARPC is

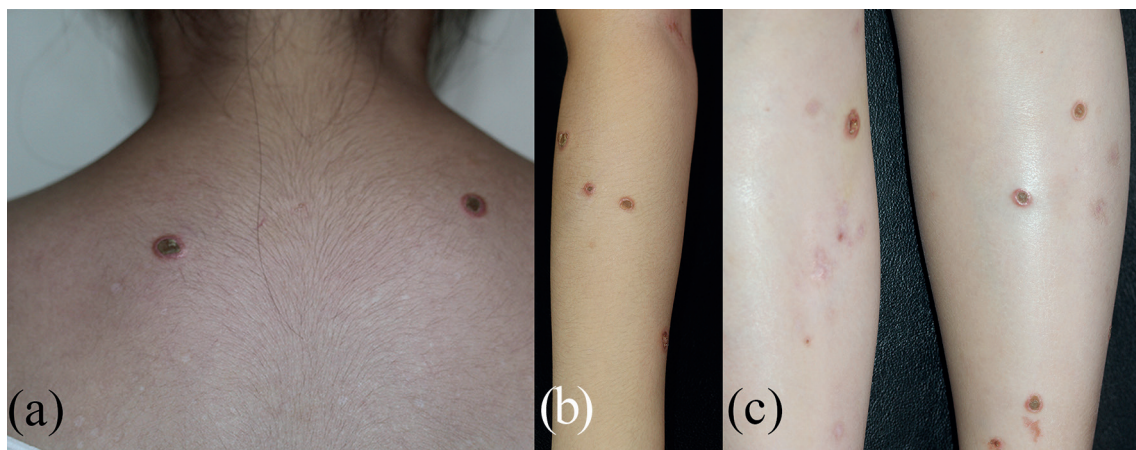


Fig. 1. Clinical photographs show several solitary papules, with well-demarcated borders and a central crater. (a) On the back (b) on the upper limb (c) on the lower limbs.

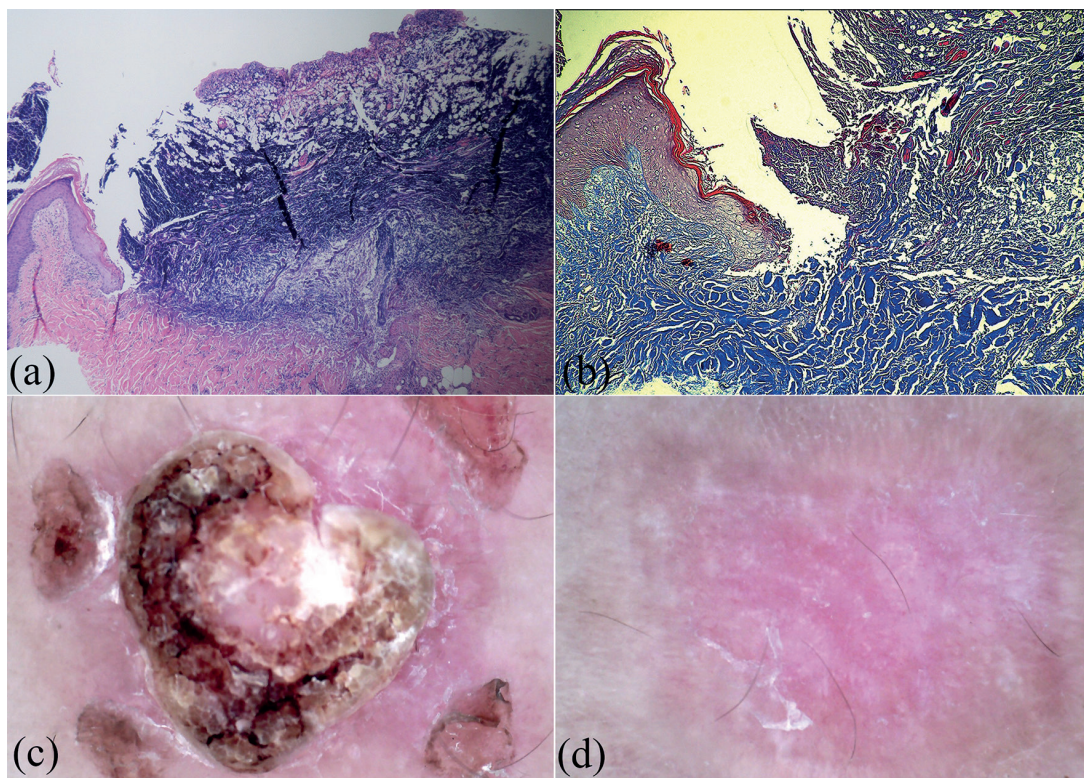


Fig. 2. (a) An excavated epidermis with a cup-shaped invagination composed of keratin, collagen and cell debris (haematoxylin-eosin stain, 40× magnification). (b) Collagen bands stained blue (Masson's trichrome, original magnification ×100). (c) Dermoscopic features of reactive perforating collagenosis: an active lesion on the upper arm. (d) A resolving lesion after treatment.

not completely understood, it is speculated that pruritus and scratching are the main triggers. ARPC usually affects patients with a variety of systemic disorders, and diabetes mellitus and chronic renal failure are the most common. In addition, malignancies, collagen vascular diseases (lupus, dermatomyositis), viral infection, lung fibrosis, thyroid dysfunction and drug induction have been reported (1, 3). The disease classically erupts as multiple, pruritic umbilicated papules with a central keratotic plug, with common sites including the trunk and extremities (1, 4). However, no case of LABD associated with ARPC has been published previously. LABD is a rare blistering autoimmune disease with the classic histological finding of a subepidermal blister with neutrophilic infiltrate and linear IgA deposition along the dermal–epidermal junction (5). Although LABD is not considered to be a potentially fatal disease, its management can be complex. Despite the absence of prospective controlled trials studying treatment options for LABD, various treatments have been reported to be effective. The best options for systemic therapy are sulphones (dapsone) and sulphonamides (sulphapyridine or sulphamethoxy-pyridazine) (5). In contrast to LABD, the treatment of ARPC, although it is self-limited in many cases, requires primarily controlling the underlying disease and minimizing pruritus. Considering that ARPC onset was subsequent to LABD in this case, we speculated that it was

a reaction to traumatic stimulation induced by LABD. The patient was treated successfully by administration of sulphapyridine combined with topical steroids. The improvement in our patient supports the hypothesis that ARPC is a secondary condition to LABD.

ACKNOWLEDGEMENT

We thank the patient and her parents, who cooperated in this study.

The authors have no conflicts of interest to declare.

REFERENCES

1. Fei C, Wang Y, Gong Y, Xu H, Yu Q, Shi Y. Acquired reactive perforating collagenosis: a report of a typical case. *Medicine (Baltimore)* 2016; 95: e4305.
2. Reid J, Almond L, Matthewman N, Stringer H, Francis N, Al Abadie M. A case of acquired reaction perforating collagenosis. *Australas J Dermatol* 2018; 59: e75–e76.
3. Kanra AY, Ari Yaylali S, Karadag AS, Ardagil Akcakaya A, Zemheri IE. Acquired perforating collagenosis associated with ranibizumab injection and successfully switched to aflibercept. *GMS Ophthalmol Cases* 2018; 8: Doc06.
4. García-Malinis AJ, Del Valle Sánchez E, Sánchez-Salas MP, Del Prado E, Coscojuela C, Gilaberte Y. Acquired perforating dermatosis: clinicopathological study of 31 cases, emphasizing pathogenesis and treatment. *J Eur Acad Dermatol Venereol* 2017; 31: 1757–1763.
5. Fortuna G, Marinkovich MP. Linear immunoglobulin A bullous dermatosis. *Clin Dermatol* 2012; 30: 38–50.