

## Seven Cases of Blistering Dactylitis

Stefano VERALDI<sup>1</sup>, Rossana SCHIANCHI<sup>2</sup>, Gianluca NAZZARO<sup>1</sup> and Stefano CAMBIAGHI<sup>1</sup><sup>1</sup>Department of Pathophysiology and Transplantation, Università degli Studi di Milano, Foundation IRCCS, Cà Granda Ospedale Maggiore Policlinico, Via Pace 9, IT-20122 Milan, and <sup>2</sup>European Institute of Dermatology, Milan, Italy. E-mail: stefano.veraldi@unimi.it

Accepted Apr 28, 2020; Epub ahead of print May 4, 2020

Blistering distal dactylitis (BDD), first described in 1972 by Hays & Mullard (1), is a rare bacterial infection of the distal phalanx of the finger (1–24). This paper reports 7 cases of BDD, observed in the period 1997–2019, at the Dermatology Unit of the University of Milan, Milan, Italy.

## CASE REPORTS

The case-list comprises 7 Caucasian patients (1 male and 6 females, age range 3–63 years, mean age 44 years) (Table I). All patients underwent laboratory tests and bacteriological examinations for aerobes and anaerobes. In 5 patients a finger was affected, and, in the other 2 patients, a toe. The infection was characterized by blisters (2 patients), oedema and blisters surrounded by mild erythema (4 patients) (Fig. 1), and pustules (1 patient). Four patients reported pain and one reported a burning sensation. Neither lymphangitis nor lymphadenopathy were detected. No systemic symptoms and signs were reported or observed.

Laboratory tests were within normal ranges or negative in all patients. Bacteriological examinations were positive for Group A *Streptococcus β-haemolyticus* and *S. aureus* (1 patient), and *S. aureus* (6 patients). Bacteriological examinations for anaerobes were negative.

All patients were treated by incision and drainage. According to antibiogram results, 6 patients were successfully treated with amoxicillin (2–3 g/day for 10 days) and one patient with i.m. ceftriaxone (2 g/day for 7 days). During follow-up (3–6 months) no relapses were observed.

## DISCUSSION

BDD can also involve the proximal phalangeal and palmar surfaces (10, 18), and the toes (2, 9, 16, 23). In these cases, the term “blistering dactylitis” is more appropriate. BDD is characterized by the acute appearance of bullous lesions, surrounded by an erythematous halo, which can become purulent and finally erosive. These lesions are sometimes painful (2). Lymphangitis, lymphadenopathy and fever are usually absent (2, 17).

It is possible that BDD is due to a bacterial autoinoculation from conjunctivae, nose, pharynx, tonsils and anus (2, 18). One case of BDD following animal bite was reported (2).

BDD was caused in the past by Group A (1–6, 8, 9, 18) or Group B (7, 10) *S. β-haemolyticus*. The first case of BDD caused by *S. aureus* was reported in 1992 (11): since then, these bacteria are most frequently isolated (12, 14, 18–22, 23). One case of methicillin-resistant *S. aureus* was described (21). As previously mentioned, in all the current patients the aetiological agent was *S. aureus*: the latter is the emerging bacterium in the aetiology of BDD. Some cases of mixed bacterial and viral infections (*S. β-haemolyticus* and *S. aureus* (2, 11), *S. β-haemolyticus* and *S. epidermidis* (3), and *S. aureus* and herpes simplex virus (15)) were also reported. In consideration of staphylococcal aetiology and clinical

Table I. Patients' characteristics

Sex	Age, years	Location of the lesions	Clinical features and symptoms
F	3	2 <sup>nd</sup> finger of the left hand	Blister and mild erythema (Fig. 1A)
F	48	1 <sup>st</sup> toe of the left foot	Blister followed by erosion; burning sensation
F	63	3 <sup>rd</sup> finger of the left hand	Severe oedema and blister surrounded by erythema (Fig. 1B); pain
F	63	3 <sup>rd</sup> finger of the left hand	Oedema and blister surrounded by erythema (Fig. 1C); pain
F	63	1 <sup>st</sup> toe of the left foot	Oedema and blister surrounded by erythema; pain
F	36	2 <sup>nd</sup> finger of the right hand	Oedema and blister surrounded by erythema (Fig. 1D); pain
M	32	2 <sup>nd</sup> finger of the right hand	Pustule

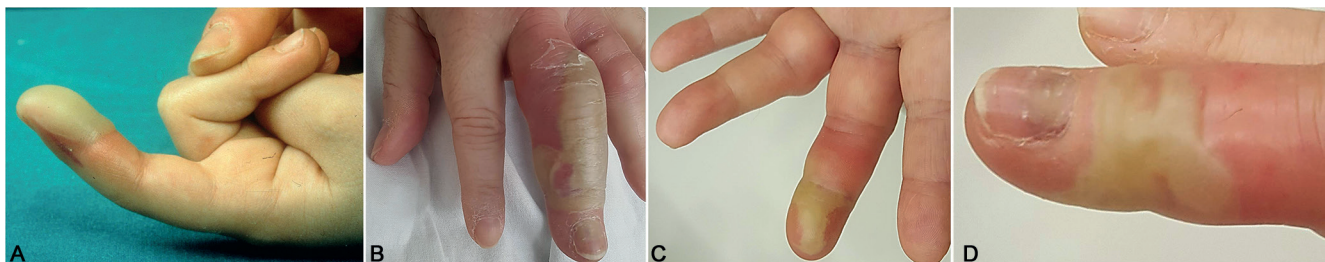


Fig. 1. (A). Patient 1. Blister and mild erythema of the 2<sup>nd</sup> finger of the left hand. (B). Patient 3. Severe oedema and blister surrounded by erythema of the 3<sup>rd</sup> finger of the left hand. (C). Patient 4. Oedema and blister surrounded by erythema of the 3<sup>rd</sup> finger of the left hand. (D). Patient 6. Oedema and blister surrounded by erythema of the 2<sup>nd</sup> finger of the right hand.

presentation, some authors consider BDD to be a clinical variety of bullous impetigo (18).

BDD occurs typically in children; however, some adult patients were described (6–8, 11, 13, 18–20, 22, 24). BDD is extremely rare in elderly people (24). Six out of 7 of our patients were adults, and 3 of these were 63 years of age. In some cases, adult patients with BDD were immunosuppressed due to diabetes (7), HIV infection (19) or treatment with systemic corticosteroids (11). Some cases of recurrent BDD were described (9, 24).

Differential diagnoses for BDD include irritant and allergic contact dermatitis, pompholyx, post-traumatic blisters, blisters caused by thermal injuries, herpes simplex, erythema multiforme, as reported by Frieden (10), insect bites and stings, and epidermolysis bullosa (17, 18).

The therapy is based on incision and drainage (3, 18, 24), and topical and/or systemic antibiotics. No treatment failure has been reported to date (18).

In conclusion, on the basis of the patients we described, BDD occurs also in adults, also involves the proximal phalangeal and palmar surfaces and the toes, and is more often caused by *S. aureus*.

*The authors have no conflicts of interest to declare.*

## REFERENCES

- Hays GC, Mullard JE. Can nasal bacterial flora be predicted from clinical findings? *Pediatrics* 1972; 49: 596–599.
- Hays GC, Mullard JE. Blistering distal dactylitis: a clinically recognizable streptococcal infection. *Pediatrics* 1975; 56: 129–131.
- McCray MK, Esterly NB. Blistering distal dactylitis. *JAAD* 1981; 5: 592–594.
- Schneider JA, Parlette HL III. Blistering distal dactylitis: a manifestation of group A beta-hemolytic streptococcal infection. *Arch Dermatol* 1982; 118: 879–880.
- Baran R. Blistering distal dactylitis. *JAAD* 1982; 6: 948–949.
- Palomo-Arellano A, Jiménez-Reyes J, Martín-Moreno L, de Castro-Torres A. Blistering distal dactylitis in an adult. *Arch Dermatol* 1985; 121: 1242.
- Benson PM, Solivan G. Group B streptococcal blistering distal dactylitis in an adult diabetic. *JAAD* 1987; 17: 310–311.
- Parras F, Ezpeleta C, Romero J, Sendagorta E, Buzón L. Blistering distal dactylitis in an adult. *Cutis* 1988; 41: 127–128.
- Telfer NR, Barth JH, Dawber RPR. Recurrent blistering distal dactylitis of the great toe associated with an ingrowing toenail. *Clin Exp Dermatol* 1989; 14: 380–381.
- Frieden IJ. Blistering dactylitis caused by group B streptococci. *Pediatr Dermatol* 1989; 6: 300–302.
- Zemtsov A, Veitschegger M. Staphylococcus aureus-induced blistering distal dactylitis in an adult immunosuppressed patient. *JAAD* 1992; 26: 784–785.
- Norcross MC Jr, Mitchell DF. Blistering distal dactylitis caused by Staphylococcus aureus. *Cutis* 1993; 51: 353–354.
- Zemtsov A, Paulger B, Veitschegger M. Anthropophilic transmission of blistering distal dactylitis. *Acta Derm Venereol* 1994; 74: 148–149.
- Woroszyński A, Durán C, Tamayo L, Orozco MDLL, Ruiz-Maldonado R. Staphylococcal blistering dactylitis: report of two patients. *Pediatr Dermatol* 1996; 13: 292–293.
- Ney AC, English JC III, Greer KE. Coexistent infections on a child's distal phalanx: blistering dactylitis and herpetic whitlow. *Cutis* 2002; 69: 46–48.
- Lyon M, Doehring MC. Blistering distal dactylitis: a case series in children under nine months of age. *J Emerg Med* 2004; 26: 421–423.
- Olivieri I, Scarano E, Padula A, Giasi V, Priolo F. Dactylitis, a term for different digit diseases. *Scand J Rheumatol* 2006; 35: 333–340.
- Scheinfeld NS. Is blistering distal dactylitis a variant of bullous impetigo? *Clin Exp Dermatol* 2007; 32: 314–316.
- Scheinfeld N. A review and report of blistering distal dactylitis due to Staphylococcus aureus in two HIV-positive men. *Dermatol Online J* 2007; 13: 8.
- Dauendorffer JN, Amouyal C, Mardare C, Ille O. Dactylite distale bulleuse staphylococcique après injections dans l'avant-bras. *Ann Dermatol Venereol* 2009; 136: 451–452.
- Fretzayas A, Moustaki M, Tsagris V, Brozou T, Nicolaidou P. MRSA blistering distal dactylitis and review of reported cases. *Pediatr Dermatol* 2011; 28: 433–435.
- Kollipara R, Downing C, Lee M, Guidry J, Robare-Stout S, Tyring S. Blistering distal dactylitis in an adult. *J Cutan Med Surg* 2015; 19: 397–399.
- Kowtoniuk R, Bednarek R, Maroon M. Blistering distal dactylitis. *JAMA Dermatol* 2018; 154: 1480.
- Hinkamp CA, Shah NH, Holland N, Wright A. Recurrent blistering distal dactylitis due to Staphylococcus aureus in an immunocompetent elderly woman. *BMJ Case Rep* 2018 May 7; 2018.