

Infectious Pseudochromhidrosis: A Case Report and Literature Review

Christoffer Aam INGVALDSEN^{1,2}, Truls Michael LEEGAARD^{2,3}, Gunnhild KRAVDAL⁴ and Cato MØRK⁵

¹Department of Plastic and Reconstructive Surgery, Rikshospitalet, Oslo University Hospital, ²Institute of Clinical Medicine, Faculty of Medicine, University of Oslo, Oslo, ³Department of Microbiology and Infection Control, Akershus University Hospital, ⁴Multidisciplinary Laboratory Medicine and Medical Biochemistry, Akershus University Hospital, and ⁵Akershus Dermatology Center, Lørenskog, Norway

Infectious pseudochromhidrosis is a rare dermatological disorder, characterized by a change in colour of the sweat from normal skin, caused by pigments from microorganisms. Such pigments are a result of evolutionary competition among microorganisms, which appears to be a decisive factor in their survival, pathogenicity, and virulence. Four bacteria are known to be involved in infectious pseudochromhidrosis: *Bacillus* spp. (blue colour), *Corynebacterium* spp. (brown/black colour), *Serratia marcescens* (red/pink colour), and *Pseudomonas aeruginosa* (blue-green colour). Infectious pseudochromhidrosis seems to be triggered by certain drugs and conditions causing physiological alterations and/or changes in microflora on the skin surface. The condition can be treated by addressing potential triggers and/or prescribing antibiotic/antiseptic therapies. We report here a case of blue infectious pseudochromhidrosis caused by pigment-producing *Bacillus cereus* and the results of a literature review.

Key words: chromhidrosis; pseudochromhidrosis; infectious pseudochromhidrosis; coloured sweat; pigment.

Accepted Oct 14, 2019; Epub ahead of print Oct 14, 2019

Acta Derm Venereol 2020; 100: adv00005.

Corr: Christoffer Ingvaldsen, Department of Plastic and Reconstructive Surgery, Rikshospitalet, Oslo University Hospital, Postboks 4950 Nydalen, NO-0424 Oslo, Norway. E-mail: c.a.ingvaldsen@medisin.uio.no

Chromhidrosis (from Greek: chroma [colour] and hidros [sweat]) is a rare dermatological disorder characterized by coloured sweat (1). Three different conditions can result in chromhidrosis (2):

Apocrine chromhidrosis is an intrinsic condition limited to areas with apocrine glands (e.g. face, axillae, anogenital area, and breast areolae) that excrete small amounts of oily sweat (1, 3). Oxidation of lipofuscin, as well as the increase in number of lipofuscin granules, are thought to cause the skin discolouration (4, 5). Lipofuscin is an intra-lysosomal polymeric material that gains colour as it oxidizes, with higher oxidation states resulting in a darker colour (1, 6–8). The oxidation may be triggered by chronic exposure to copper (e.g. from an intrauterine device or drinking water) and ammonium (9). There are reports of orange (9), red (10), blue (8, 9, 11–20), green (13, 21), and brown/black (22–26) sweat.

Eccrine chromhidrosis is generalized discolouration that occurs secondary to ingestion of water-soluble drugs (2,

SIGNIFICANCE

Microorganisms may produce pigments to increase the likelihood of survival. Under favourable conditions such pigments can result in coloured sweat and/or atypical skin discolouration in patients. This is a rare dermatological disorder named infectious pseudochromhidrosis. We report here a case of blue infectious pseudochromhidrosis caused by the bacteria *Bacillus cereus* and a literature review. The potential triggers, causative microorganisms, diagnostic approaches, and suggested treatments for infectious pseudochromhidrosis are addressed.

27, 28), dyes (29–31), or due to breakdown products from eccrine glands (2, 32–35). Eccrine glands are distributed with varying density over almost the entire integument and excrete large amounts of sweat, containing mostly water and electrolytes (1, 3).

Pseudochromhidrosis is a condition where colourless, eccrine sweat becomes coloured by exogenous factors on the skin surface, such as chromogenic microorganisms (1, 2, 15, 36–38) and chemical agents (39–42). The reported colours are yellow (5), red (43–45), pink (46, 47), blue (2, 37, 38), green (36, 48), brown (39, 40), and black (44, 49, 50), most commonly localized on the face, neck, and palms (2).

Since bacteria are potential causative agents of pseudochromhidrosis; *infectious pseudochromhidrosis* (IPCH) is becoming an increasingly used term in literature (1, 15). To our knowledge, no definition of this disorder has been proposed. Moreover, there is no clear consensus in terms of disease triggers, causative microorganisms, and factors contributing to the clinical presentation of coloured sweat. The scope of this article was, therefore, to report another case of IPCH and to review the literature.

MATERIALS AND METHODS

Case report

A 24-year-old woman presented with a 1-year history of an asymptomatic and odourless blue discolouration covering her hands, feet, and neck (**Fig. 1**). Her past medical history was insignificant and she had not been diagnosed with any underlying dermatoses. On the contrary, the patient reported daily attacks of cholinergic and dermographic urticaria, and hypohidrosis even after strenuous exercise and emotional stimuli. Her symptoms resemble acquired idiopathic anhidrosis; however, this was not investigated further.

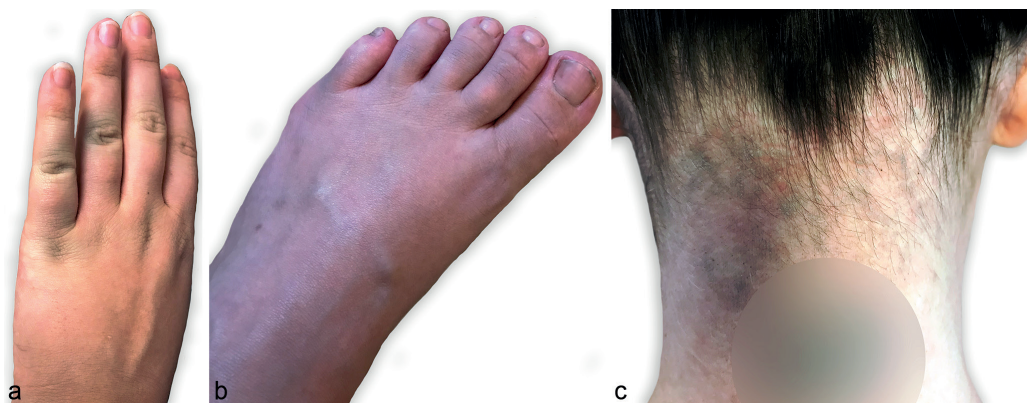

Fig. 1. Clinical photographs. (a) Blue discoloration on dorsal side of the hand primarily covering the joints. (b) Diffuse blue discoloration with an ashen hue on dorsal side of the foot. (c) Diffuse blue discoloration on the neck. Blurred circle covering tattoo.

At the time of presentation, the patient was approximately 7 months pregnant with her first child. She had started daily 25 mg promethazine due to pruritus 6 months earlier. Promethazine was stopped 1 month after presentation with no change in colour intensity. The blue colour was present continuously, but was more obvious after physical activity. It could be removed with soap and water; however, it was more easily removed with alcohol wipes (Fig. 2). The patient also reported staining of her clothes, towels, furniture, and shower. Urine, stool, saliva, and tears were normal coloured.

Initially, 2 blood samples were performed at her general physician's office with a 1-month interval. These blood samples were normal, apart from slightly increased copper values (35 and 37 $\mu\text{mol/l}$), yet values were within reference range in pregnancy (19–47 $\mu\text{mol/l}$).

Retrospectively, her husband also recognized slight blue discoloration located on his right pectoral and deltoid region. He had no significant past medical history, underlying dermatoses, and did not use any medication. The blue discoloration appeared 2–3 weeks after his wife's. No blood samples or other diagnostic tests were performed.

The first and senior author of this study saw the family of 3 approximately one year after presentation. An ashen hue was observed primarily on hands, feet, and neck (female patient), and right pectoral region (male patient). The underlying skin was normal. No skin discoloration was seen on their child. Dermoscopy of the discoloured areas revealed diffuse superficial pigmentation and an unmodified skin pattern (as postulated by Pistone et al. (51)). Skin examination with a Wood lamp revealed fluorescence on hands, feet, and hair (Fig. 3).

Multiple bacteriological and mycological swabs were taken from all 3 family members. Skin scrapings for dermatophyte PCR identification were taken from the female and male patient. All bacteriological swabs of female patient (neck, upper arm, axilla, hand, and foot) had heavy growth of 2 strains of *Bacillus cereus*.

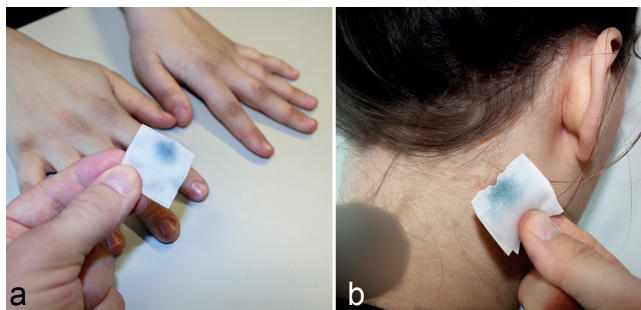


Fig. 2. Alcohol wipes from (a) hands and (b) neck easily removed the discoloration and revealed its blue colour.

Two out of 5 swabs from the male patient (pectoral region and foot) yielded the same bacteria. The child's swabs grew no microorganisms other than normal microflora. One of the *B. cereus* strains found produced blue pigments on blood agar, but the other did not (Fig. 4). All swabs and skin scrapings were negative for fungi. See below for methods for culture and identification of bacteria, and results. No skin biopsy was performed.

We hypothesized that the female patient was the source. In order to assess for a potential underlying cause of *B. cereus* growth, she was scheduled for a second appointment. Additional investigations were performed, including blood and urine analyses. All tests were normal, apart from a slightly increased alkaline phosphatase (ALP) of 122 U/l (reference range 35–105 U/l). ALP had also been above upper reference limit prior to the presentation of blue discoloration (with no known or suspected cause). Copper was normalized in this blood sample.

Due to her reports of hypohidrosis, a sweat provocation test with following sweat pH measurements (Jenway pH meter, Model 3510, Cole-Parmer, Staffordshire, UK) were performed. The patient performed 15 min of indoor cycling and 15 min of treadmill running. During this exercise she produced some sweat. However, this was less than was subjectively expected. Her scalp, hair, anterior and dorsal trunk, palms, and feet were surprisingly dry. pH measurements of sweat were considered normal (mean/min–max: 5.6/5.1–6.5). No wheals were induced during exercise.

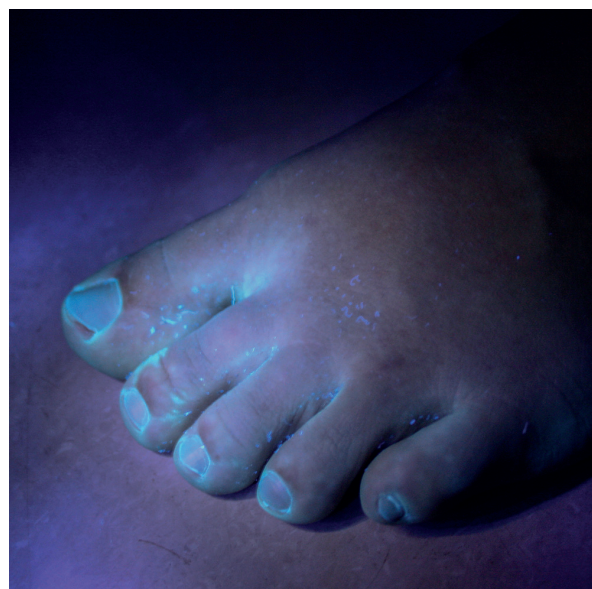

Fig. 3. Fluorescent material on dorsal aspects of the feet (especially interdigitally).

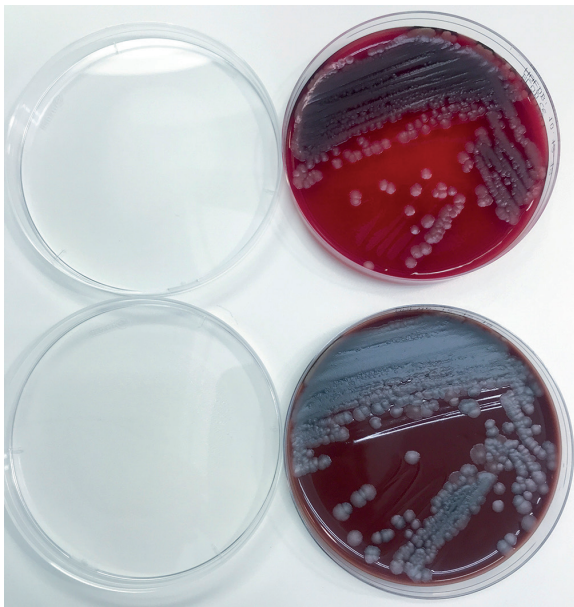


Fig. 4. *Bacillus cereus*: 2 isolates; one with a blue tint and one without.

Both adults were treated with oral erythromycin, 250 mg 3 times a day, and topical clindamycin 2 times a day for 10 days. As the female patient still had a slight discolouration on her feet, she continued same topical treatment for 7 days. Complete remission of blue discolouration was achieved in both patients, and it did not return during an observation time of 6 months.

Bacteria culture and identification

The samples were cultivated aerobically, anaerobically, and for fungi. The isolates were initially identified by morphology, Gram stain, haemolysis on blood agar, penicillin susceptibility, and motility. The isolates were then subject to matrix-assisted laser desorption ionisation time of flight mass spectrometry (MALDI-TOF MS, Bruker Daltonik GmbH, Bremen, Germany) and 16S rRNA gene sequencing with primers based on MicroSEC® 500 16S rDNA bacterial sequencing kit (Life Technologies, Paisley, UK).

Results

Two different isolates were cultured; a greyish culture and a greyish culture with a blue tint (Fig. 4). Both were penicillin resistant, motile, and produced haemolysis on blood agar. As neither MALDI-TOF nor 16S rRNA can distinguish properly between the *B. cereus*, *B. anthracis* and *B. thuringiensis*, it was concluded that the isolates belong to the *B. cereus* group and are non-anthraxis. The *B. cereus* strains are referred to as *B. cereus* in the following text. PCRs for dermatophytes were negative.

Literature search

This is a narrative review. A literature search of PubMed, Cochrane Library, and Google Scholar was performed in the period November 2018 to January 2019. Search terms included “chromhidrosis”, “pseudochromhidrosis”, “coloured sweat”, “lipofuscin”, “bacterial pigment”, “fungal pigment”, and “promethazine sweat”. Articles in English, German, French, Dutch, and Danish were included. Full texts and reference lists were reviewed.

RESULTS

Case reports of infectious pseudochromhidrosis and causative microorganisms

Based on the literature review, there are only 4 bacteria that are confirmed to have resulted in cases of IPCH (**Table I**):

Bacillus species – blue IPCH (2, 37, 38): *Bacillus* is a genus of Gram-positive, sporulating rods that are aerobic or facultatively anaerobic and are widely distributed in the environment (soil, dust, water, food, and plants) (52, 53). In terms of pathogenic *Bacillus* spp., *B. anthracis* is the only obligate pathogen (where cutaneous anthrax represents 95% of cases worldwide) (53). *B. cereus* is an occasional pathogen that can cause various infections mostly associated with its secreted toxins (52–55). The *B. cereus* found in the current case report colonizes hu-

Table I. Case reports of infectious pseudochromhidrosis and causative microorganisms

Causative microorganism(s)	Sweat colour	Age (years)/ Sex	Location	Treatment	Remission (yes/no)	Country of study	Ref.
<i>Bacillus</i> spp. (+ <i>Malassezia furfur</i>)	Blue	57/M	Head, neck	Stop ranitidine and lansoprazole (suggested causative agents)	Yes	New Zealand	37
<i>Bacillus</i> spp.	Blue	28/F	Arm, forearm, elbow, face, thorax	Stop topiramate. Topical erythromycin and basic soap	Yes	France	38
<i>Bacillus</i> spp.	Blue	14/F	Hand, feet	Topical sulfadiazine	Yes	Thailand	2
<i>Corynebacterium</i> spp.	Black	26/M	Palm	Topical erythromycin solution + oral erythromycin 250 mg bid for 1 week	Yes	Spain	50
<i>Corynebacterium</i> spp.	Brown/black	36/M	Face, neck, thorax	Topical erythromycin + oral erythromycin 250 mg tid for 10 days	Yes	Greece	49
<i>Corynebacterium</i> spp.	Black	20/M	Palms + leg (unilateral)	Topical clindamycin + oral erythromycin 500 mg bid for 3 days	Yes	India	44
<i>Corynebacterium</i> spp.	Black	-/F	Palms	Topical clindamycin (unknown duration)	Yes	India	44
<i>Serratia marcescens</i>	Pink	19/F	Finger/toe nails, palm, cheek	Topical 1% nadifloxacin bid + oral cefcapene pivoxil 300 mg/day	Yes	Japan	46
<i>Serratia marcescens</i>	Pink	55/M	Face, axilla	Ciprofloxacin 250 mg bid for 10 days + azithromycin 500 mg/day for 2 weeks + sulfamethoxazole trimethoprim (400/80 mg) bid for 2 weeks. Later topical clindamycin and 0.2% chlorhexidine	No	Denmark	47
<i>Pseudomonas aeruginosa</i> (+ <i>Bacillus</i> spp. + <i>Corynebacterium</i> spp.)	Blue-green	9/M	Neck, ears, wrists, antecubital fossae	An antimicrobial wash containing octenidine	Yes	Great Britain	36
<i>Pseudomonas aeruginosa</i>	Green	13/M	Toenails, foot sole (unilateral)	20% aluminium chloride solution	Yes	USA	48

bid: twice a day; tid: 3 times a day.

man skin and the intestinal tract (54), yet infections in immunocompetent patients are rare (56).

Corynebacterium species – brown/black IPCH (44, 49, 50): *Corynebacterium* is a genus of Gram-positive and (mostly) aerobic rods that is widely distributed in nature. *Corynebacterium* spp. are also found in the human microbiota and are, in general, innocuous (57, 58). The genus, however, which currently has more than 110 validated species, constitutes a very heterogeneous group (59). From a medical perspective, the pathogenic species *C. diphtheriae* (diphtheria), *C. ulcerans* (diphtheria-like infections), *C. tenuis* (trichomycosis axillaris), *C. minutissimum* (erythrasma), and *C. striatum* (endocarditis) might be of greatest interest.

Serratia marcescens – red/pink IPCH (45–47): *S. marcescens* is a Gram-negative, facultatively anaerobic, and saprophytic bacteria belonging to the *Enterobacteriaceae* family (60, 61). The ubiquitous bacteria have a predilection for starches and are rarely found in bacteriological skin cultures. Due to its production of red colour, the presence of *S. marcescens* has often been mistaken for sweating of blood (hematohidrosis) (45).

Pseudomonas aeruginosa – blue-green IPCH (36, 48, 62): *P. aeruginosa* is a Gram-negative, aerobic coccobacillus, which is widespread in nature (63). It is well known that the bacteria can colonize moist skin surfaces and can cause a greenish discolouration of skin, nails, clothes, and surgical dressings (48, 62, 64, 65).

There are also several case reports where IPCH has been suspected despite negative cultures (5, 43, 44, 51, 66). This tentative diagnosis has been strengthened by complete remission after antibacterial treatment, combining systemic and topical erythromycin in all cases.

The pigments of microorganisms

The literature review revealed a repeated theme of microorganisms producing pigments. Such pigments have, in some cases, been the suggested or documented reason for coloured sweat. In fact, research reveals hundreds of different pigment-producing microorganisms; bacteria, fungi, and parasites. The pigments described comprise a heterogeneous group of carotenoids (terpenoid pigments) (67–72), melanins (73–77), alkaloids (78, 79), porphyrins (80, 81), siderophores (65), and flavins (82).

Moreover, pigment production seems to be a decisive factor determining survival, pathogenicity, and virulence among microorganisms. Pigments do this by interfering with the host immune system and/or provoking inflammatory damage to cells and tissues (83). As such, some microorganisms invest heavily in pigment production, producing up to 30% of their dry weight as pigments (84). Many of these pigments are extracellular, and thereby able to colour the skin surface and/or stain clothes (85).

Concerning the 4 bacteria described above, the pigments have been chemically extracted and characterized in 2 of them: *Serratia marcescens* and *P. aeruginosa*.

The colour of *S. marcescens* IPCH is explained by its production of a red pigment, named prodigiosin, which gives the red/pink colour on the skin surface (46). Williamson et al. reported that the production of prodigiosin is highly dependent on temperature, pH, and other environmental factors (86).

P. aeruginosa may produce multiple water-soluble pigments, most commonly pyocyanin (blue) and pyoverdine (dim muddy yellow with a green fluorescence) causing the distinguishing blue-green hue (36, 64, 65, 87). “*Aeruginosa*” derives from the Latin word for copper rust, referring to the characteristic, pseudomonal discolouration (65).

Pigment production is known to occur in *Bacillus* spp. and *Corynebacterium* spp. However, studies do not mention the exact pigments causing blue and brown/black discolouration:

B. cereus has been shown to produce both a green (84, 88) and a red pigment (85). One study from Hiroshima reported large amounts of intracellular, purple pigment (copper coproporphyrin III) in a *B. cereus* strain (81, 89). To date, none of the previous studies have specifically reported a blue pigmentation as a result of colonization with *B. cereus*. Referred *Bacillus* spp. IPCH case reports (Table I) did, however, have blue-coloured sweat (which could potentially be pigments from *B. cereus*). Apart from *B. cereus*, previous studies have also described pigment production in many other *Bacillus* spp. (90–94).

Oliveira et al. reviewed pigment production in *Corynebacterium* spp., and reported that carotenoid production is one of many important virulence factors (59). Lycopene, the bright red pigment found in tomatoes, is one of the carotenoids produced (95). Only a few species, however, have been identified to produce carotenoid pigments (e.g. *C. glutamicum*, *C. michiganense*, *C. erythrogenes*, *C. fascians*, and *C. poinsettiae*) (59, 95). Leonard et al. also described a single strain of *C. striatum* that produced a soluble, brown pigment (96). Interestingly, this brown pigment production was enhanced when grown in the presence of tyrosine, which suggests that it is a melanin. Shulka et al. reported a novel *Corynebacterium* spp. that produced black pigment (with the proposed name *C. nigricans*) (97). This bacterium also hydrolysed tyrosine.

DISCUSSION

IPCH is a rare dermatological disorder characterized by a change in sweat colour on normal skin due to microorganisms' pigments. The infectiousness of this disorder has been exemplified in other studies (36, 44) as well as by the current case report. The pigments causing the colour palette seen in this disorder appear to be of major

Table II. Potential triggers of infectious pseudochromhidrosis (IPCH)

Potential trigger	Suggested way of triggering IPCH	Microorganism	Sweat colour	Comment	Ref.
Ranitidine (antihistamine; H ₂ -receptor antagonist)	Changed one of the environmental factors important in stratum corneum milieu	<i>Bacillus</i> spp.	Blue	Patient also used carbamazepine, propranolol, quetiapine, and lansoprazole	37
Promethazine (antihistamine; H ₁ -receptor antagonist)	Hypohidrosis (worsening of known condition)	<i>Bacillus</i> spp.	Blue	Patient with an unspecified hypohidrotic condition and 7 months pregnant at time of presentation	Our case report
Topiramate (anticonvulsant)	Hypohidrosis and decreased skin pH	<i>Bacillus</i> spp.	Blue	Patient also used levetiracetam	38
Lymecycline (tetracycline; antibiotic)	Promoting growth of chromogenic bacteria	<i>P. aeruginosa</i>	Blue-green	Lymecycline for acne	36

importance for microorganisms. They are a result of evolutionary competition to overcome hosts, other microorganisms, and environmental challenges. Despite determining survival, pathogenicity, and virulence among microorganisms, we hypothesize that most pigments are mainly produced only under favourable conditions (of pH, temperature, hydration levels, metabolism rate, oxygen tension, growth substrates, etc.). This hypothesis is strengthened by the observations found in some of the IPCH case reports.

Castela et al. reported blue skin discolouration due to *Bacillus* spp. triggered by topiramate (an antiepileptic drug) (38). They recorded a slightly decreased pH on the surface of the skin of their patient and proposed that this could be a result of the treatment provided. Topiramate inhibits carbonic anhydrase isoenzymes, which are also found in kidneys and eccrine glands. Inhibition of this enzyme may alter the primary sweat composition and reduce water formation. The authors also suggested that topiramate reduces aquaporin-5 expression in the skin. Together, these effects could lead to altered sweat pH and hypohidrosis (38). This theory is strengthened by studies indicating that hypohidrosis could be an adverse effect of topiramate (38, 98–100).

Combined use of ranitidine (H₂-receptor antagonist) and lansoprazole (proton pump inhibitor) may trigger *Bacillus* colonization, as reported by Hill et al. (37). The same authors also described resolution of both the blue skin discolouration and the *Bacillus* spp. overgrowth upon stopping ranitidine. Alongside Hill's et al., the current case report presents a patient who might be affected by blue *Bacillus* spp. IPCH following administration of an antihistamine.

Interestingly, our patient's unspecified hypohidrotic condition could, in fact, have been intensified by the use of promethazine: Zahejsky & Rovensky reported a significant reduction in palmar sweating after administration of promethazine in their clinical study (101). The same authors reported that palmoplantar sweat gland activity is regulated in other neuroanatomical centres (most likely limbic structures) than eccrine sweat gland activity elsewhere on the integument. Promethazine influences these sweat regulatory centres in a way that is not fully understood (101). As sweat production on the hands and feet are similarly controlled, a comparable worsening of hypohidrosis might have been the case at both sites (3).

As stated in the methods section, hands and feet were the first regions to show blue-coloured sweat. Whether promethazine is the sole trigger is currently unknown. Pregnancy is another possible trigger. **Table II** sums up potential triggers of IPCH based on the literature review.

Another important observation in the current case report was that *B. cereus* colonized and produced pigments in both adults, but not in the newborn. There are documented differences in the pH and hydration between paediatric and adult stratum corneum (102). The lack of discolouration in the newborn may reflect the absence of the specific requisite milieu for this pigment-producing *Bacillus* spp. to grow or to produce its pigment.

Based on the literature review, bacteriological tests should be the first diagnostic step when dealing with coloured sweat and/or atypical skin discolouration. Oral erythromycin and topical erythromycin/clindamycin appear to be the most effective treatment in both identified and unidentified IPCH (2). If cultures are negative, and antibiotic treatment does not lead to remission of symptoms, an in-depth medical history and broad diagnostic approach are of importance in determining an alternative cause for chromhidrosis.

ACKNOWLEDGEMENTS

The authors thank Dr Maria Ulvestad (Department of Dermatology, Stavanger University Hospital, Stavanger, Norway) for valuable comments.

The authors have no conflicts of interest to declare.

REFERENCES

- Semkova K, Gergovska M, Kazandjieva J, Tsankov N. Hyperhidrosis, bromhidrosis, and chromhidrosis: Fold (intertriginous) dermatoses. *Clin Dermatol* 2015; 33: 483–491.
- Tempark T, Wittayakornrerk S, Jirasukprasert L, Chatprodprai S, Wananukul S. Pseudochromhidrosis: report and review of literature. *Int J Dermatol* 2017; 56: 496–502.
- Asahina M, Poudel A, Hirano S. Sweating on the palm and sole: physiological and clinical relevance. *Clin Auton Res* 2015; 25: 153–159.
- Shelley WB, Hurley HJ, Jr. Localized chromhidrosis: a survey. *AMA Arch Derm Syphilol* 1954; 69: 449–471.
- Nair PA, Kota RK, Surti NK, Diwan NG, Gandhi SS. Yellow pseudochromhidrosis in a young female. *Indian Dermatol Online J* 2017; 8: 42–44.
- Cawley EP, Hsu YT, Sturgill BC, Harman LE, Jr. Lipofuscin ("wear and tear pigment") in human sweat glands. *J Invest Dermatol* 1973; 61: 105–107.

7. Kitamura S, Yanagi T, Imafuku K, Hata H, Shimizu H. Lipofuscin deposition causes the pigmentation of apocrine hidrocystoma. *J Dermatol* 2018; 45: 91–94.
8. Griffith JR. Isolated areolar apocrine chromhidrosis. *Pediatrics* 2005; 115: e239–241.
9. Erdol S, Karakaya S, Saglam H, Tarim O. Chromhidrosis due to exogenous oxidizing heavy metals: Clinical and laboratory findings. *Pediatr Dermatol* 2018; 35: 448–452.
10. Blalock TW, Crowson AN, Danford B. A case of generalized red sweating. *Dermatol Online J* 2014; 21. pii: 13030/qt73k8k695.
11. Mapara A TV, Khandelwal AK. Apocrine chromhidrosis over dorsum of foot: a case report. *J Dental Med Sci* 2012; 2: 33–34.
12. Polat M, Dikilitas M, Gozubuyukogullari A, Alli N. Apocrine chromhidrosis. *Clin Exp Dermatol* 2009; 34: e373–374.
13. Balasubramanian S, Amperayani S, Dhanalakshmi K, Kumar R. Chromhidrosis – colored sweat in a toddler. *Indian Pediatr* 2015; 52: 337–338.
14. Carman KB, Aydogdu SD, Sabuncu I, Yasar C, Yakut A, Oztelcan B. Infant with chromhidrosis. *Pediatr Int* 2011; 53: 283–284.
15. Bilgin I, Kelekci KH, Catal S, Calli A. Late-onset apocrine chromhidrosis. *Indian J Dermatol Venereol Leprol* 2014; 80: 579.
16. Marks JG, Jr. Treatment of apocrine chromhidrosis with topical capsaicin. *J Am Acad Dermatol* 1989; 21: 418–420.
17. Pérez Tato B, Zamora Martínez E, Sánchez Albusa B, Pérez González YC, Polimón Olabarrieta I, Marinero Escobedo S, et al. Facial and axillary apocrine chromhidrosis. *Dermatol Online J* 2012; 18: 13.
18. Barankin B, Alanen K, Ting PT, Sapijaszko MJ. Bilateral facial apocrine chromhidrosis. *J Drugs Dermatol* 2004; 3: 184–186.
19. Chang YC, Anderson N, Soeprono F. Bilateral facial pigmentation. *Dermatol Online J* 2007; 13: 16.
20. Geelhoed-Duijvestijn PHLM. [A woman with blue sweat]. *Ned Tijdschr Geneesk* 2005; 149: 583 (in Dutch).
21. Cox NH, Popple AW, Large DM. Autofluorescence of clothing as an adjunct in the diagnosis of apocrine chromhidrosis. *Arch Dermatol* 1992; 128: 275–276.
22. Saff DM, Owens R, Kahn TA. Apocrine chromhidrosis involving the areolae in a 15-year-old amateur figure skater. *Pediatr Dermatol* 1995; 12: 48–50.
23. Beer K, Oakley H. Axillary chromhidrosis: report of a case, review of the literature and treatment considerations. *J Cosmet Dermatol* 2010; 9: 318–320.
24. Wang A, Wysong A, Nord KM, Egbert BM, Kosek J. Chromhidrosis: a rare diagnosis requiring clinicopathologic correlation. *Am J Dermatopathol* 2014; 36: 853–855.
25. Matarasso SL. Treatment of facial chromhidrosis with botulinum toxin type A. *J Am Acad Dermatol* 2005; 52: 89–91.
26. Wu JM, Mamelak AJ, Nussbaum R, McElgunn PS. Botulinum toxin a in the treatment of chromhidrosis. *Dermatol Surg* 2005; 31: 963–965.
27. Hurley HJ, Witkowski J. Dye clearance and eccrine sweat secretion in human skin. *J Invest Dermatol* 1961; 36: 259–272.
28. Snider DE, Jr., Farer LS. Rifampin and red urine. *JAMA* 1977; 238: 1628.
29. Krishnam AS, Bharathi S, Krishnan S. An interesting case of bisacodyl (dulcolax)-induced chromhidrosis. *Indian J Dermatol Venereol Leprol* 2012; 78: 756–758.
30. Cilliers J, de Beer C. The case of the red lingerie – chromhidrosis revisited. *Dermatology* 1999; 199: 149–152.
31. Jaiswal AK, Ravikiran SP, Roy PK. Red eccrine chromhidrosis with review of literature. *Indian J Dermatol* 2017; 62: 675.
32. Park JG, Prose NS, Garza R. Eccrine Chromhidrosis in an adolescent with sickle cell disease. *Pediatr Dermatol* 2017; 34: e273–e274.
33. Keum DI, Hong H, Lee SH, Ahn SK. Eccrine chromhidrosis resembling clinical features of pompholyx with bile-like greenish pigmentation on the right palm and soles. *Ann Dermatol* 2015; 27: 482–483.
34. Uzoma M, Singh G, Kohen L. Green palmo-plantar vesicular eruption in a patient with hyperbilirubinemia. *JAAD Case Rep* 2017; 3: 273–275.
35. Triwongwanat D, Kasemsarn P, Boonchai W. Green pigmentation on the palms and soles. Acral green pigmentation (eccrine chromhidrosis). *JAMA Dermatol* 2013; 149: 1339–1340.
36. Gaffney DC, Cooper HL. Coloured sweat in two brothers: first report of familial chromhidrosis. *Australas J Dermatol* 2016; 57: e23–25.
37. Hill S, Duffill M, Lamont D, Rademaker M, Yung A. Pseudo-chromhidrosis: blue discolouration of the head and neck. *Australas J Dermatol*. 2007; 48: 239–241.
38. Castela E, Thomas P, Bronsard V, Lacour JP, Ortonne JP, Passeron T. Blue pseudo-chromhidrosis secondary to topiramate treatment. *Acta Derm Venereol* 2009; 89: 538–539.
39. Takita Y, Ichimiya M, Yamaguchi M, Hamamoto Y, Muto M. A case of pseudo-chromhidrosis due to dihydroxyacetone. *J Dermatol* 2006; 33: 230–231.
40. Yoshida R, Kobayashi S, Amagai M, Tanaka M. Brown palm pseudo-chromhidrosis. *Contact Dermatitis* 2002; 46: 237–238.
41. Poh-Fitzpatrick MB. “Red sweat”. *J Am Acad Dermatol* 1981; 4: 481–482.
42. Labouche F. Pseudo-chromhidrose infectieuse: une étude de cas et une revue de la littérature. *Bull Soc Fr Dermatol Syphiligr* 1965; 72: 444–447.
43. Thami GP, Kanwar AJ. Red facial pseudo-chromhidrosis. *Br J Dermatol* 2000; 142: 1219–1220.
44. Koley S, Mandal RK. Red and black pseudo-chromhidrosis. *Indian J Dermatol* 2016; 61: 454–457.
45. Greenberg L. *Serratia marcescens* in human affairs. *Drug Intell Clin Pharm* 1978; 12: 674–679.
46. Harada K, Morohoshi T, Ikeda T, Shimada S. A patient with pseudo-chromhidrosis presenting with pink nails. *J Am Acad Dermatol* 2012; 67: e74–75.
47. Weismann K, Poulsen AG, Moller AF, Kobayashi T. A man with a reddish stained wash cloth. *Arch Dermatol* 2005; 141: 795–796.
48. LeFever WP, Golitz LE. Green foot. *Pediatr Dermatol* 1984; 2: 38–40.
49. Panagoulas GS, Basagiannis CS, Tentolouris N, Stavropoulou E, Karnesis L. Colored sweat caused by pseudo-chromhidrosis. *Ann Intern Med* 2010; 152: 198–199.
50. Rodriguez-Martin M, Rodriguez MS, Cabrera AN. Palmar and digital black pseudo-chromhidrosis: a case report. *Int J Dermatol* 2010; 49: 562–564.
51. Pistone G, Bellomo L, Alaimo R, Bongiorno MR. Pseudo-chromhidrosis: the role of dermoscopy in diagnosis. *Int J Dermatol* 2014; 53: e473–475.
52. Bottone EJ. *Bacillus cereus*, a volatile human pathogen. *Clin Microbiol Rev* 2010; 23: 382–398.
53. Turnbull PCB. *Bacillus*. 4th edn. Galveston, TX: University of Texas Medical Branch at Galveston, Dept of Microbiology & Immunology, 1996.
54. Veysseyre F, Fourcade C, Lavigne JP, Sotto A. *Bacillus cereus* infection: 57 case patients and a literature review. *Med Mal Infect* 2015; 45: 436–440.
55. Glasset B, Herbin S, Granier SA, Cavalié L, Lafeuille E, Guérin C, et al. *Bacillus cereus*, a serious cause of nosocomial infections: epidemiologic and genetic survey. *PloS One* 2018; 13: e0194346.
56. Chang T, Rosch JW, Gu Z, Hakim H, Hewitt C, Gaur A, et al. Whole genome characterization of *Bacillus cereus* associated with specific disease manifestations. *Infect Immun* 2018; 86: e00086–18.
57. Burkovski A. *Corynebacteria: genomics and molecular biology*. Erlangen: Caister Academic Press, 2008.
58. Bernard K. The genus *corynebacterium* and other medically relevant coryneform-like bacteria. *Clin Microbiol* 2012; 50: 3152–3158.
59. Oliveira A, Oliveira LC, Aburjaile F, Benevides L, Tiwari S, Jamal SB, et al. Insight of genus *corynebacterium*: ascertaining the role of pathogenic and non-pathogenic species. *Front Microbiol* 2017; 8: 1937.
60. Haddix PL, Shanks RMQ. Prodigiosin pigment of *Serratia*

- marcescens is associated with increased biomass production. Arch Microbiol 2018; 200: 989–999.
61. Khanna A, Khanna M, Aggarwal A. Serratia marcescens – a rare opportunistic nosocomial pathogen and measures to limit its spread in hospitalized patients. J Clin Diagn Res 2013; 7: 243–246.
 62. Kalkan G, Duygu F, Bas Y. Greenish-blue staining of under-clothing due to Pseudomonas aeruginosa infection of intertriginous dermatitis. J Pak Med Assoc 2013; 63: 1192–1194.
 63. Chiriac A, Brzezinski P, Foia L, Marinu I. Chloronychia: green nail syndrome caused by Pseudomonas aeruginosa in elderly persons. Clin Interv Aging 2015; 10: 265–267.
 64. Yilmaz E, Savk E, Oncü S, Gülec GU, Ertugrul B, Sakarya S, et al. Green staining of clothing: a signal for pseudomonal infection. Cutis 2010; 86: 305–308.
 65. Kaya TI, Delialioglu N, Yazici AC, Tursten U, Ikizoglu G. Medical pearl: blue underpants sign – a diagnostic clue for Pseudomonas aeruginosa intertrigo of the groin. J Am Acad Dermatol 2005; 53: 869–871.
 66. Singal A, Thami GP. Red pseudochromhidrosis of the neck. Clin Exp Dermatol 2004; 29: 548–549.
 67. Afra S, Makhdoumi A, Matin MM, Feizy J. A novel red pigment from marine Arthrobacter sp. G20 with specific anticancer activity. J Appl Microbiol 2017; 123: 1228–1236.
 68. Avalos J, Carmen Limon M. Biological roles of fungal carotenoids. Curr Genet 2015; 61: 309–324.
 69. Sandmann G. Carotenoids of biotechnological importance. Adv Biochem Eng Biotechnol 2015; 148: 449–467.
 70. Merritt K, Jacobs NJ. Characterization and incidence of pigment production by human clinical group B streptococci. J Clin Microbiol 1978; 8: 105–107.
 71. Marshall JH, Wilmoth GJ. Pigments of Staphylococcus aureus, a series of triterpenoid carotenoids. J Bacteriol 1981; 147: 900–913.
 72. Lan L, Cheng A, Dunman PM, Missiakas D, He C. Golden pigment production and virulence gene expression are affected by metabolisms in Staphylococcus aureus. J Bacteriol 2010; 192: 3068–3077.
 73. Nosanchuk JD, Stark RE, Casadevall A. Fungal melanin: what do we know about structure? Front Microbiol 2015; 6: 1463.
 74. Ensminger PW. Pigment production by Haemophilus paratuberculosis. J Bacteriol 1953; 65: 509–510.
 75. Schmalzer-Ripcke J, Sugareva V, Gebhardt P, Winkler R, Kniemeyer O, Heinekamp T, et al. Production of pyomelanin, a second type of melanin, via the tyrosine degradation pathway in Aspergillus fumigatus. Appl Environ Microbiol 2009; 75: 493–503.
 76. Valeru SP, Rompikuntal PK, Ishikawa T, Vaitkevicius K, Sjöling A, Dolganov N, et al. Role of melanin pigment in expression of Vibrio cholerae virulence factors. Infect Immun 2009; 77: 935–942.
 77. Chatfield CH, Cianciotto NP. The secreted pyomelanin pigment of Legionella pneumophila confers ferric reductase activity. Infect Immun 2007; 75: 4062–4070.
 78. Machowinski A, Kramer HJ, Hort W, Maysen P. Pityriacitrin – a potent UV filter produced by Malassezia furfur and its effect on human skin microflora. Mycoses 2006; 49: 388–392.
 79. Maysen P, Schafer U, Kramer HJ, Irlinger B, Steglich W. Pityriacitrin – an ultraviolet-absorbing indole alkaloid from the yeast Malassezia furfur. Arch Dermatol Res 2002; 294: 131–134.
 80. Miller SD, David-Bajar K. Images in clinical medicine. A brilliant case of erythrasma. N Engl J Med 2004; 351: 1666.
 81. Yamada-Ankei T, Iwasaki H, Mori T. Production of copper coproporphyrin III by Bacillus cereus. I. Purification and identification of copper coproporphyrin III. J Biochem 1977; 81: 835–842.
 82. Odanaka K, Iwatsuki M, Satho T, Watanabe M. Identification and characterization of a brilliant yellow pigment produced by Bordetella pertussis. Microbiol Immunol 2017; 61: 490–496.
 83. Liu GY, Nizet V. Color me bad: microbial pigments as virulence factors. Trends Microbiol 2009; 17: 406–413.
 84. Banerjee D, Chatterjee S, Banerjee UC, Guha AK, Ray L. Green pigment from Bacillus cereus M(1)(16) (MTCC 5521): production parameters and antibacterial activity. Appl Biochem Biotechnol 2011; 164: 767–779.
 85. Canale-Parola E. A Red pigment produced by aerobic spore-forming bacteria. Arch Microbiol 1963; 46: 414–427.
 86. Williamson NR, Simonsen HT, Ahmed RA, Goldet G, Slater H, Woodley L, et al. Biosynthesis of the red antibiotic, prodigiosin, in Serratia: identification of a novel 2-methyl-3-n-amylyl-pyrrole (MAP) assembly pathway, definition of the terminal condensing enzyme, and implications for under-cycloprodigiosin biosynthesis in Streptomyces. Mol Microbiol 2005; 56: 971–989.
 87. Moayedi A, Nowroozi J, Sepahy AA. Effect of fetal and adult bovine serum on pyocyanin production in Pseudomonas aeruginosa isolated from clinical and soil samples. Iranian J Basic Med Sci 2017; 20: 1331–1338.
 88. Banerjee D, Mondal A, Gupta M, Guha AK, Ray L. Optimization of fermentation conditions for green pigment production from Bacillus cereus M116 (MTCC 5521) and its pharmacological application. Lett Appl Microbiol 2014; 58: 25–30.
 89. Yamada-Ankei T, Iwasaki H, Mori T. Production of copper coproporphyrin III by Bacillus cereus. II. Regulation of the biosynthesis of coproporphyrin III and its copper complex by oxygen and heavy metal ions. J Biochem 1977; 81: 843–850.
 90. Magyarosy A, Ho JZ, Rapoport H, Dawson S, Hancock J, Keasling JD. Chloroxanthomycin, a fluorescent, chlorinated, pentacyclic pyrene from a Bacillus sp. Appl Environ Microbiol 2002; 68: 4095–4101.
 91. Taylor MJ, Lawton WD, Goldberg ID. Correlation between pigment production and amino acid requirements in Bacillus subtilis. J Bacteriol 1970; 102: 871–873.
 92. Rogolsky M. Genetic mapping of a locus which regulates the production of pigment associated with spores of Bacillus subtilis. J Bacteriol 1968; 95: 2426–2427.
 93. Drewnowska JM, Zambrzycka M, Kalska-Szostko B, Fiedoruk K, Swiecicka I. Melanin-like pigment synthesis by soil bacillus weihenstephanensis isolates from northeastern Poland. PloS One 2015; 10: e0125428.
 94. Barnett TA, Valenzuela D, Riner S, Hageman JH. Production by Bacillus subtilis of brown sporulation-associated pigments. Can J Microbiol 1983; 29: 96–101.
 95. Heider SA, Peters-Wendisch P, Wendisch VF. Carotenoid biosynthesis and overproduction in Corynebacterium glutamicum. BMC Microbiol 2012; 12: 198.
 96. Leonard RB, Nowowiejski DJ, Warren JJ, Finn DJ, Coyle MB. Molecular evidence of person-to-person transmission of a pigmented strain of Corynebacterium striatum in intensive care units. J Clin Microbiol 1994; 32: 164–169.
 97. Shukla SK, Bernard KA, Harney M, Frank DN, Reed KD. Corynebacterium nigricans sp. nov.: proposed name for a black-pigmented Corynebacterium species recovered from the human female urogenital tract. J Clin Microbiol 2003; 41: 4353–4358.
 98. Arcas J, Ferrer T, Roche MC, Martínez-Bermejo A, López-Martín V. Hypohidrosis related to the administration of topiramate to children. Epilepsia 2001; 42: 1363–1365.
 99. de Carolis P, Magnifico F, Pierangeli G, Rinaldi R, Galeotti M, Cevoli S, et al. Transient hypohidrosis induced by topiramate. Epilepsia 2003; 44: 974–976.
 100. Margari L, Ventura P, Buttiglione M, Presicci A, Lucarelli E, Sardaro M, et al. Electrophysiological study in 2 children with transient hypohidrosis induced by topiramate. Clinical Neuropharmacol 2008; 31: 339–346.
 101. Zahejsky J, Rovensky J. Effect of prothazin (promethazine hydrochloride) on sweat gland activity. Dermatol Monatschr 1972; 158: 1–8.
 102. Schmid-Wendtner MH, Korting HC. The pH of the skin surface and its impact on the barrier function. Skin Pharmacol Physiol 2006; 19: 296–302.