

## Refractory Pemphigoid with Autoantibodies to Both BP230 and Laminin gamma1

Himino ASHIDA<sup>1</sup>, Toshihisa HAMADA<sup>1\*</sup>, Yoichiro HOSOKAWA<sup>1</sup>, Takashi HASHIMOTO<sup>2</sup>, Wataru NISHIE<sup>3</sup>, Norito ISHII<sup>4</sup>, Takekuni NAKAMA<sup>4</sup>, Taisuke KANNO<sup>5</sup> and Masami IKEDA<sup>1</sup>

<sup>1</sup>Department of Dermatology, Takamatsu Red Cross Hospital, 4-1-3 Ban-cho, Takamatsu, Kagawa 760-0017, <sup>2</sup>Department of Dermatology, Osaka City University Graduate School of Medicine, Osaka, <sup>3</sup>Department of Dermatology, Hokkaido University Graduate School of Medicine, Sapporo, <sup>4</sup>Department of Dermatology, Kurume University School of Medicine, Kurume, <sup>5</sup>Department of Dermatology, Okayama University Graduate School of Medicine, Dentistry and Pharmaceutical Sciences, Okayama, Japan. E-mail: t-hamada@cc.okayama-u.ac.jp

Accepted Aug 22, 2019; E-published Aug 22, 2019

Bullous pemphigoid (BP) is characterized by autoantibody production against BP180, one of the structural proteins in the dermal–epidermal junction of the skin (1). Patients with BP can also have circulating autoantibodies against BP230, one of the plakin family proteins localized in the inner plaque of the hemidesmosomes (2).

Several molecules other than BP180 constituting the dermal–epidermal junction have been identified as autoantigens in BP and other types of pemphigoid (1). For instance, anti-p200 (or anti-laminin  $\gamma$ 1) pemphigoid is a distinct autoimmune subepidermal blistering disorder characterized by circulating autoantibodies against laminin  $\gamma$ 1, a 200-kDa glycoprotein localized to the basement membrane zone (BMZ) of the skin (3).

We hereby report a rare case of a Japanese patient with pemphigoid resistant to high-dose corticosteroid and oral colchicine, who had circulating autoantibodies against both BP230 and laminin  $\gamma$ 1 but not BP180.

### CASE REPORT

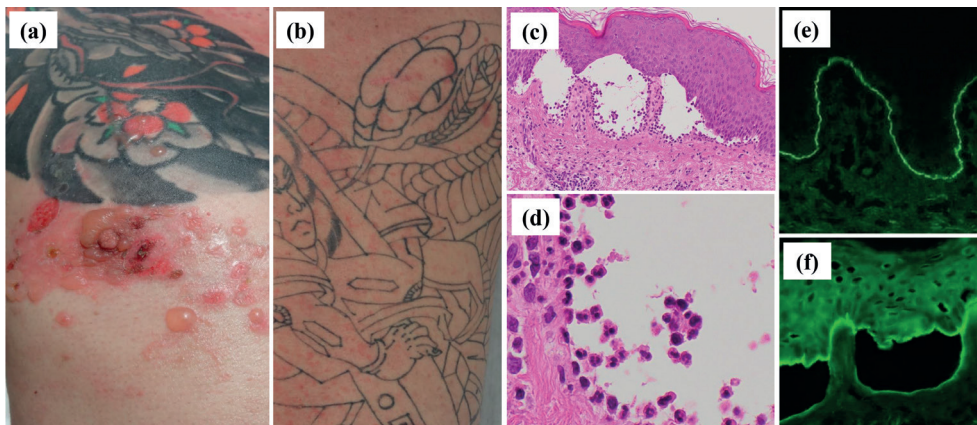
A 50-year-old Japanese man first noticed itchy erythematous papules on his trunk and extremities. He was referred to us because of his recalcitrant clinical course, which was suggestive of prurigo chronica multiformis. He had been treated with a potent topical corticosteroid and oral antihistamines with a favorable clinical course. However, 4 years later, his eruption intensified rapidly with the development of multiple itchy erythematous patches and vesicles, and severe itching began to interfere with his sleep. He had tattoos on almost his entire trunk and extremities dating back to his late 20s. He had no history of psoriasis.

A physical examination revealed widespread, coalescent infiltrating erythematous patches and multiple vesicles that were distributed independently of the sites of his tattoos (Fig. 1a, b). No

mucosal lesions were observed. Routine laboratory tests revealed a white blood cell count of 13,330/ $\mu$ l with 4.7% eosinophils, increased serum levels of IgE at 23,314 IU/ml (3–311) and CC chemokine ligand 17 at 584 pg/ml (0–449). A biopsy specimen from a vesicle showed subepidermal blister formation with many eosinophils and neutrophils bound to the dermal side of the blisters (Fig. 1c,d). Direct immunofluorescence showed a linear deposit of IgG on the BMZ (Fig. 1e). Indirect immunofluorescence detected circulating IgG class autoantibodies reacting to both the epidermal and dermal sides of 1M NaCl split skin (Fig. 1f). Enzyme-linked immunosorbent assays (ELISAs) were positive for N-terminal and C-terminal domains of BP230 (index 23.53, cut-off <9), but negative for the BP180 NC16A domain, and the NC1 and NC2 domains of type VII collagen (MBL, Nagoya, Japan). ELISA for full-length BP180 showed a negative result (4). Immunoblotting (IB) using normal human epidermal extract as a substrate showed that the patient's IgG autoantibodies reacted weakly but clearly with BP230, but not with BP180 (Fig. S1a<sup>1</sup>), compatible with the results of the ELISAs. No positive reactivity was detected by IB using either BP180 NC16A domain recombinant protein (Fig. S1b<sup>1</sup>). IB using normal human dermal extract demonstrated that the patient's IgG autoantibodies reacted with the 200-kDa laminin  $\gamma$ 1, but not with the 290-kDa type VII collagen, thereby ruling out the possibility of epidermolysis bullosa acquisita (Fig. S1c<sup>1</sup>). Based on the above findings, a diagnosis of pemphigoid with IgG autoantibodies to both laminin  $\gamma$ 1 and BP230 with a bullous pemphigoid disease area index (BPDAI) score of 33 was made.

The patient was initially treated with intravenous methylprednisolone pulse therapy (1,000 mg daily, for 3 consecutive days) followed by oral prednisolone 40 mg daily (Fig. S2<sup>1</sup>). Because of the refractory clinical course with corticosteroid therapies alone, we added diaminodiphenyl sulfone 50 mg daily and colchicine 1.5 mg daily, with only slight beneficial effect. Frequent recurrences of erythema with severe itching continuously interfered with his sleep. Eventually, combination therapy of oral cyclosporine and

<sup>1</sup><https://doi.org/10.2340/00015555-3294>



**Fig. 1. Clinical, histopathological and immunofluorescence findings.** (a,b) Multiple erythematous papules and vesicles on the trunk and extremities. (c,d) Subepidermal blister formation with many eosinophils and neutrophils [hematoxylin and eosin stain; original magnification (c) x40, (d) x200]. (e) Direct immunofluorescence shows a linear deposit of IgG on the basement membrane zone (x100). (f) Indirect immunofluorescence using 1M NaCl split skin detects circulating IgG class autoantibodies reacting to both the epidermal and dermal sides (x100).

azathioprine with an additional round of intravenous methylprednisolone pulse therapy was required to fully control the disease activity and reduce the BPDAI score to 0 at hospital day 88 (Fig. S2<sup>1</sup>). A gradual tapering of oral prednisolone, cyclosporine and azathioprine was performed with a favorable clinical course. Ten months after initiating therapy, he had no recurrence with oral prednisolone 12.5 mg daily and cyclosporine 50 mg daily.

## DISCUSSION

Circulating anti-BP230 autoantibodies are detected in 50–60% of BP patients (5). No correlation has been observed between disease activity and serum levels of anti-BP230 autoantibodies. Thus, the pathogenic role of anti-BP230 autoantibodies is still unclear, mainly because of their intracellular localization (6). In rare cases of BP with autoantibodies against BP230, no circulating anti-BP180 autoantibodies are detected (4, 7, 8). These patients, whose condition is referred to as “BP230-type BP”, tend to show a milder clinical course (7, 8). Our patient, who was diagnosed as having both anti-p200 pemphigoid and BP230-type BP, showed an active inflammatory phenotype with resistance to potent corticosteroid therapy.

Anti-p200 pemphigoid presents with BP-like urticarial erythematous patches or plaques with tense blisters, vesicles and erosions, occasionally associated with pre-existing psoriasis (3, 9). A male predominance has been observed, with the M/F ratio ranging from 1.8 to 2.1. The median age has been reported to range from 72 to 82 years (9, 10). Histopathology of the affected skin shows dense neutrophilic infiltrates in the papillary dermis. About 25% of patients with anti-laminin  $\gamma$ 1 pemphigoid have concomitant autoantibodies against BP180, BP230, laminin 332, and type VII collagen (9). Two pemphigoid patients with autoantibodies to both BP230 and laminin  $\gamma$ 1 have previously been reported (11, 12). Patients with anti-p200 pemphigoid could have a more heterogeneous clinical course than previously suspected (10).

In indirect immunofluorescence using 1M NaCl-split-skin, our patient exhibited reactions on both the epidermal and dermal sides, which are considered to represent the reactivities with BP230 and laminin  $\gamma$ 1, respectively. However, our patient lacked circulating anti-BP180 autoantibodies, which are generally considered pathogenic in BP. In an *ex-vivo* model using cryosections of human skin and leukocytes of healthy controls, the sera from patients with anti-p200 pemphigoid were reported to accumulate leukocytes to the dermal–epidermal junction by binding between its Fc region and Fc $\gamma$  receptor, leading to dermal–epidermal separation (13). In our patient, as shown in Fig. 1d, many eosinophils and neutrophils were bound to the dermal side of the subepidermal blisters, where anti-laminin  $\gamma$ 1 autoantibodies should be bound. Taking these results together, we consider that anti-laminin  $\gamma$ 1 autoantibodies, rather than anti-BP230 autoantibodies, may have been the cause of the blister formation in the present case. Anti-BP230 autoantibodies might be produced as an epiphenomenon by

intermolecular epitope spreading, as a result of continuous antigen exposure to the host immune system after the initial tissue injury caused by anti-laminin  $\gamma$ 1 autoantibodies (14, 15). However, anti-BP230 autoantibodies might also have relatively weak pathogenic effects (8).

In conclusion, anti-laminin  $\gamma$ 1 autoantibodies, with add-on effects by anti-BP230 autoantibodies, may have induced the recalcitrant clinical course with resistance to corticosteroid therapy in our patient. Combination therapy of immunosuppressants and high-dose corticosteroids including two rounds of intravenous methyl-PSL pulse therapy was required to fully control the disease activity.

*The authors have no conflicts of interest to declare.*

## REFERENCES

- Goletz S, Zillikens D, Schmidt E. Structural proteins of the dermal-epidermal junction targeted by autoantibodies in pemphigoid diseases. *Exp Dermatol* 2017; 26: 1154–1162.
- Stanley JR, Tanaka T, Mueller S, Klaus-Kovtun V, Roop D. Isolation of complementary DNA for bullous pemphigoid antigen by use of patients' autoantibodies. *J Clin Invest* 1988; 82: 1864–1870.
- Dainichi T, Koga H, Tsuji T, Ishii N, Ohyama B, Ueda A, et al. From anti-p200 pemphigoid to anti-laminin gamma1 pemphigoid. *J Dermatol* 2010; 37: 231–238.
- Izumi K, Nishie W, Mai Y, Wada M, Natsuga K, Ujiie H, et al. Autoantibody Profile Differentiates between Inflammatory and Noninflammatory Bullous Pemphigoid. *J Invest Dermatol* 2016; 136: 2201–2210.
- Blöcker IM, Dähnrich C, Probst C, Komorowski L, Saschenbrecker S, Schlumberger W, et al. Epitope mapping of BP230 leading to a novel enzyme-linked immunosorbent assay for autoantibodies in bullous pemphigoid. *Br J Dermatol* 2012; 166: 964–970.
- Kromminga A, Sitaru C, Hagel C, Herzog S, Zillikens D. Development of an ELISA for the detection of autoantibodies to BP230. *Clin Immunol* 2004; 111: 146–152.
- Nakama K, Koga H, Ishii N, Ohata C, Hashimoto T, Nakama T. Clinical and immunological profiles of 14 patients with bullous pemphigoid without IgG autoantibodies to the BP180 NC16A domain. *JAMA Dermatol* 2018; 154: 347–350.
- Hayakawa T, Teye K, Hachiya T, Uehara R, Hashiguchi M, Kawakami T, et al. Clinical and immunological profiles of anti-BP230-type bullous pemphigoid: Restriction of epitopes to C-terminal domain of BP230 shown by novel ELISAs of BP230-domain specific recombinant proteins. *Eur J Dermatol* 2016; 26: 155–163.
- Goletz S, Hashimoto T, Zillikens D, Schmidt E. Anti-p200 pemphigoid. *J Am Acad Dermatol* 2014; 71: 185–191.
- Commin MH, Schmidt E, Duvert-Lehembre S. Clinical and immunological features and outcome of anti-p200 pemphigoid. *Br J Dermatol* 2016; 175: 776–781.
- Imanishi A, Tateishi C, Imanishi H, Sowa-Osako J, Koga H, Tsuruta D, et al. Pemphigoid with antibodies to laminin  $\gamma$ 1, BP180 and BP230, associated with psoriasis vulgaris: successful disease control with cyclosporin. *J Dermatol* 2015; 42: 394–397.
- Honda Y, Dainichi T, Nishie W, Ujiie H, Hattori Y, Miyachi Y, et al. Subepidermal autoimmune bullous disease affecting predominantly mucocutaneous junctions and the palms with autoantibodies to BP230 and laminin  $\gamma$ 1. *Br J Dermatol* 2016; 175: 619–621.
- Vafia K, Groth S, Beckmann T, Hirose M, Dworschak J, Recke A, et al. Pathogenicity of autoantibodies in anti-p200 pemphigoid. *PLoS One* 2012; 7: e41769.
- Chan LS, Vanderlugt CJ, Hashimoto T, Nishikawa T, Zone JJ, Black MM, et al. Epitope spreading: lessons from autoimmune skin diseases. *J Invest Dermatol* 1998; 110: 103–109.
- Di Zenzo G, Thoma-Uszynski S, Calabresi V, Fontao L, Hofmann SC, Lacour JP, et al. Demonstration of epitope-spreading phenomena in bullous pemphigoid: results of a prospective multicenter study. *J Invest Dermatol* 2011; 131: 2271–2280.