

An Unusual Birthmark on the Scalp: A Quiz

Yue-Tong QIAN¹, Jin-Yuan MA², Sergio VANO-GALVAN³, Jia-Wei LIU¹, Wei LIU¹ and Dong-Lai MA¹

¹Department of Dermatology, Peking Union Medical College Hospital, Chinese Academy of Medical Sciences and Peking Union Medical College, Beijing, ²Preventive Medicine, School of Public Health, Southern Medical University, Guangzhou, China, and ³Department of Dermatology, Hospital Ramon y Cajal, Madrid, Spain. E-mail: mdonglai@sohu.com

A 13-year-old girl presented with an unusual asymptomatic birthmark on her scalp. The birthmark increased in size gradually in proportion to the patient's growth. Her physical and mental development was normal and there were no other associated neurological, skeletal or congenital anomalies. There was no family history of this disorder and no consanguinity. Physical examination revealed a 5 × 8 cm alopecic patch on the vertex of her scalp. The lesion consisted of aggregated comedo-like pits and scars (Fig. 1). Skin biopsy was taken for histopathological examination.

What is your diagnosis? See next page for answer.

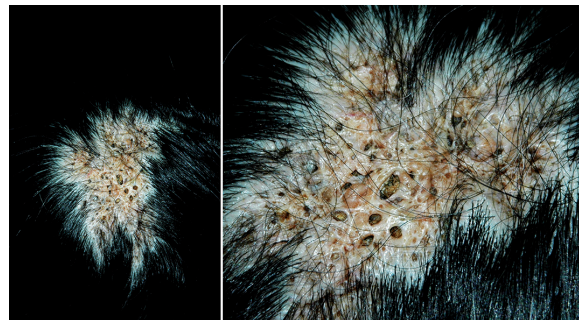


Fig. 1. A circumscribed alopecic plaque on the vertex of the scalp. The lesion consisted of aggregated comedo-like pits, papules, nodules and scars.

ANSWERS TO QUIZ

An Unusual Birthmark on the Scalp: A Commentary

Acta Derm Venereol 2019; 99: 846–847.

Diagnosis: Naevus comedonicus of the scalp

Skin biopsy revealed a hyperkeratotic epidermis with cup-shaped follicular plugging (Fig. 2). Arrector pili muscles and sebaceous glands were absent. A diagnosis of naevus comedonicus (NC) was made based on the clinical and histological findings. The patient was referred to plastic surgery for treatment. The lesion was excised successfully with no complications.

NC is a rare subtype of epidermal naevus first described by Kofmann in 1895 (1). It has been considered a hamartoma of the pilosebaceous unit, resulting in developmental defect in production of mature hairs, matrix cells, or sebaceous glands. Only soft keratin can be formed, which results in dilated follicular orifices (2). Somatic mutation of the fibroblast growth factor receptor 2 gene (*FGFR-2*) is thought to be an important factor in the pathogenesis of NC (3). NC can be associated with central nervous system, ocular and skeletal abnormalities in the context of naevus comedonicus syndrome (4).

Clinically, the lesions of NC may present shortly after birth or may develop during early childhood (most commonly before the age of 10 years) (5). Growth of the lesions appears to be proportional to age, but may be accelerated during puberty due to the increase in eccrine and sebaceous secretions (4). NC is characterized by multiple

asymptomatic dilated follicular openings with dark keratinous plugs resembling comedo-like lesions in a linear, unilateral distribution along Blaschko's lines or presenting as a circumscribed plaque. Occasionally, it may associate with bacterial infections, drainage, cyst formation, and scarring, which is an inflammatory subtype of NC (6). The lesions are most commonly located on the face, neck, trunk and upper extremities. Involvement of the palms, soles and genitals has also been reported. However, involvement of the scalp is extremely rare (2, 6–8). Histology typically reveals grouped immature follicles with dilated keratin-filled invagination of the epidermis, devoid of hair shafts or well-formed sebaceous glands (7). Immunohistochemical findings showed an increased expression of proliferating cell nuclear antigen (PCNA), intercellular adhesion molecule-1 (ICAM-1), HLA-DR and CD68 (9). Clinical differential diagnosis includes acne conglobata, naevus sebaceous, epidermal naevi, Favre-Racouchot syndrome and familial dyskeratotic comedones.

NC are thought to have a benign course, but association with squamous cell carcinoma has been reported recently; thus surgical treatment or close monitoring of these patients is recommended (10). Other treatment options include systemic retinoids, topical therapy (retinoic acid, salicylic acid, 12% ammonium lactate) and ablative laser treatment (ultrapulse carbon-dioxide lasers, erbium-YAG lasers, 1450-nm diode laser), which have been used with various success (5, 8).

REFERENCES

1. Kofmann S. A case of rare localization and spreading of comedones. *Arch Dermatol Syphilol* 1895; 32: 177–178.
2. Sikorski D, Parker J, Shwayder T. A boy with an unusual scalp birthmark. *Int J Dermatol* 2011; 50: 670–672.
3. Sinha A, Natarajan S. Linear morphea, nevus comedonicus, and lichen striatus in a 5-year-old girl. *Pediatr Dermatol* 2011; 28: 72–74.
4. Bhullar A, Shamsudin N. Images in clinical medicine: nevus comedonicus. *N Engl J Med* 2015; 372: 2541.
5. Tchernev G, Ananiev J, Semkova K, Dourmishev LA, Schönlebe J, Wollina U. Nevus comedonicus: an updated review. *Dermatol Ther (Heidelb)* 2013; 3: 33–40.
6. Sahu P, Aggrawal K, Bansal C, Jain VK. Nevus comedonicus on scalp: an unusual presentation. *Int J Trichology* 2018; 10: 37–39.
7. Ghaninezhad H, Ehsani AH, Mansoori P, Taheri A. Naevus comedonicus of the scalp. *J Eur Acad Dermatol Venereol* 2006; 20: 184–185.
8. Kikkeri NN, Priyanka R, Parshawanath H. Nevus comedonicus on scalp: a rare site. *Indian J Dermatol* 2015; 60: 105.
9. Bongiorno MR, Pistone G, Aricò M. Naevus comedonicus immunohistochemical features in two cases. *Acta Derm Venereol* 2003; 83: 300–301.
10. Walling HW, Swick BL. Squamous cell carcinoma arising in nevus comedonicus. *Dermatol Surg* 2009; 35:144–146.

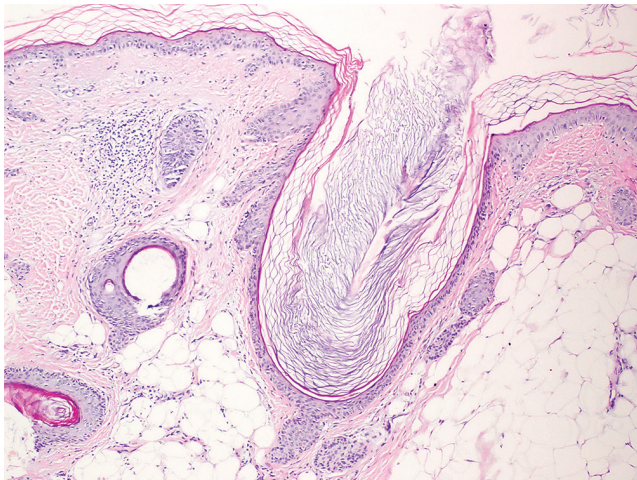


Fig. 2. A hyperkeratotic epidermis with cup-shaped follicular plugging (haematoxylin & eosin, original magnification $\times 40$).