

## A Case of Ixekizumab-induced Psoriasiform Eruption

Tomohiro OIWA, Mafumi FUJITA, Sawako TAKASE, Youichi NISHIMURA, Miyuki OTA, Kayo OKADA and Takao TACHIBANA  
 Department of Dermatology, Osaka Red Cross Hospital, 5-30 Fudegasaki-cho, Tennoji-ku, Osaka 543-8555, Japan. E-mail: tomoski@kuhp.kyoto-u.ac.jp

Accepted Feb 5, 2019; E-published Feb 6, 2019

Psoriasis is a common chronic inflammatory skin disease. The current understanding of the immunopathogenesis and inflammatory cytokine pathways enables us to develop and introduce biological therapies for the treatment of moderate to severe psoriasis (1). Anti-IL-17 (anti-interleukin-17) inhibitors, such as ixekimumab (anti-IL-17A antibody), secukinumab (anti-IL-17A antibody) and brodalumab (anti-IL-17 receptor A (IL-17RA) antibody) exert excellent therapeutic effects on psoriasis. Since IL-17 is an important cytokine for preventing fungal infections, adverse skin reactions such as cutaneous candidiasis are occasionally experienced during the administration of IL-17 inhibitors (2), however little is known about other adverse skin reactions of these inhibitors.

It is known that biologics, such as tumour necrosis factor (TNF) and interleukin (IL)-12/23 (ustekinumab) blockade, can paradoxically induce psoriasiform eruptions (3–5), although the pathogenesis remains unclear (6). As for the IL-17 inhibitors, to our knowledge, there are only two reports of psoriasiform eruptions induced by secukinumab (7, 8) and no reports for ixekizumab and brodalumab.

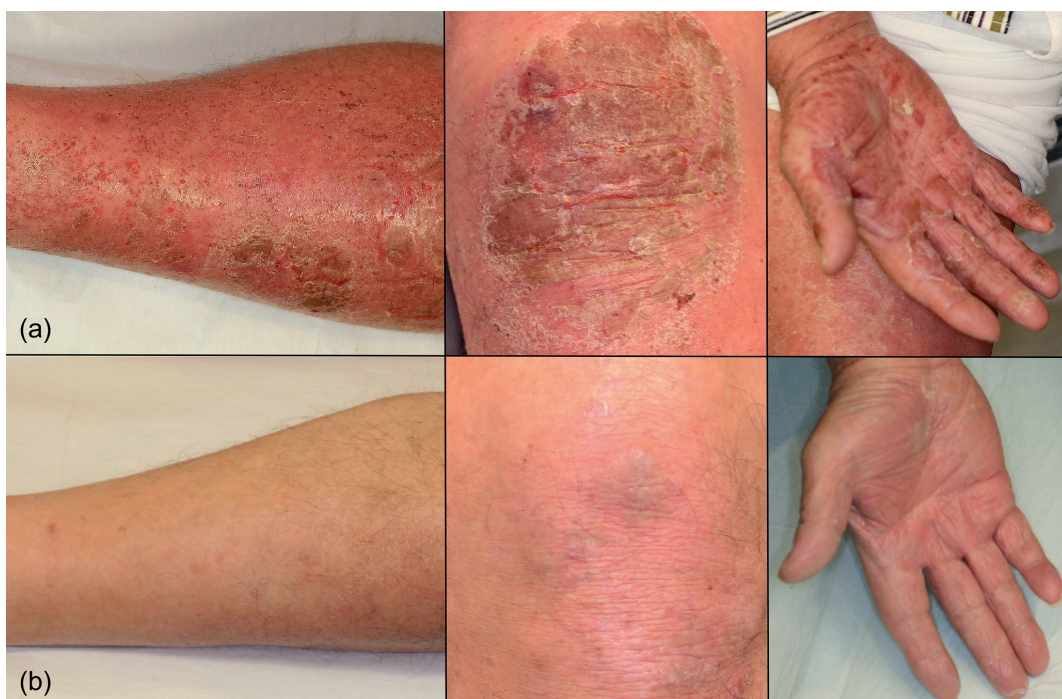Here, we report the first case of psoriasiform eruptions induced by ixekizumab.

## CASE REPORT

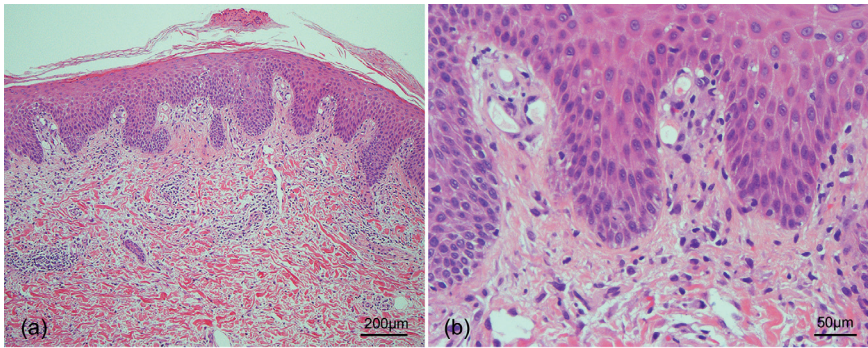
A 76-year-old man (162 cm, 56 kg) was diagnosed with psoriasis vulgaris over 20 years ago. He had been treated with topical therapies (calcipotriol/betamethasone, clobetasol propionate, and other topical corticosteroids) and narrowband UVB (ultraviolet B) phototherapy; however, the psoriatic lesions were persistent on the elbows, dorsum of the hands, knees and lower limbs.

He was treated with ixekizumab (80 mg/2 weeks/body), and by 4 weeks of treatment, the psoriatic lesions disappeared, except on the knees. The fifth dose of ixekizumab was administered 8 weeks after the initiation of treatment, when mild scaly erythema developed on the lower limbs, which was not observed before. Fungal infection was negative in the lesions. Three days later, both erythema and oedema were observed on most of the body including the palms and soles (Fig. 1a), and the body temperature was up to 38.0°C. Because the skin lesions progressed to erythroderma accompanied by thick scales, the sixth dose of ixekizumab was not administered and clobetasol ointment was started. Skin biopsy from the scaly erythema on his left thigh, presented pathological findings compatible with psoriasis (Fig. 2).

Three weeks after the last administration of ixekizumab, the scaly erythema and oedema improved, however, psoriatic lesions were still persistent, especially on palms, soles, and lower limbs. We therefore started oral cyclosporine (150 mg/day) treatment. One week later, these skin lesions gradually improved, and we continued the administration of cyclosporine as the patient refused further biological treatments. Twelve weeks after the last administration of ixekizumab, the skin lesions were mostly resolved.



**Fig. 1. Clinical findings.** (a) After the fifth dose of ixekizumab, both erythema and oedema were observed on most of the body, including the palms and soles. (b) Twelve weeks after the last administration of ixekizumab, the skin lesions were mostly resolved. However, the skin lesions on the knees remained. Minimal scaly erythema was observed on the knees.



**Fig. 2. Histopathological findings.** (a) Low-magnification view ( $\times 40$ ). Hyperkeratosis with parakeratosis was observed, and the epidermis showed acanthosis with regular elongation of rete ridges. (b) High-magnification view ( $\times 100$ ). Neutrophils and lymphocytes infiltrated moderately in superficial dermis, and slight interface change and dilated papillary blood vessels were observed.

However, the skin lesions on the knees remained. Minimal scaly erythema was observed on the knees. (Fig. 1b).

## DISCUSSION

We experienced a case of psoriasiform eruptions that developed during treatment with ixekizumab. Because the psoriasiform eruptions in our patient flared after the administration of ixekizumab and the discontinuation of treatment improved the skin lesions, it is strongly suspected that ixekizumab paradoxically induced the psoriasiform eruptions. Certainly, it is difficult to completely rule out the possibility that ixekizumab induced an acute exacerbation of eczema in a psoriasis patient as the pathogenesis in our case is different from that of a paradoxical psoriasiform eruption induced by TNF- $\alpha$  blocking agents.

The occurrence of psoriasiform eruptions induced by the biologics, mainly TNF- $\alpha$  blocking agents, is known as a paradoxical reaction. The most popular hypothesis is due to the disequilibrium in the cytokine balance. Psoriasis involves 3 major cytokines, TNF- $\alpha$ , IFN type I (interferon type I) and the IL-23/Th17 axis, which are interwoven in the pathogenesis of psoriasis and are linked in a triangular interplay. Thus, targeting one of these cytokines may influence the other two axes (9). In this sense, it is known that TNF- $\alpha$  blocking agents increase the expression of IFN- $\alpha$ , and induce the psoriasiform eruptions (6). Psoriasiform eruptions have also been reported with various other biological agents, such as rituximab (10), abatacept (11), tocilizumab (12), ustekinumab, and IL-17 inhibitors. Their pathogenesis is still unclear, but possibly related to the imbalance in the cytokine pathways like the psoriasiform eruptions that are induced by the TNF- $\alpha$  blocking agents.

Although there are no reports on the paradoxical psoriasiform eruptions induced by IL-17RA antibody, anti-IL-17A antibody-induced psoriasiform eruptions have been reported. IL-17RA antibody, unlike anti-IL-17A antibody, blocks not only IL-17A, but also other members of the IL-17 family. The blockage of IL-17A only, may possibly provoke the activation of the other members of IL-17 families. Indeed, the other members of IL-17

families are considered to possess pro-inflammatory functions (13).

Herein, we report the first case of psoriasiform eruption, which was possibly induced by ixekizumab. Clinicians should therefore be aware that anti-IL-17A antibody such as secukinumab and ixekizumab may induce paradoxical psoriasiform eruptions.

*The authors have no conflicts of interest to declare.*

## REFERENCES

1. Harden JL, Krueger JG, Bowcock AM. The immunogenetics of Psoriasis: A comprehensive review. *J Autoimmun* 2015; 64: 66–73.
2. Huppler AR, Bishu S, Gaffen SL. Mucocutaneous candidiasis: the IL-17 pathway and implications for targeted immunotherapy. *Arthritis Res Ther* 2012; 14: 217.
3. Ciccarelli F, De Martinis M, Sirufo MM, Ginaldi L. Psoriasis induced by anti-tumor necrosis factor alpha agents: a comprehensive review of the literature. *Acta Dermatovenerol Croat* 2016; 24: 169–174.
4. Sladden MJ, Clarke PJ, Wettenhall J. Infliximab-induced palmoplantar pustulosis in a patient with crohn disease. *Arch Dermatol* 2007; 143: 1449.
5. Hay RA, Pan JY. Paradoxical flare of pustular psoriasis triggered by ustekinumab, which responded to adalimumab therapy. *Clin Exp Dermatol* 2014; 39: 751–752.
6. Toussiot É, Aubin F. Paradoxical reactions under TNF- $\alpha$  blocking agents and other biological agents given for chronic immune-mediated diseases: an analytical and comprehensive overview. *RMD Open* 2016; 2: e000239.
7. Sladden MJ, Sladden CS, Gulliver WPF. Secukinumab-induced psoriasiform eruption. *JAMA Dermatol* 2017; 153: 1194–1195.
8. Noell C, McQuade B, Gottlieb A, Rosmarin D. Anti IL-17 flared psoriasis in a patient on secukinumab. *Dermatol Ther* 2017 May 26 [Epub ahead of print].
9. Grine L, Dejager L, Libert C, Vandenbroucke RE. An inflammatory triangle in psoriasis: TNF, type I IFNs and IL-17. *Cytokine Growth Factor Rev* 2015; 26: 25–33.
10. Guidelli GM, Fioravanti A, Rubegni P, Feci L. Induced psoriasis after rituximab therapy for rheumatoid arthritis: a case report and review of the literature. *Rheumatol Int* 2013; 33: 2927–2930.
11. Kato K, Satoh T, Nishizawa A, Yokozeki H. Psoriasiform drug eruption due to abatacept. *Acta Derm Venereol* 2011; 91: 362–363.
12. Laurent S, Le Parc JM, Clérico T, Bréban M, Mahé E. Onset of psoriasis following treatment with tocilizumab. *Br J Dermatol* 2010; 163: 1364–1365.
13. Marinoni B, Ceribelli A, Massarotti MS, Selmi C. The Th17 axis in psoriatic disease: pathogenetic and therapeutic implications. *Auto-Immun Highlights* 2014; 5: 9–19.