

Vascular Mass of the Scalp in a Newborn: A Quiz

Afi-Emiliène EDEE¹, Matthias TALLEGAS², Anne JOURDAIN³, Antoine LISTRAT⁴, Baptiste MOREL⁵ and Annabel MARUANI¹

¹Department of Dermatology, Unit of Paediatric Dermatology, Reference Center for Vascular Anomalies – MAGEC, ²Department of Pathology, ³Department of Pediatric Oncology, ⁴Department of Pediatric neurosurgery, and ⁵Department of Pediatric Radiology, University Hospital Center of Tours, FR-37044 Tours Cedex 9, France. E-mail: a.edee@chu-tours.fr

A female infant, 5 weeks old, was referred to our hospital for a congenital mass, located in the left parietal area of the skull. She had no family history and was born at term with the use of forceps for delivery. After birth, the mass, that had been considered a hematoma, progressively increased in volume but did not seem to cause any pain. At age 5 weeks (Fig. 1a), the infant underwent Doppler ultrasonography that showed a highly vascularized solid tumor. MRI (magnetic resonance imaging) revealed a left parietal subcutaneous mass, heterogeneous with hemorrhagic ranges (hyper T1 signal). There were also liquid ranges (hyper T2 and hypo T1 signals). There were no intracerebral anomalies or ce-

rebral effusion (Fig. 1c). CT (computer tomography) scan was performed for a better view of the bone. We observed a thinning of the parietal bone and focal interruption of the cortex over a few millimeters on the opposite side of the lower part of the lesion. Also, focal bone interruptions were observed, with no intracranial anomalies.

Conclusions from imaging favored an atypical infantile hemangioma. A beta-blocker test, 2 mg/kg/day, was not efficacious after 15 days (Fig. 1b). The decision was made to surgically remove the entire lesion, when the infant turned 2 months (Fig. 1d).

What is your diagnosis? See next page for answer.

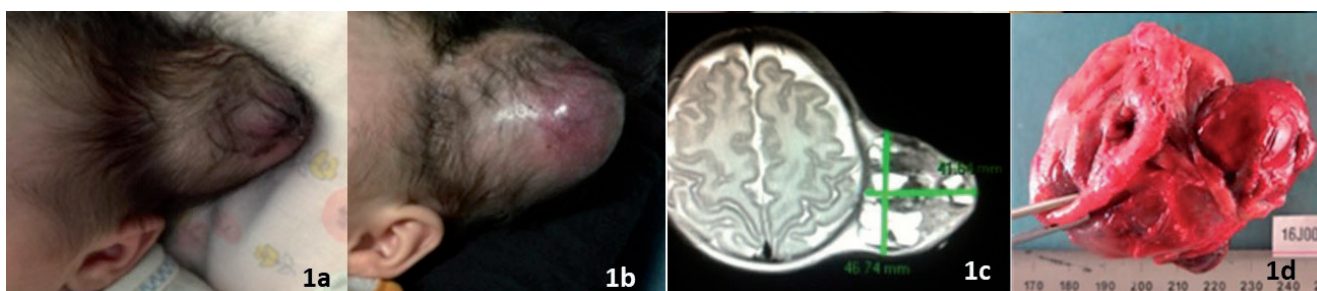


Fig. 1. Clinical features and imaging of the tumor. a) Congenital mass of the skull in a 5 week-old girl; b) At the age of 2 months, the mass had increased in size; c) MRI revealed a heterogeneous mass with hemorrhagic ranges (hyper T1 signal); d) The tumor was removed (macroscopy).

ANSWERS TO QUIZ

Vascular Mass of the Scalp in A Newborn: A Commentary

Acta Derm Venereol 2019; 99: 627–628.

Diagnosis: Congenital fibrosarcoma

Microscopy examination showed a densely cellular proliferation, largely entangled in hemorrhagic patches, made of monotonous fusiform or ovoid cells, with a fascicular growth pattern and areas of hemangiopericytoma-like vascularization. Tumor cells exhibited low to moderate cytologic atypia but high mitotic activity (15 mitosis/2 mm²). Tumor cells showed focal expression of high mobility group AT-hook 2 (*HMGA2*) but were negative for desmine. CD34 and ETS-related gene ERG highlighted the abundant capillary network. The proliferation index (Ki67) was estimated to be about 35%. Molecular findings revealed an ETS translocation variant 6/neurotrophic receptor tyrosine kinase 3 (*ETV6/NTRK3*), which is specific for infantile fibrosarcoma among pediatric skin tumors.

The lesion was entirely removed and additional explorations showed no metastasis. There was no additional treatment. After a 2 year and 6 month-follow-up, the child was in very good health and showed complete remission of the fibrosarcoma.

Congenital infantile fibrosarcoma is a rare malignant soft-tissue neoplasm, although one of the most frequent cutaneous congenital neoplasms. It often involves extremities and might be located on the scalp (1). This tumor might be confused with a rapidly involuting congenital hemangioma (RICH), which is a vascular tumor that usually decreases in

volume in the first month of life (2). Subcutaneous infantile hemangioma is another differential diagnosis (3), because both tumors increase in volume after birth. MRI and CT scan can help in the diagnosis, but in our case, imaging was not sufficient (4). Pathological and molecular methods are necessary for the diagnosis, revealing the specific gene translocation *ETV6/NTRK3*.

The prognosis of congenital fibrosarcoma is usually quite good, depending on the extent of the tumor. Treatment is based on complete surgical excision. Adjuvant chemotherapy is required for metastasis (5).

Our case highlights the need for surgical samples or resection for atypical vascular lesions mimicking infantile or congenital hemangioma.

REFERENCES

1. Ud Din N, Minhas K, Shamim MS, Mushtaq N, Fadoo Z. Congenital (infantile) fibrosarcoma of the scalp: a case series and review of literature. *Childs Nerv Syst* 2015; 31: 2145–2149.
2. Hu Z, Chou PM, Jennings LJ, Arva NC. Infantile fibrosarcoma – a clinical and histologic mimicker of vascular malformations: case report and review of the literature. *Pediatr Dev Pathol* 2013; 16: 357–363.
3. Enos T, Hosler GA, Uddin N, Mir A. Congenital infantile fibrosarcoma mimicking a cutaneous vascular lesion: a case report and review of the literature. *J Cutan Pathol* 2017; 44: 193–200.
4. Ainsworth KE, Chavhan GB, Gupta AA, Hopyan S, Taylor G. Congenital infantile fibrosarcoma: review of imaging features. *Pediatr Radiol* 2014; 44: 1124–1129.
5. PDQ Pediatric Treatment Editorial Board. Childhood Soft Tissue Sarcoma Treatment (PDQ®): Health Professional Version. PDQ Cancer Information Summaries [Internet]. Bethesda (MD): National Cancer Institute (US); 2002–2018 Apr 2.

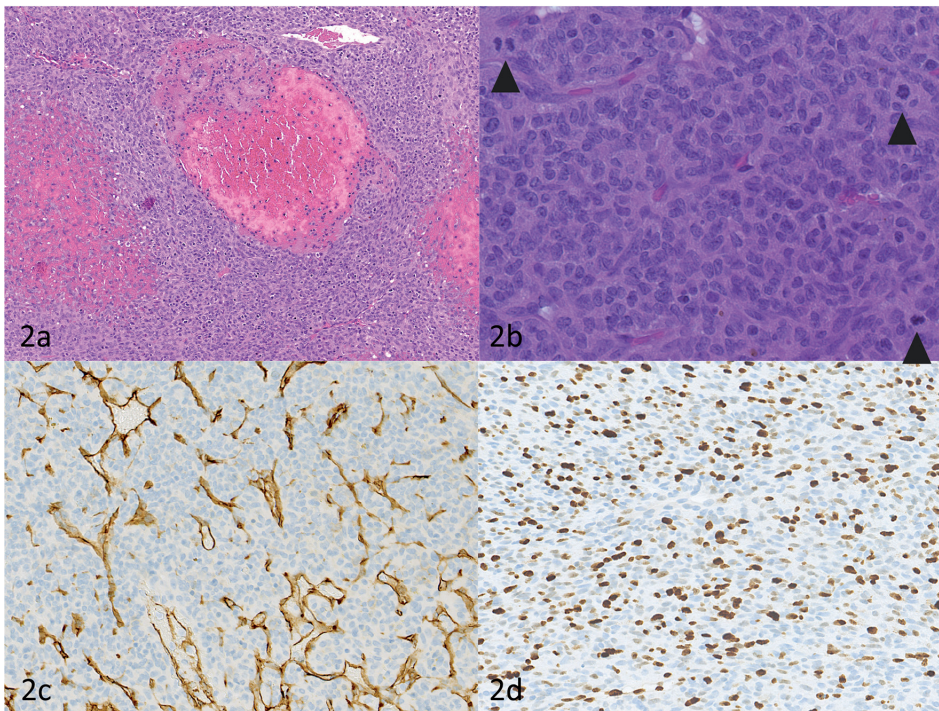


Fig. 2. Histological and immunohistochemical features of the tumor. a. The tumor had a high cellular density and haemorrhagic pools [H&E staining, x100 magnification]; b. At higher magnification, the proliferation was made of monotonous spindle to ovoid cells, showing low nuclear atypia but frequent mitotic figures (black arrows) [H&E staining, x400 magnification]; c. Tumor cells were negative for CD34, which in contrast highlighted the abundant and often hemangiopericytoma-like vascularization; d. High mitotic activity of the tumor (Ki67 35%).