

## Effect of Topical Rapamycin 1% on Multiple Trichoepitheliomas

Isabelle DREYFUS<sup>1</sup>, Giuliana ONNIS<sup>1</sup>, Emilie TOURNIER<sup>2</sup>, Olivier DEREURE<sup>3</sup> and Juliette MAZEREEUW-HAUTIER<sup>1</sup>

<sup>1</sup>Reference Centre for Rare Skin Diseases, (CRM RP), Dermatology Department, CHU Larrey, 24, Chemin de Pourville, FR-31400 Toulouse Cedex 09, <sup>2</sup>Laboratory of Pathological Anatomy and Cytology, CHU Oncopole, Toulouse, and <sup>3</sup>Dermatology of Department and INSERM U1058 University of Montpellier, Montpellier, France. E-mail: dreyfus.i@chu-toulouse.fr

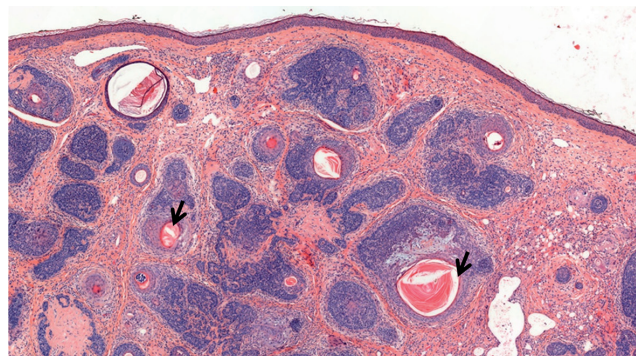
Accepted Jan 15, 2019; E-published Jan 17, 2019

Trichoepitheliomas are benign adnexal neoplasms with follicular differentiation that can occur as isolated sporadic lesions or as part of multiple familial trichoepitheliomas (MFT) syndrome, a phenotypic variant of Brooke-Spiegler syndrome associated with autosomal dominant mutations of the tumour suppressor gene *CYLD* (16q12.1) (1, 2). In the MFT setting, trichoepitheliomas appear during childhood as multiple skin-coloured papules or small nodules, usually present with a symmetrical distribution and localized on the scalp, neck and face (with predominance on the nose, cheeks, forehead, nasolabial folds and inner aspects of the eyebrows). Trichoepitheliomas progressively increase in number and size over years and usually result in significant aesthetic disfiguring. Brinkhuizen et al. (3) recently demonstrated that, similarly to tuberous sclerosis (4), the pathogenesis of trichoepitheliomas involves an activation of the mammalian target of rapamycin (mTOR) signalling pathway. We report here the effect of topical rapamycin 1%, an efficient topical treatment of cutaneous angiofibroma, in patients with tuberous sclerosis, on trichoepitheliomas of 5 patients with MFT.

### CASE REPORTS

The patients' characteristics are summarized in Table S1<sup>†</sup>. All trichoepitheliomas were histologically confirmed, showing basaloid lobules with keratocysts and infundibular keratinization without epidermal continuity, and with cellular fibroblastic stroma (Fig. 1). All patients were female, with a median age of 45 years (range 26–54 years). Lesions first appeared at the median age of 15 years (range 4–23 years) and were located exclusively on the face (front, nose, nasolabial folds). The number of lesions was between 20 and 500, and their diameter ranged from 2 to 5 mm. Molecular analysis was conducted in one patient showing a heterozygous mutation on exon 19 of the *CYLD* gene: c.2625dupT (p.Val876Cysfs\*14). All patients had received prior topical and/or systemic treatments, including CO<sub>2</sub> laser vaporization, 5% imiquimod cream and oral acitretin (maximum daily dosage 30 mg (0.5 mg/kg/day)).

All patients were treated twice daily with a topical formulation of rapamycin 1%, in an emollient cream containing glycerol 15%/petroleum jelly 8%/liquid paraffin 2%. None of the patients used concomitant treatments. Efficacy and tolerance were evaluated after 2 months (M2, intermediate evaluation) and 5 months (M5, final evaluation) of uninterrupted treatment, using a visual analogical scale (VAS) from 0 to 10. Efficacy was rated by 2 different physicians, either during the visits or blindly through digital photograph analysis, and by the patients. According to the physicians' rating, the median efficacy was 1/10 (range 0–3) at M2, and 3.5/10



**Fig. 1. Trichoepithelioma (patient 2).** Basaloid lobules showing keratocysts and infundibular keratinization (arrow) without epidermal continuity, and with cellular fibroblastic stroma. Haematoxylin-eosin stain, magnification  $\times 50$ .

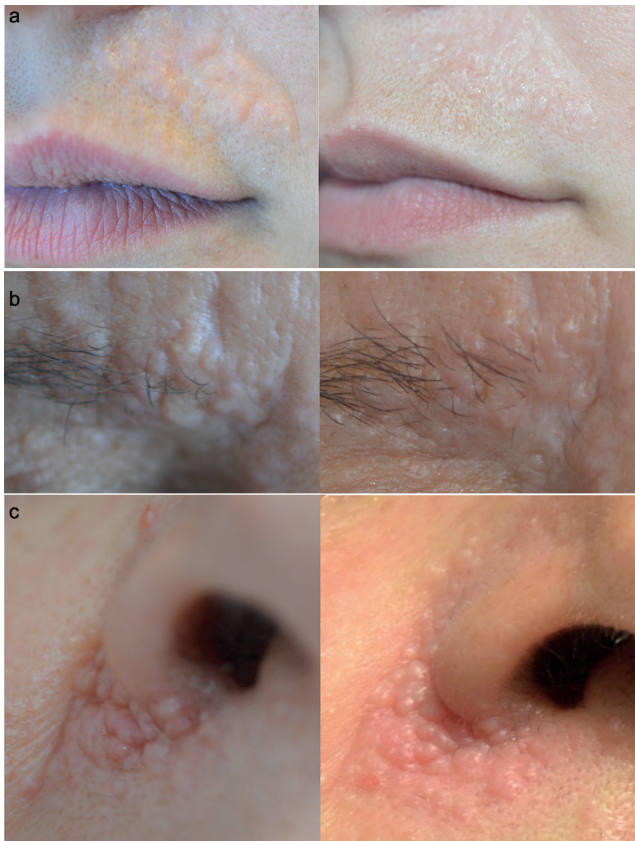(range 0–5) at M5. The clinical response was characterized by a decrease in the density of the lesions, related to a decrease in thickness and size of the lesions, rather than to a reduction in the number of lesions (Fig. 2). According to the patients' rating, the median efficacy was 6/10 (range 0–6) at M2, and 5.5/10 (range 0–6) at M5. Four patients reported an improvement in the lesions and no new lesions under treatment. Conversely, patient 5 did not report any improvement.

Tolerance was considered good by all patients, self-rated at a median score of 9/10 (range 7–10) at M2 and 10/10 (range 4–10) at M5. Four out of 5 patients reported a slight irritation of the skin within the first week of treatment. Two patients reported an increased frequency of headaches during treatment, responding to paracetamol or triptans. None stopped the treatment because of side-effects. Among the 4 patients who had an improvement in their trichoepitheliomas, 2 are currently under treatment (patients 2 and 4). Patient 3 stopped the treatment and was then treated with CO<sub>2</sub> laser. Ten months after stopping topical rapamycin, patient 1 has new lesions, but the size of treated lesions did not change.

### DISCUSSION

A number of therapeutic options have been proposed previously in MFT-related trichoepitheliomas, including surgery, dermabrasion, ablative CO<sub>2</sub> laser and cryotherapy. However, these invasive procedures have a limited efficacy and may be complicated by permanent scarring, hypopigmentation and atrophy. There is also a high risk of relapse (5, 6). Topical imiquimod also proved effective in 2 patients with solitary desmoplastic trichoepithelioma but the lesions relapsed after treatment discontinuation (7). More recently, the effect of topical mTOR inhibitors on MFT-related skin lesions was reported by Tu & Teng (2) in 2 siblings aged 6 and 8 years. A formulation of 1% rapamycin cream was applied on numerous, but small

<sup>†</sup><https://doi.org/10.2340/00015555-3116>



**Fig. 2. Multiple trichoepitheliomas localized** on (a) nasolabial folds (patient 4), (b) forehead (patient 1) and (c) ala of the nose (patient 3). Evaluation before the start of rapamycin (left), and 5 months of treatment (right).

(2–4 mm), facial trichoepitheliomas, twice daily, alone or after ablative CO<sub>2</sub> laser therapy, for a period of 7 and 12 months, respectively. Treatment was well tolerated and resulted in an interruption of the progression of the lesions, according to the authors. However, no evaluation score was provided. In line with this report, our results suggest that a topical formulation of rapamycin may reduce the thickness and size of trichoepitheliomas and reduce the occurrence of new tumours. However, the overall effect remains limited. This may be explained by incomplete penetration related to galenic formulation or by significant tumour thickness. Efficacy might therefore be optimized by occlusion, adjunction of a solubilizer agent in the formulation to increase rapamycin bioavailability, use of a more concentrated formulation, or concomitant use of ablative laser to reduce lesions thickness as in the report by Tu & Teng (2). Another reason for the limited efficacy could be that less than one-third of the trichoepitheliomas showed positive staining for mTOR (3). The limited efficacy might also be explained

by the fact that other pathways, such as the hedgehog, might play a more relevant role in the pathogenesis of trichoepitheliomas than the m-Tor pathway (8). Baur et al. (8) recently showed a significant regression of the highly differentiated TE upon vismodegib, that could be explained by the upregulation of Gli1 (glioma-associated oncogene) mRNA in these tumours, indirectly upregulated by *CYLD* mutation. Contrasting with the limited clinical impact reported by the physicians, patients self-reported a higher efficacy that may reflect their high level of request for an effective therapy for these disfiguring lesions. Tolerance appears good overall. The occurrence of headaches, a side-effect reported for oral sirolimus may suggest a systemic diffusion of the drug (9). It is notable that this side-effect was not previously reported with the topical formulation, either in tuberous sclerosis (10) or in MFT-related trichoepitheliomas (2).

In conclusion, topical rapamycin, although off-label and expensive, may be considered in MFT-related facial trichoepitheliomas. Concomitant therapy, such as prior ablative laser, may be considered in order to optimize the efficacy of the drug.

## REFERENCES

1. du Toit JP, Schneider JW, Visser WI, Jordaan HF. The clinicopathological spectrum of trichoepitheliomas: a retrospective descriptive study. *Int J Dermatol* 2016; 55: 270–277.
2. Tu JH, Teng JM. Use of topical sirolimus in the management of multiple familial trichoepitheliomas. *Dermatol Ther* 2017; 30.
3. Brinkhuizen T, Weijzen CA, Thissen MR, van Marion AM, Lohman BG, et al. Immunohistochemical analysis of the mechanistic target of rapamycin and hypoxia signalling pathways in basal cell carcinoma and trichoepithelioma. *PLoS One* 2014; 9: e106427.
4. Amin S, Lux A, Khan A, O'Callaghan F. Sirolimus ointment for facial angiofibromas in individuals with tuberous sclerosis complex. *Int Sch Res Notices* 2017; 2017:8404378.
5. Hofmann L, Kraus SL, Brauns B, Schön MP, Kretschmer L. Complex surgical therapy of multiple trichoepitheliomas. *J Dtsch Dermatol Ges* 2015; 13: 457–459.
6. Sinha K, Mallipeddi R, Sheth N, Al-Niaimi F. Carbon dioxide laser ablation for trichoepitheliomas: The largest reported series. *J Cosmet Laser Ther* 2018; 20: 9–11.
7. Seo SH, Kim GW, Sung HW. Imiquimod as an adjuvant treatment measure for desmoplastic trichoepithelioma. *Ann Dermatol* 2011; 23: 229–231.
8. Baur V, Papadopoulos T, Kazakov DV, Agaimy A, Hartmann A, Isbary G, et al. A case of multiple familial trichoepitheliomas responding to treatment with the Hedgehog signaling pathway inhibitor vismodegib. *Virchows Arch* 2018; 473: 241–246.
9. Nocera A, Andorno E, Tagliamacco A, Morelli N, Bottino G, Ravazzoni F, et al. Sirolimus therapy in liver transplant patients: an initial experience at a single center. *Transplant Proc* 2008; 40: 1950–1952.
10. Wang S, Liu Y, Wei J, Zhang J, Wang Z, Xu Z. Tuberous sclerosis complex in 29 children: clinical and genetic analysis and facial angiofibroma responses to topical sirolimus. *Pediatr Dermatol* 2017; 34: 572–577.