

# Comparison of the Treatment Outcome of Oral Tofacitinib with Other Conventional Therapies in Refractory Alopecia Totalis and Universalis: A Retrospective Study

Jung-Won SHIN<sup>1</sup>, Chang-Hun HUH<sup>1</sup>, Min-Woo KIM<sup>2</sup>, Ji-Su LEE<sup>2</sup>, Ohsang KWON<sup>2</sup>, Soyun CHO<sup>3</sup> and Hyun-sun PARK<sup>3</sup>  
 Departments of Dermatology: <sup>1</sup>Seoul National University Bundang Hospital, Gyeonggi, <sup>2</sup>Seoul National University Hospital, and <sup>3</sup>SMG-SNU Boramae Medical Center, Seoul, Korea

**Treatment of alopecia totalis and alopecia universalis is often challenging and unsatisfactory. Recently, Janus kinase inhibitor has shown promising results. The aim of this study is to compare the efficacy and tolerability of oral tofacitinib and conventional modalities for treating refractory alopecia totalis/universalis. A total of 74 patients (18 treated with tofacitinib, 26 treated with conventional oral treatment (steroid ± cyclosporine), and 30 treated with diphenylcyclopropenone) were included in the study. The patients' medical records were reviewed retrospectively. After 6 months, 44.4% of patients in the tofacitinib group, 37.5% in the conventional oral treatment group, and 11.1% in the diphenylcyclopropenone group achieved 50% improvements in the Severity of Alopecia Tool score. During treatment, 10% of patients in the tofacitinib group, 73.1% in the conventional oral treatment group, and 10% in the diphenylcyclopropenone group experienced adverse drug reactions. In conclusion, oral tofacitinib was more effective than diphenylcyclopropenone immunotherapy and more tolerable than conventional oral treatment after 6 months of treatment.**

**Key words:** alopecia totalis; alopecia universalis; cyclosporine; diphenylcyclopropenone; oral steroid; tofacitinib.

Accepted Oct 3, 2018; Epub ahead of print Oct 3, 2018

Acta Derm Venereol 2019; 99: 41–46.

**Corr:** Hyun-sun Park, SMG-SNU Boramae Medical Center, Boramae-ro-5-gil, Dongjak-gu, Seoul 07061, Korea. E-mail: snuhdm@gmail.com

Alopecia totalis (AT) and alopecia universalis (AU) are rare, extensive subtypes of alopecia areata (AA). AA is a common autoimmune dermatological disease characterized by non-scarring hairless patches on the scalp, often resulting in significant psychological distress for patients (1–3). The extent of alopecia may predict the degree of psychological distress experienced (2). Hence, given that AA can negatively influence the quality of life of patients, striving for a treatment with greater efficacy and safety is paramount. To date, despite numerous proposed treatment methods, there is no reliable and efficacious therapy for AA. Moreover, extensive forms of AA, such as AT and AU, are known to have a poorer treatment response with greater probability of developing chronic diseases (4).

## SIGNIFICANCE

Treatment of severe alopecia areata is often challenging and unsatisfactory. However, oral tofacitinib, which is approved for treatment of rheumatoid arthritis, has had promising results. This is the first study to compare the treatment outcomes of tofacitinib with other conventional therapies in patients with refractory severe alopecia areata. After 6 months of treatment, patients on tofacitinib had a higher response rate and greater tolerability than those on topical immunotherapy and oral steroid±immunosuppressant, respectively. This study will help clinicians to better determine treatment options for severe refractory alopecia areata.

It has been shown recently that blocking the common signalling pathways downstream of cytokine receptors, particularly Janus kinase (JAK), may reverse AA in mice (5). Based on this information, JAK inhibitors have been proposed as a novel promising therapeutic option for AA. In several previous studies, tofacitinib, one of the JAK inhibitors, has been shown to have promising results in managing severe AA (6–8). However, lack of evidence, safety uncertainties, and high associated costs compared with other conventional methods have limited its application in clinical practice. Thus far, to the best of our knowledge, there is no report comparing the treatment outcomes between tofacitinib and other conventional therapies. Hence, this study retrospectively compared the efficacy and tolerability of oral tofacitinib with conventional oral treatment and topical immunotherapy in treating refractory AT/AU.

## METHODS

This study was approved by the Institutional Review Board of Seoul National University Bundang Hospital (B-1708/415-204) and SMG-SNU Boramae Medical Center (10-2017-24). Electronic medical records and clinical photographs were reviewed for all patients with AT or AU who were treated in a tertiary or a secondary hospital with oral tofacitinib, conventional oral treatment (steroid ± cyclosporine), or diphenylcyclopropenone (DPCP) immunotherapy during a period between August 2005 and August 2017. Inclusion criteria were: (i) ≥18 years old; (ii) AT (>80% scalp hair loss) and AU (>80% scalp hair loss with total body hair loss); (iii) ≥1 year of current episode duration; (iv) previous treatment failure of at least one conventional oral treatment or immunotherapy; and (v) at least 6-month follow-up period. Clinical

and demographic information, including age, sex, age of disease onset, and duration of current episode of disease, were retrieved from the patients' medical records. Disease severity was assessed with the Severity of Alopecia Tool (SALT) (9). SALT scores were measured using patients' clinical photographs for those in the conventional oral treatment and DPCP groups; but for those in the tofacitinib group, the SALT scores recorded in the electronic chart were used.

Treatment response was evaluated by calculating the percentage regrowth of scalp hair ( $\frac{\text{SALT at baseline} - \text{SALT at follow-up}}{\text{SALT at baseline}} \times 100$ ). SALT<sub>50</sub> was defined as 50% regrowth. The presence or absence of adverse reactions, types of adverse reactions, and permanent discontinuation of drugs due to adverse reactions, were evaluated by reviewing patients' medical records.

#### Statistical analysis

Kruskal–Wallis test and  $\chi^2$  test were used to compare continuous and non-continuous variables among the 3 groups, respectively. If there was a significant difference, pair-wise comparisons using Mann-Whitney *U* test or  $\chi^2$  test with *post hoc* Bonferroni correction were performed. All analyses were performed using SPSS for Windows (Version 20, IBM, Chicago, IL, USA). *p*-values less than 0.05 were considered statistically significant.

## RESULTS

### Baseline characteristics

Of 450 patients diagnosed as having AT or AU, a total of 74 patients (18 tofacitinib, 26 conventional oral treatment, 30 DPCP) were included in this study. The other 376 patients were excluded because they did not meet the inclusion criteria: treatment with other modalities ( $n=11$ ), age under 18 years ( $n=43$ ), initial SALT score  $\leq 80$  ( $n=187$ ),  $< 1$  year of current episode duration ( $n=57$ ), no previous history of treatment failure ( $n=32$ ), or short follow-up duration ( $n=46$ ). A portion of patients in the tofacitinib group had been included in our previous study investigating the efficacy and tolerability

of oral tofacitinib for Korean patients with moderate to severe AA (7). The demographic features of patients are summarized in **Table I**. The median age at onset of first episode was 18.5 years in the tofacitinib group, 23.5 years in the conventional oral treatment group, and 25 years in the DPCP group. The median duration of disease was 8 years in the tofacitinib group, 5 years in the conventional oral treatment and DPCP groups. The median initial SALT score was 100, 98.5, and 98.1 in the tofacitinib, conventional oral treatment, and DPCP groups, respectively. The median number of previously failed treatments for the current episode was 2, 1, and 1 in the tofacitinib, conventional oral treatment, and DPCP groups, respectively. Previous treatment methods are also summarized in Table I. Although most of the patients were switched to a different treatment regimen from the previous one, some patients who had long current episode duration were kept in the same treatment regimen with dose adjustment. Baseline characteristics in the tofacitinib group were not significantly different from the other 2 groups except for the number of previously failed treatments.

In the tofacitinib group, all patients received baseline laboratory tests, including complete blood cell count with differential, admission panel (aminotransferase, aspartate aminotransferase, gamma glutamyltransferase, total bilirubin, urea nitrogen, creatinine, calcium, phosphorus, total protein, albumin), lipid panel, interferon- $\gamma$  release assay for *Mycobacterium tuberculosis*, and serology (HIV, hepatitis virus, syphilis). Three patients in the tofacitinib group had latent tuberculosis and received isoniazid 300 mg daily throughout the entire treatment period. Oral tofacitinib was prescribed as a monotherapy. Tofacitinib 5 mg was given twice daily to all patients; in the 4 patients without any sign of response, the dose was increased (to 5 mg 3 times a day after 2 months in

**Table I. Baseline characteristics of patients with alopecia totalis and alopecia universalis in each group ( $n=74$ )**

	Tofacitinib $n=18$	Conventional oral treatment $n=26$	DPCP $n=30$	<i>p</i> -value
Age, years, median (range)	28 (19–51)	30.5 (18–63)	33 (18–51)	0.677
Sex				0.258
Male	7	14	11	
Female	11	12	19	
Age at onset of first episode, years, median (range)	18.5 (3–49)	23.5 (2–62)	25 (6–49)	0.444
Duration of disease, years, median (range)	8 (2–17)	5 (1–21)	5 (1–25)	0.469
Duration of current episode, <i>n</i> (%)				0.336
1–5 years	10 (55.6)	18 (69.2)	15 (50)	
> 5 years	8 (44.4)	8 (30.8)	15 (50)	
Subtype, <i>n</i> (%)				0.651
Alopecia totalis	8 (44.4)	8 (30.8)	11 (36.7)	
Alopecia universalis	10 (55.6)	18 (69.2)	19 (63.3)	
SALT at initiating therapy, median (range)	100 (83–100)	98.5 (80–100)	98.1 (80–100)	0.112
Previous treatment history for current episode*				
Number of previously failed treatments, median (range)	2 (1–3)	1 (1–2)	1 (1–2)	0.017
Treatment method (number of patients)	Oral steroid (17) Oral steroid + cyclosporine (7) DPCP (8)	Oral steroid (15) Oral steroid + cyclosporine (5) DPCP (11)	Oral steroid (24) Oral steroid + cyclosporine (18) DPCP (3)	NA

\*Only conventional oral treatment or immunotherapy was included. DPCP: diphenylcyclopropenone; SALT: Severity of Alopecia Tool.

one patient, to 5 mg 3 times a day after 4 months in 2 patients, and to 5 mg 3 times a day after 2 months, then increased again to 10 mg twice daily after 4 months in one patient). The median total tofacitinib dose was 1,680 mg (range 1,680–2,800 mg).

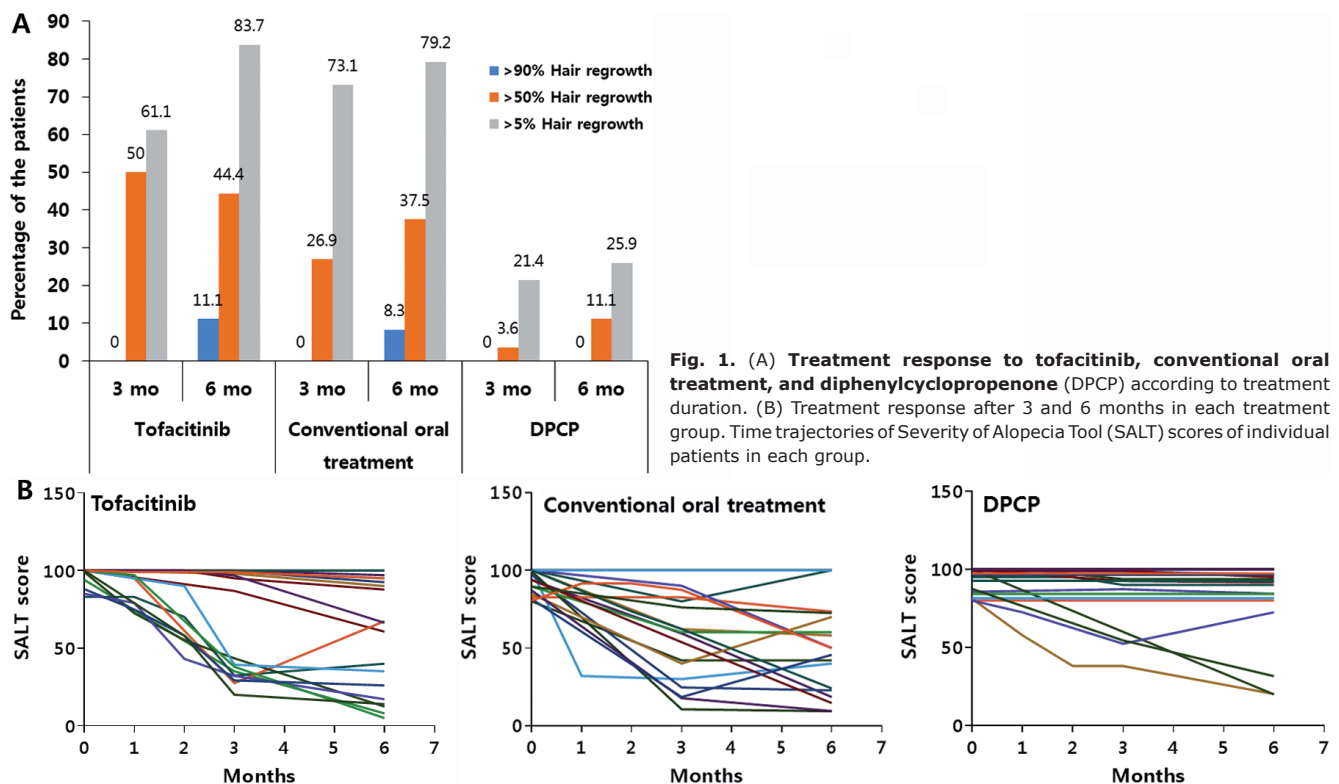
In the conventional oral treatment group, all patients received baseline laboratory tests, including complete blood cell count with differential, admission panel, lipid panel, and hepatitis virus serology test, before initiating treatment. In most cases, a total of 24 mg methylprednisolone was given per day for the first week; then reduced by 4 mg/day for each subsequent week, until the dose was 4 mg/day, which was maintained for 2 months. The dose was then reduced to 2 mg/day, which was maintained for 3 months. In cases without sufficient response, the initial dosing schedule was re-tried. The median total dose of methylprednisolone was 1,120 mg (840–1,330 g). In 22 patients, oral cyclosporine was combined with methylprednisolone. In 19 of these 22 patients, cyclosporine was combined from the beginning of the treatment, while in the remaining 3 patients it was added 3 months after the start of treatment. Cyclosporine was given 150–300 mg per day and the median total cyclosporine dose was 33,600 mg (25,200–33,600 g).

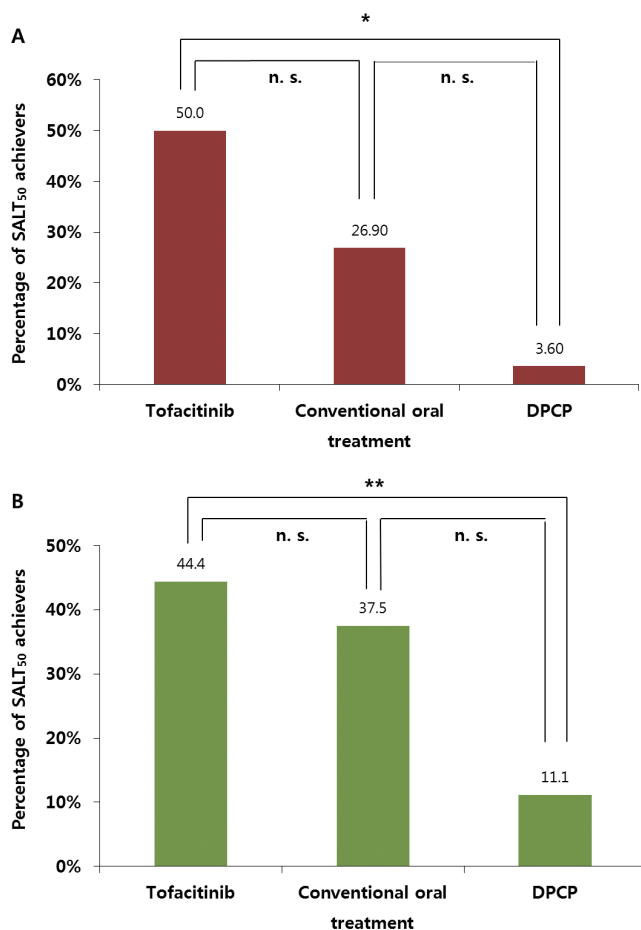
In the DPCP group, the initial concentration of DPCP used post-sensitization ranged from 0.0001 to 1%, with a median of 0.001%. The highest concentration of DPCP used ranged from 0.001 to 1%, with a median of 0.1%.

### Treatment response

Treatment response in each group according to the treatment duration is shown in **Fig. 1**. In general, treatment response increased over time in all groups. After 6 months, patients in the tofacitinib group showed the highest treatment response (Fig. 1A). SALT<sub>50</sub> achievers in the tofacitinib group showed a sharper decline in the SALT score, showing more rapid hair regrowth than the other groups (Fig. 1B).

After 3 months, 9 patients (50%) in the tofacitinib group, 7 patients (26.9%) in the conventional oral treatment group, and one patient (3.6%) in the DPCP group achieved SALT<sub>50</sub> (**Fig. 2A**). There was a significant difference in the proportion of patients who achieved SALT<sub>50</sub> among the 3 groups ( $p=0.001$ ). It was significantly higher in the tofacitinib group than in the DPCP group (corrected  $p=0.000$ ). After 6 months, 8 patients (44.4%) in the tofacitinib group, 9 patients (37.5%) in the conventional oral treatment group, and 3 patients (11.1%) in the DPCP group achieved SALT<sub>50</sub> (**Fig. 2B**). The proportion of patients who achieved SALT<sub>50</sub> was significantly different among the 3 groups ( $p=0.028$ ). It was significantly higher in the tofacitinib group than in the DPCP group (corrected  $p=0.048$ ). However, there was no significant difference in SALT<sub>50</sub> rate between the tofacitinib and conventional oral treatment groups at 3 and 6 months. The median value of SALT score change was 34.6 (range 0–80), 34.7 (0–89.2) and 0 (0–53.0)





**Fig. 2.** Ratio of Severity of Alopecia Tool (SALT<sub>50</sub> defined as 50% regrowth) SALT<sub>50</sub> achievers in each group (A) after 3 months and (B) 6 months. \*p < 0.01, \*\*p < 0.05. DPCP: diphenylcyclopropenone.

after 3 months; 36.5 (0–91.5), 39.9 (0–91.6), 0 (0–80) after 6 months in the tofacitinib, conventional oral treatment, and DPCP groups, respectively. Tofacitinib and conventional oral treatment groups were significantly different with the DPCP group after 3 and 6 months (all corrected p=0.000).

*Adverse reactions*

Adverse reactions in each group are described in **Table II**. In the tofacitinib group, 6 (33.3%) patients experienced adverse reactions. Most of the adverse reactions were mild or transient, and no-one permanently discontinued treatment due to drug reactions. Meanwhile, 19 patients (73.1%) in the conventional oral treatment group experienced adverse reactions; among them, 6 patients (23.1%) permanently discontinued treatment. The most common adverse reactions were abdominal discomfort and acneiform eruption. In the DPCP group, 10 patients (33.3%) experienced adverse reactions; among them, 3 patients (10.0%) stopped treatment due to severe eczema and urticaria. The proportions of patients who experienced adverse drug reactions were significantly different between the 3 groups (p=0.018), and the proportion in the tofacitinib group was significantly lower than that in the conventional oral treatment group (corrected p=0.042).

**DISCUSSION**

There have been many proposed treatment modalities for AA; however, none are Food and Drug Administration (FDA)-approved and fully satisfactory. Since its efficacy was first demonstrated in 1952, systemic oral steroid has remained the most widely used method to treat extensive AA (10). Steroid treatment reduces inflammation around the hair follicle, allowing it to return to its normal growth cycle. However, despite its popularity, there is limited evidence to support the efficacy of oral steroids (11–16). The greatest barrier

**Table II.** Adverse reactions (ARs) observed in each group

	Tofacitinib	Conventional oral treatment	DPCP
Patients who experienced ARs, n (%)	6 (33.3)*	19 (73.1)	10 (33.3)
Patients who discontinued treatment due to relevant drug ARs, n (%)	0	6 (23.1%) <sup>a</sup>	3 (10.0%) <sup>b</sup>
Symptoms of ARs (n)	Skin rash (1) Urticaria (1) Palmoplantar desquamation (1) Nasopharyngitis (1) Wart (1) Anaemia (1) Abdominal discomfort (1)	Abdominal discomfort (9) Acneiform eruption (9) Facial swelling (3) Weight gain (3) Hypertension (2) Hyperglycaemia (1) Hypercholesterolemia (1) Lymphadenopathy (1) Arthralgia (1) Menstrual irregularity (1) Gingival hypertrophy (1) Liver function abnormality (1)	Severe eczema (6) Severe itching (3) Urticaria with angioedema (1)

\*Corrected p < 0.05 compared with conventional oral treatment.

<sup>a</sup>The main causes of discontinuation of conventional oral treatment (number of patients): abdominal discomfort (3), acneiform eruption (1), hypertension (1), and gingival hypertrophy (1). <sup>b</sup>The main causes of discontinuation of DPCP (number of patients): severe eczema (2) and urticaria with angioedema (1).

DPCP: diphenylcyclopropenone.



to using steroids is the associated adverse reactions, especially with prolonged treatment. Furthermore, no standard treatment dose and schedule for the use of steroids have been established. Cyclosporine is one of the options for treating chronic and severe AA. However, most previous studies have investigated the combined therapeutic effect of cyclosporine and systemic steroids rather than cyclosporine alone (17–21). Adverse reactions include increased blood pressure, liver toxicity, and acute renal failure. Clinical use of cyclosporine in combination with steroids is advised only in refractory cases, given the severity of systemic adverse effects and lack of evidence (4). Also, DPCP immunotherapy is an option for treating recalcitrant AT/AU (11). The exact therapeutic mechanism of DPCP has not yet been elucidated; however, antigenic competition and decreased production of anti-hair-follicle antibodies are thought to play important roles (22). The success rate of DPCP as a treatment of AT/AU ranges from 22% to 79% (11).

Recent experimental research has elucidated that the natural killer group, 2D-bearing CD8<sup>+</sup> cytotoxic T lymphocytes, is the key player in the pathogenesis of AA; it has been shown, in a mouse model, to cause upregulation of interleukin-15, produce interferon- $\gamma$ , and attack the hair follicle (5). JAK inhibitors, as downstream regulators of interleukin-15 and interferon- $\gamma$ , have been demonstrated to reverse AA. Recently, an open-label clinical trial (23) and retrospective observational studies (6–8) with tofacitinib have revealed promising results for treating AA.

This study included patients with AT/AU with a duration of  $\geq 1$  year of the current episode and at least one previous failed attempt of conventional oral treatment or immunotherapy, in order to collect refractory cases and to exclude those with acute diffuse and total alopecia, which can resolve spontaneously (24). There was no significant difference in the baseline characteristics between the 3 groups (Table I).

Tofacitinib was significantly more efficacious than DPCP after 3 and 6 months, whereas it did not reveal a significantly higher efficacy than conventional oral treatment. Nevertheless, considering that most patients in the tofacitinib group experienced multiple prior treatment failures to both conventional oral treatment and DPCP (Table I), tofacitinib appears to be a promising option for highly refractory cases. In general, the longer the treatment duration, the better response patients showed in all treatment groups (Fig. 1A). Interestingly, tofacitinib demonstrated a unique response pattern (Fig. 1B). Patients who achieved SALT<sub>50</sub> showed a sharp decline in the SALT score earlier in the treatment course. In contrast, most of those who failed to achieve SALT<sub>50</sub> showed a plateau or gradual decrease in the SALT score. Therefore, we believe that a treatment response during the first 3 months might be an important indicator for

further treatment response to tofacitinib. One patient who showed an initial SALT<sub>50</sub> response within the first 3 months deteriorated after 6 months, but recovered again after 2 months with a dose increment of 10 mg twice a day.

Tofacitinib showed better tolerability compared with the other treatment groups (Table II). The proportion of patients who experienced adverse drug reactions was significantly lower (33.3%) in the tofacitinib group than in the conventional oral treatment group (73.1%). The proportion of adverse reactions in the conventional oral treatment group might be overestimated because the majority of patients were treated with steroid plus cyclosporine. Both drugs can cause adverse reactions and a combination of these might increase the frequency of adverse reactions compared with monotherapy with each agent. No patients in the tofacitinib group permanently discontinued the medication due to adverse reactions, while 6 patients (23.1%) in the conventional oral treatment group and 3 patients (10%) in the DPCP group did. Although there were no serious adverse reactions in the tofacitinib group, this only reflects the results from a 6-month follow-up period. In a previous study with a median follow-up of 12 months, approximately 38.9% of the patients experienced infections during treatment with tofacitinib (6). Because of the shorter follow-up period in the present study, the risk of infection might be underestimated. JAK inhibitors also may modulate anti-tumour inflammatory responses and increase the risk of malignancy. However, recent comprehensive pooled analysis of multiple clinical trials revealed that a standardized incidence rate of all malignancies of tofacitinib-treated rheumatoid arthritis patients was within the expected range of the general population with rheumatoid arthritis (25). Close monitoring and age-adequate cancer screening may be beneficial for those receiving tofacitinib for an extended period.

#### Study limitations

The present study has some limitations. First, it is a retrospective study with a small number of patients. Secondly, it is not a head-to-head comparison of treatment modalities. However, considering that AT/AU is a relatively rare disease and that it took more than 10 years to collect data from this number of patients, these results are noteworthy. Thirdly, we did not include a placebo group for proper control. However, since the spontaneous resolution rate of moderate-to-severe AA is low, such possibility in AT/AU is expected to be extremely low (26). Fourthly, the current study had a relatively short observational period. Although the majority of DPCP responders experienced their first regrowth within the first 6 months of treatment (27), DPCP is known to require extended treatment to show sufficient effects (28–31). Certainly, large scale long-term prospective head-to-head

comparative randomized controlled trials are required to confirm the results of the current study.

### Conclusion

Oral tofacitinib was more efficacious than DPCP immunotherapy and more tolerable than conventional oral treatment, at least during the first 6-month treatment period. To the best of our knowledge, this is the first investigation that comparatively analysed the treatment outcomes of tofacitinib with other conventional therapies in patients with refractory AT and AU. The present study will help clinicians to better determine their treatment options for severe refractory AA and will guide further clinical trials investigating the efficacy and safety of JAK inhibitors for AA.

*The authors have no conflicts of interest to declare.*

### REFERENCES

- Rafique R, Hunt N. Experiences and coping behaviours of adolescents in Pakistan with alopecia areata: an interpretative phenomenological analysis. *Int J Qual Stud Health Well-being* 2015; 10:26039. 10.3402/qhw.v3410.26039. eCollection 2015.
- Hunt N, McHale S. The psychological impact of alopecia. *BMJ* 2005; 331: 951–953.
- McGarvey EL, Baum LD, Pinkerton RC, Rogers LM. Psychological sequelae and alopecia among women with cancer. *Cancer Pract* 2001; 9: 283–289.
- Lee S, Lee WS. Management of alopecia areata: updates and algorithmic approach. *J Dermatol* 2017; 44: 1199–1211.
- Xing L, Dai Z, Jabbari A, Cerise JE, Higgins CA, Gong W, et al. Alopecia areata is driven by cytotoxic T lymphocytes and is reversed by JAK inhibition. *Nat Med* 2014; 20: 1043–1049.
- Liu LY, Craiglow BG, Dai F, King BA. Tofacitinib for the treatment of severe alopecia areata and variants: a study of 90 patients. *J Am Acad Dermatol* 2017; 76: 22–28.
- Park HS, Kim MW, Lee JS, Yoon HS, Huh CH, Kwon O, et al. Oral tofacitinib monotherapy in Korean patients with refractory moderate-to-severe alopecia areata: a case series. *J Am Acad Dermatol* 2017; 77: 978–980.
- Ibrahim O, Bayart CB, Hogan S, Piliang M, Bergfeld WF. Treatment of alopecia areata with tofacitinib. *JAMA Dermatol* 2017; 153: 600–602.
- Olsen E, Hordinsky M, McDonald-Hull S, Price V, Roberts J, Shapiro J, et al. Alopecia areata investigational assessment guidelines. National Alopecia Areata Foundation. *J Am Acad Dermatol* 1999; 40: 242–246.
- Dillaha CJ, Rothman S. Treatment of alopecia areata totalis and universalis with cortisone acetate. *J Invest Dermatol* 1952; 18: 5–6.
- Kassira S, Korta DZ, Chapman LW, Dann F. Review of treatment for alopecia totalis and alopecia universalis. *Int J Dermatol* 2017; 56: 801–810.
- Bin Saif GA. Oral mega pulse methylprednisolone in alopecia universalis. *Saudi Med J* 2006; 27: 717–720.
- Bin Saif GA, Al-Khawajah MM, Al-Otaibi HM, Al-Roujaye AS, Alzolibani AA, Kalantan HA, et al. Efficacy and safety of oral mega pulse methylprednisolone for severe therapy resistant alopecia areata. *Saudi Med J* 2012; 33: 284–291.
- Tsai YM, Chen W, Hsu ML, Lin TK. High-dose steroid pulse therapy for the treatment of severe alopecia areata. *J Formos Med Assoc* 2002; 101: 223–226.
- Lalosevic J, Gajic-Veljic M, Bonaci-Nikolic B, Nikolic M. Combined oral pulse and topical corticosteroid therapy for severe alopecia areata in children: a long-term follow-up study. *Dermatol Ther* 2015; 28: 309–317.
- Khaitan BK, Mittal R, Verma KK. Extensive alopecia areata treated with betamethasone oral mini-pulse therapy: an open uncontrolled study. *Indian J Dermatol Venereol Leprol* 2004; 70: 350–353.
- Shapiro J, Lui H, Tron V, Ho V. Systemic cyclosporine and low-dose prednisone in the treatment of chronic severe alopecia areata: a clinical and immunopathologic evaluation. *J Am Acad Dermatol* 1997; 36: 114–117.
- Kim BJ, Min SU, Park KY, Choi JW, Park SW, Youn SW, et al. Combination therapy of cyclosporine and methylprednisolone on severe alopecia areata. *J Dermatolog Treat* 2008; 19: 216–220.
- Shaheedi-Dadras M, Karami A, Mollaei F, Moravvej H, Malekzad F. The effect of methylprednisolone pulse-therapy plus oral cyclosporine in the treatment of alopecia totalis and universalis. *Arch Iran Med* 2008; 11: 90–93.
- Lee D, Hong SK, Park SW, Hur DY, Shon JH, Shin JG, et al. Serum levels of IL-18 and sIL-2R in patients with alopecia areata receiving combined therapy with oral cyclosporine and steroids. *Exp Dermatol* 2010; 19: 145–147.
- Yeo IK, Ko EJ, No YA, Lim ES, Park KY, Li K, et al. Comparison of high-dose corticosteroid pulse therapy and combination therapy using oral cyclosporine with low-dose corticosteroid in severe alopecia areata. *Ann Dermatol* 2015; 27: 676–681.
- Tobin DJ, Gardner SH, Lindsey NJ, Hoffmann R, Happle R, Freyschmidt-Paul P. Diphencyprone immunotherapy alters anti-hair follicle antibody status in patients with alopecia areata. *Eur J Dermatol* 2002; 12: 327–334.
- Kennedy Crispin M, Ko JM, Craiglow BG, Li S, Shankar G, Urban JR, et al. Safety and efficacy of the JAK inhibitor tofacitinib citrate in patients with alopecia areata. *JCI Insight* 2016; 1: e89776.
- Lew BL, Shin MK, Sim WY. Acute diffuse and total alopecia: a new subtype of alopecia areata with a favorable prognosis. *J Am Acad Dermatol* 2009; 60: 85–93.
- Curtis JR, Lee EB, Kaplan IV, Kwok K, Geier J, Benda B, et al. Tofacitinib, an oral Janus kinase inhibitor: analysis of malignancies across the rheumatoid arthritis clinical development programme. *Ann Rheum Dis* 2016; 75: 831–841.
- Strober BE, Menon K, McMichael A, Hordinsky M, Krueger G, Panko J, et al. Alefacept for severe alopecia areata: a randomized, double-blind, placebo-controlled study. *Arch Dermatol* 2009; 145: 1262–1266.
- Chiang KS, Mesinkovska NA, Piliang MP, Bergfeld WF. Clinical efficacy of diphenylcyclopropenone in alopecia areata: retrospective data analysis of 50 patients. *J Invest Dermatol Symp Proc* 2015; 17: 50–55.
- Ohlmeier MC, Traupe H, Luger TA, Bohm M. Topical immunotherapy with diphenylcyclopropenone of patients with alopecia areata – a large retrospective study on 142 patients with a self-controlled design. *J Eur Acad Dermatol Venereol* 2012; 26: 503–507.
- Sotiriadis D, Patsatsi A, Lazaridou E, Kastanis A, Vakirlis E, Chrysomallis F. Topical immunotherapy with diphenylcyclopropenone in the treatment of chronic extensive alopecia areata. *Clin Exp Dermatol* 2007; 32: 48–51.
- Wiseman MC, Shapiro J, MacDonald N, Lui H. Predictive model for immunotherapy of alopecia areata with diphencyprone. *Arch Dermatol* 2001; 137: 1063–1068.
- Avgerinou G, Gregoriou S, Rigopoulos D, Stratigos A, Kalogeromitros D, Katsambas A. Alopecia areata: topical immunotherapy treatment with diphencyprone. *J Eur Acad Dermatol Venereol* 2008; 22: 320–323.