

Disseminated Erythematous Papules and Pustules: A Quiz

Yasuyuki FUJITA¹, Chihiro SHIYA¹, Yuka INAMURA-TAKASHIMA¹, Toshifumi NOMURA¹, Akihiko SHIBAKI² and Hiroshi SHIMIZU¹

¹Department of Dermatology, Hokkaido University Graduate School of Medicine, N15 W7, Kita-ku, Sapporo 060-8638, and ²Shibaki Dermatology Clinic, Sapporo, Japan. E-mail: yfujita@med.hokudai.ac.jp

A 10-month-old Japanese girl presented with asymptomatic papules on the whole body that had appeared 3 weeks prior to referral. She had been treated with topical corticosteroids and oral antibiotics at a previous clinic, with poor response. Physical examination revealed light-red papules of up to 8 mm diameter scattered over her extremities and head (Fig. 1A, B). Pustules with partly follicular distribution were also observed on her forehead and anterior scalp (Fig. 1B). History-taking revealed that she had received the Bacillus Calmette–Guérin (BCG) vaccine 2 months prior to onset of symptoms. She had no

systemic symptoms, such as fever, cough or hepatosplenomegaly, nor did she have episodes associated with immunodeficiency. A skin biopsy from a papule on her forearm revealed interstitial and perifollicular lymphohistiocytic infiltration (Fig. 1C). Multi-nucleolar histiocytes were also observed (Fig. 1D). These cells stained positively for CD68 and were negative for S-100 and CD1a. No bacillary organisms were detected from the skin specimen by Ziehl-Neelsen staining.

What is your diagnosis? See the next page for answer.

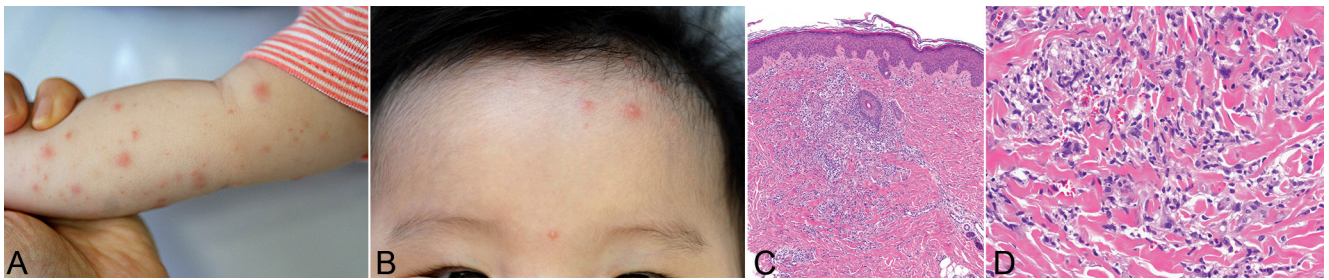


Fig. 1. (A) Infiltrated light-red papules disseminated on the upper arms. (B) Follicular papules on the forehead and anterior scalp. (C) Histopathological revealing interstitial and perifollicular lymphohistiocytic infiltration (original magnification $\times 40$). (D) Interstitial histiocytic infiltration with multi-nucleolar cells (original magnification $\times 200$). C and D: Haematoxylin and eosin staining.

ANSWERS TO QUIZ

**Disseminated Erythematous Papules and Pustules:
A Commentary**

Acta Derm Venereol 2019; 99: 123–124.

Diagnosis: Papular tuberculid following BCG vaccination

The patient had received the BCG vaccine 2 months prior to onset of symptoms. Furthermore, all the papules and pustules improved spontaneously over a period of 4 weeks, leaving slight pigmentation, and no recurrence was found at 12-month follow-up. A final diagnosis of papular tuberculid was made from the clinicopathological findings.

BCG is a live, attenuated strain of *Mycobacterium bovis* developed by Calmette and Guérin for vaccination against tuberculosis and other mycobacterial infections. In Japan, all infants have been obligated to receive BCG vaccine since 2005, and various adverse effects, such as BCG lymphadenitis and tuberculids, have been observed (1, 2).

Papular tuberculid, a rare adverse effect of BCG vaccination, was first described by De Bruyne in 1953 (3). It is considered to be a hypersensitivity reaction to *M. bovis*-like lichen scrofulosorum and papulonecrotic tuberculid; scattered distribution and papular morphology characterizes this clinical entity. Approximately 20 cases of papular tuberculid have been described in the literature (2–4), but this is likely to be an underestimate of the actual number of cases because of the disorder's latent, asymptomatic and self-limited clinical course. Perifollicular infiltration of histiocytes with Langhans giant cells is characteristic of papular tuberculid, and the folliculotropism can lead to folliculitis-like pustules, as seen in the forehead lesion of the present case.

Papular tuberculid associated with BCG vaccination usually resolves within a few months after onset. Differential diagnoses include cutaneous BCG dissemination, granuloma annulare, varicella, pityriasis lichenoides et varioliformis acuta, superficial folliculitis and Langerhans cell histiocytosis. Skin biopsy with Ziehl-Neelsen staining and immunohistochemistry is useful for ruling out these conditions, especially if the skin lesions persist for months. Of note, granuloma annulare has been reported to clinically mimic papular tuberculid, which is characterized by palisading granuloma and necrobiosis (5, 6). However, rather rapid improvement does not fit the typical course of granuloma annulare in these cases, and they should be considered as a variant of papular tuberculid.

In conclusion, dermatologists and paediatricians should determine the history of BCG vaccination when examining infants with asymptomatic papulosis.

REFERENCES

1. Bellet JS, Prose NS. Skin complications of Bacillus Calmette-Guérin immunization. *Curr Opin Infect Dis* 2005; 18: 97–100.
2. Attia EAS. Update on cutaneous complications of Bacille Calmette-Guérin immunization. *J Egypt Women Dermatol Soc* 2012; 9: 72–76.
3. De Bruyne JI, Van Creveld S, Prakken JR, Stoppelman MR. Papular tuberculids after BCG vaccination. *Acta Derm Venereol* 1953; 33: 385–390.
4. Muto J, Kuroda K, Tajima S. Papular tuberculides post-BCG vaccination: case report and review of the literature in Japan. *Clin Exp Dermatol* 2006; 31: 611–612.
5. Nagase K, Koba S, Okawa T, Inoue T, Misago N, Narisawa Y. Generalized granuloma annulare following BCG vaccination, mimicking papular tuberculid. *Eur J Dermatol* 2011; 21: 1001–1002.
6. Yoon JY, Lee NR, Choi EH. Generalized granuloma annulare after bacillus Calmette-Guérin vaccination, clinically resembling papular tuberculid. *J Dermatol* 2014; 41: 109–111.