

Overexpression of Androgen, Oestrogen and Progesterone Receptors in Skin Lesions of Becker's Naevus

Ping SHENG[#], Yun-Long CHENG[#], Chuan-Chuan CAI[#], Ya-Yun WU, Ge SHI, Ying ZHOU and Yi-Ming FAN

Department of Dermatology, Affiliated Hospital of Guangdong Medical University, Zhanjiang, Guangdong, China

[#]These authors contributed equally to this study.

Becker's naevus is androgen-dependent. The aim of this study was to investigate whether oestrogen and progesterone receptors are involved in this disorder. Immunohistochemistry showed that epidermal expression of androgen receptors, oestrogen receptors (α , β) and progesterone receptors was higher in skin lesions of Becker's naevus than in perilesional and control skin. Androgen receptor overexpression was observed in pilosebaceous glands, while oestrogen and progesterone receptor overexpression was seen in hair follicles, but not in sebaceous glands in skin lesions compared with perilesional skin. Reverse transcription PCR and Western blot revealed that levels of androgen, oestrogen and progesterone receptors were generally upregulated in skin lesions compared with perilesional and control skin, and their expression was usually higher in perilesional than in control skin. These results suggest that simultaneous overexpression of androgen, oestrogen and progesterone receptors might be implicated in the pathogenesis of Becker's naevus.

Key words: Becker's naevus; androgen; oestrogen; progesterone; receptor.

Accept Jun 5, 2018; Epub ahead of print Jun 8, 2018

Acta Derm Venereol 2018; 98: 867–872.

Corr: Yi-Ming Fan, Department of Dermatology, Affiliated Hospital of Guangdong Medical University, No. 57, Renmin Avenue, Xiashan district, Zhanjiang, Guangdong, 524001, China. E-mail: ymfan1963@163.com

Becker's naevus (BN) is a fairly common dermatosis that generally becomes apparent in adolescence. It typically presents as a brown patch on the shoulder girdle and upper chest, often concomitant with hypertrichosis. The main pathological features of BN include acanthosis, basal hyperpigmentation, and rete ridge fusion and elongation (1, 2). The aetiopathogenesis of BN is unclear. BN may represent a paradigmatic trait, but Cai et al. (3) proposed that mutations in ACTB might interfere with the development of hair follicles and pilar muscles development through enhanced Hedgehog signalling.

Sex hormones play important roles in physiological and pathological processes in human skin. Androgen, oestrogen and progesterone mediate the biological actions through their receptors. Androgen receptor (AR), oestrogen receptor (ER) and progesterone receptor (PR) belong to class I members of nuclear receptor superfamily

SIGNIFICANCE

Becker's naevus is an androgen-dependent hyperpigmentation dermatosis occurring mostly in male teenagers. This study reveals that levels of androgen, oestrogen and progesterone receptors are remarkably higher in skin lesions of Becker's naevus compared with perilesional and control skin, using immunohistochemistry, reverse transcription PCR and Western blot. The abnormal activities of these sex hormone receptors are also present in perilesional normal-appearing skin. These results suggest that simultaneous overexpression of androgen, oestrogen and progesterone receptors might be implicated in the pathogenesis of Becker's naevus.

ly and serve as ligand-inducible transcription factors (4, 5). Both testosterone and dihydrotestosterone bind to AR, with a potent biological activity of dihydrotestosterone (4). ER comprises 2 isoforms, ER α and ER β , coded by ESR1 and ESR2 genes, respectively (5); 17 β -oestradiol has a similar affinity for ER α and ER β (6). PR includes truncated PRA and full-length PRB, produced by the same PR gene (7). Androgen can influence hair growth, sebaceous gland growth and differentiation, epidermal barrier homeostasis and wound healing, while oestrogen is involved in skin ageing and cancer, pigmentation, hair growth and sebum production (8). In contrast, less is known about the impact of progesterone on skin and its appendages. Progesterone stimulates keratinocyte and sebum secretion, but inhibits pigment production and collagen degradation (9, 10).

It is generally accepted that BN is an androgen-dependent dermatosis (11, 12). Although the true prevalence of BN in females is undetermined, BN has been shown to be more common in male teenagers with higher serum levels of androgen (11). Several reports have found AR overexpression in BN lesions (11–15). Oral spironolactone (50 mg/day) enlarged the hypoplastic breast in BN syndrome (16), while topical 4% flutamide solution alleviated hyperpigmentation in BN (17). These results support the role of androgen in the pathogenesis of BN. However, to date, ER and PR expression in BN is unknown. This study investigated the expression of AR, ER α , ER β and PR in BN lesional skin using immunohistochemistry, reverse transcription PCR (RT-PCR) and Western blot (WB).

METHODS

Specimens

Between January 2014 and June 2015, lesional and perilesional normal-appearing skin was collected from 17 male and 3 female patients with BN (Table S1¹). The mean diagnostic age was 19.05 ± 6.07 (range 12–38) years and mean \pm SD duration 8.51 ± 7.47 (range 0.1–32) years. BN was diagnosed based on the clinical and pathological features (1, 2). Normal skin samples were obtained from 8 healthy males and 2 females who underwent aesthetic surgery, with a mean age of 20.40 ± 4.86 (range 13–30) years. Sex and age were comparable between the 2 groups ($\chi^2=0.12$, $p=0.729$; $t=0.611$, $p=0.546$). The biopsied samples were divided into 2 halves, of which one was fixed with 10% neutral buffered formalin and embedded in paraffin for immunohistochemistry, and the other was frozen in liquid nitrogen for isolation of RNA or DNA. This study was approved by the Institutional Review Board of our hospital (number PJ2013121) and informed consent was obtained from all participants.

Immunohistochemistry

The paraffin-embedded sections were dewaxed, hydrated, autoclaved in 0.01 M citrate buffer (pH 6.0) for 2 min, and incubated with 3% hydrogen peroxide for 10 min to quench the endogenous peroxidase activity. Subsequently, the sections were incubated with monoclonal rabbit anti-human AR (clone D6F11; cat. 5153; 1:500 dilution; Cell Signaling Technology, Danvers, MA, USA), rabbit anti-human ER α (clone E115; cat. ab32063; 1:100 dilution; Abcam, Cambridge, MA, USA), mouse anti-human ER β (clone 14C8; cat. ab288; 1:200; Abcam), or rabbit anti-human PR (clone C89F7; cat. 3153; 1:100; Cell Signaling Technology) overnight at 4°C, followed by treating with ready-to-use Elivision Plus kit (Maixin Biotechnology, Fuzhou, China) for 1 h at room temperature. The sections were stained with diaminobenzidine kit (Maixin Biotechnology) and then counterstained with haematoxylin. Breast cancer specimens served as positive controls, while omitting the primary antibody as negative controls.

The micrographs were captured by Olympus DP71 digital camera (Tokyo, Japan) and analysed by 2 independent observers using Image-Pro[®] Plus v6.0 (Media Cybernetics Inc., Silver Spring, MD, USA). Five fields were chosen randomly from each section at $\times 200$ magnification. AR, ER α , ER β and PR staining was mainly nuclear and sometimes cytoplasmic. Nuclear staining keratinocytes were counted in the interfollicular epidermis. In addition, because the pilosebaceous units were seen only in 2 normal specimens, nuclear positive cells in the hair bulb, outer root sheath, and basal and differentiated sebocytes of all pilosebaceous glands in each section were calculated in lesional and perilesional skin.

The Allred score, based on proportion of positive cells and staining intensity, was adopted to evaluate the immunoreactivity of AR, ER α , ER β and PR. Briefly, the proportion of nuclear staining cells was assigned as 0 (no staining), 1 (<1%), 2 (1–10%), 3 (11–33%), 4 (34–66%) and 5 (>67%), while the staining intensity was scored as 0 (no staining), 1 (weak staining), 2 (moderate staining) and 3 (strong staining). The 2 scores were added together and then categorized into 4 classes: negative (0–2), 1+ (3–4), 2+ (5–6) and 3+ (7–8) (18, 19).

Reverse transcription PCR

Total RNA was extracted from frozen skin specimens of 13 cases of BN and 10 healthy subjects, using TRIzol Reagent (Life Technologies, Carlsbad, CA, USA), quantitated by spectrophotometer

(Eppendorf, Hamburg, Germany) and reverse transcribed with M-MLV RTase cDNA Synthesis Kit (TaKaRa Biotechnology Co. Ltd, Dalian, China). The primer sets (Table SII¹) were synthesized by Sangon Biotech Co. Ltd (Shanghai, China). PCR was performed using S1000[™] Thermal Cycler (Bio-Rad Laboratories, Hercules, CA, USA) in a final volume of 20 μ l, containing 1 μ l template cDNA, 1 μ l primer, 10 μ l Premix Ex Taq[™]II (TaKaRa Biotechnology Co. Ltd) and 8 μ l distilled water. Amplification conditions included initial denaturation at 98°C for 5 min, 30 cycles of amplification (98°C for 30 s, adapted annealing temperatures for 30 s, and 72°C for 40 s), and final extension at 72°C for 5 min. Amplification products were electrophoresed in 1.2% agarose gel, stained with GelRed[™] (Biotium Inc., Hayward, CA, USA) and visualized under UV transillumination. The relative gene expression of AR, ER and PR was normalized to GAPDH.

Western blot

The frozen skin specimens of 13 BN cases and 10 healthy subjects were lysed using PRO-PREP[™] Protein Extraction Solution (iNtRON Biotechnology, Seongnam, Republic of Korea). Protein concentrations were determined using BCA Protein Assay Kit (Beyotime Biotech, Jiangsu, China). Thirty microgram total protein was subjected to SDS-polyacrylamide gel electrophoresis and transferred onto polyvinylidene fluoride membrane (ISEQ00010; Millipore Corporation, Billerica, MA, USA). Membranes were blocked with 5% skim milk for 1 h, and then incubated with primary antibodies (AR, 1:1 000; ER α , 1:250; ER β , 1:500; PR, 1:250; rabbit anti-human GAPDH, 1:2 000, clone 14C10, cat. 2118, Cell Signaling Technology) overnight at 4°C. Subsequently, membranes were incubated with horseradish peroxidase-labelled secondary antibodies (goat anti-rabbit IgG (cat. 7074) for AR, ER α , PR and GAPDH; horse anti-mouse IgG (cat. 7076) for ER β ; Cell Signaling Technology) at 1:5 000 dilution for 1–2 h at room temperature. The immunoblots were visualized using Immobilon[™] Western Chemiluminescent HRP Substrate (Millipore Corp.) and photographed using X-ray films. The grey values were acquired with Image J software. AR, ER and PR protein expression was standardized as the ratio to GAPDH.

Statistical analysis

RT-PCR and Western blot results were analysed using one-way analysis of variance with least significant difference test, while immunohistochemical data were evaluated using Kruskal–Wallis and Mann–Whitney tests. The relationship between AR, ER and PR immunohistochemical expression in the epidermis was determined by Spearman's rank correlation analysis. $p < 0.05$ was considered significant.

RESULTS

Clinicopathological characteristics

All patients presented with asymptomatic brown patches with irregular borders, with no mucosal involvement or family history of BN. Skin lesions were most common on the scapular region and proximal limbs (Table S1¹). Hypertrichosis was observed in 17 cases (85%). The main pathological changes included rete ridge elongation and fusion (100%), keratotic plugging (70%), acanthosis (75%), basal pigmentation (95%), sebaceous hyperplasia (80%), smooth muscle hyperplasia (75%) and mild perivascular lymphohistiocytic infiltration in the superficial dermis (100%).

¹<https://doi.org/10.2340/00015555-2986>

Androgen receptor expression

AR immunoreactivity was observed in basal and spinous layers of epidermal keratinocytes, pilosebaceous glands, eccrine glands, fibroblasts, inflammatory cells and vascular endothelial cells in lesional, perilesional and control skin. Epidermal AR expression was incremental in BN lesional skin compared with control skin ($p < 0.01$). AR immunostaining was higher in the hair follicles and sebaceous glands of BN lesional skin than in perilesional skin ($p < 0.01-0.05$) (Fig. 1, Table SIII¹). RT-PCR and WB results revealed that AR mRNA and protein levels were higher in lesional and perilesional skin than in control skin ($p < 0.01-0.05$), with the highest in BN lesional skin (Figs 2-3).

Oestrogen receptor expression

ER α and ER β immunoreactivity was detected in the basal and spinous layers of epidermal keratinocytes, pilosebaceous glands, eccrine glands, fibroblasts, inflammatory cells and vascular endothelial cells. Epidermal ER α and ER β expression was increased in lesional and perilesional skin compared with control skin ($p < 0.01$), especially in BN lesional skin. ER α and ER β immunostaining of hair follicles was increased in BN lesional skin compared

with perilesional skin ($p < 0.01-0.05$), but that of sebaceous glands showed no difference between lesional and perilesional skin ($p > 0.05$) (Fig. 1, Table SIII¹). RT-PCR showed that ER α and ER β mRNA levels were upregulated in lesional and perilesional skin compared with control skin ($p < 0.01$), with the maximum level in BN lesional skin (Fig. 2). However, WB demonstrated that ER α and ER β protein levels were augmented in BN lesions compared with perilesional and control skin ($p < 0.05$) (Fig. 3).

Progesterone receptor expression

PR staining was localized in basal and spinous layers of epidermal keratinocytes, pilosebaceous glands, eccrine glands, fibroblasts, inflammatory cells and vascular endothelial cells. Epidermal PR expression was higher in lesional and perilesional skin than in control skin ($p < 0.01-0.05$), with the highest level in BN lesions. PR overexpression was present in hair follicles ($p < 0.01$), but not in sebaceous glands ($p > 0.05$) in BN lesions compared with perilesional skin (Fig. 1, Table SIII¹). RT-PCR and WB revealed that PR mRNA and protein level was higher in lesional and perilesional skin than in control skin ($p < 0.01-0.05$) (Figs 2 and 3).

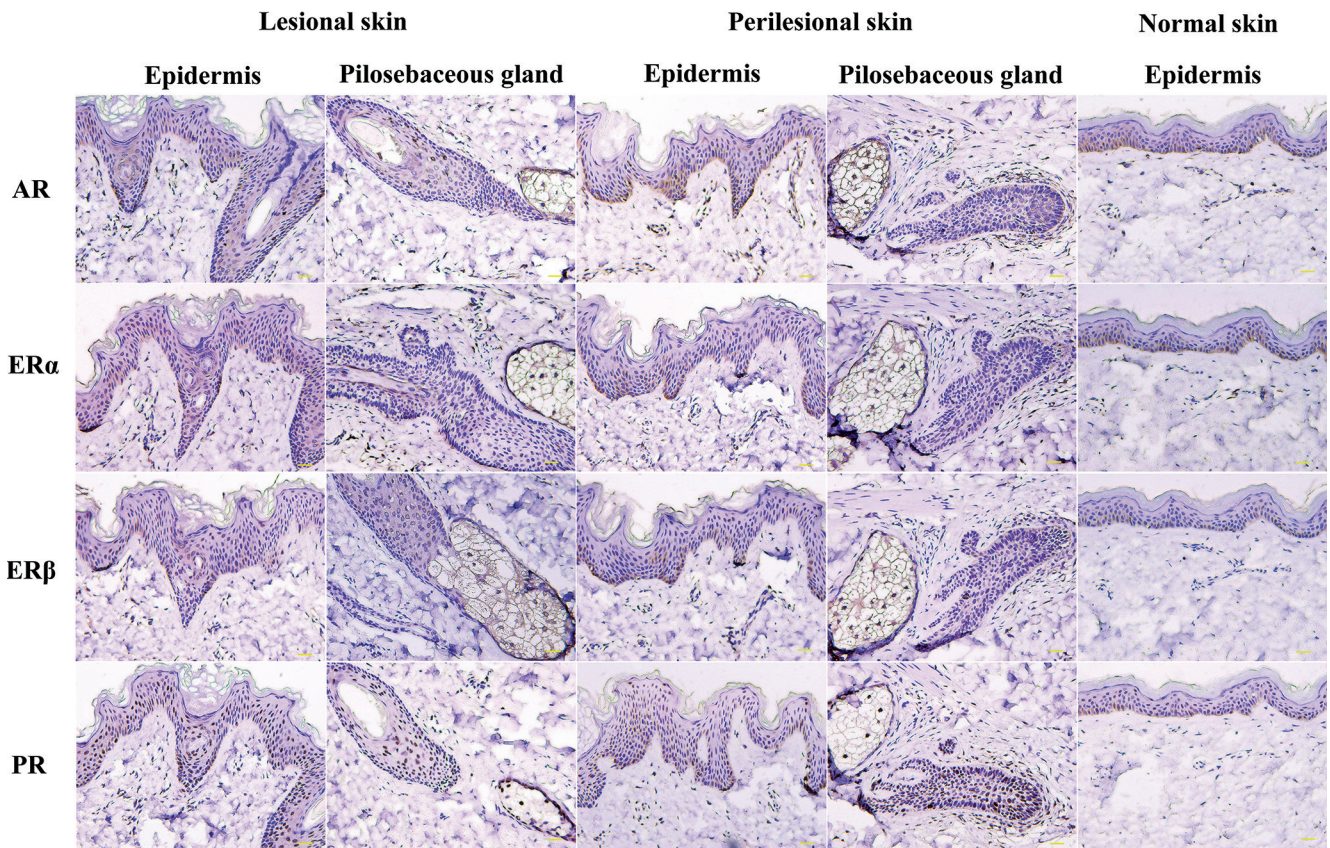


Fig. 1. Androgen receptor (AR), oestrogen receptor (ER) α , ER β and progesterone receptor (PR) immunoreactivity in the epidermis and pilosebaceous glands of Becker's naevus (BN) and normal skin (immunostaining; bar=50 μ m).

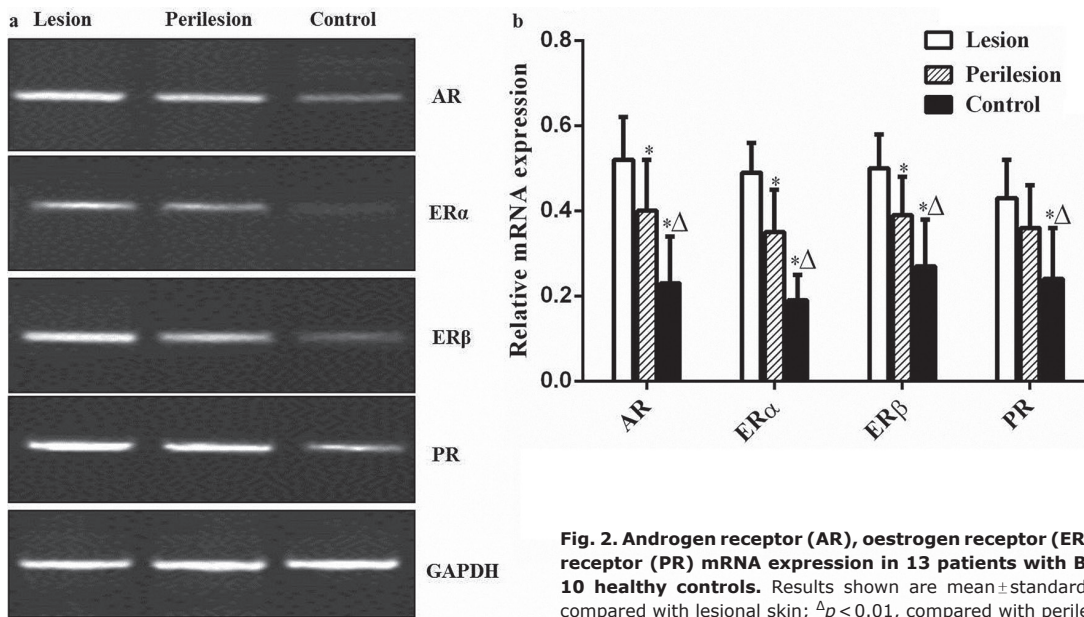


Fig. 2. Androgen receptor (AR), oestrogen receptor (ER) α , ER β and progesterone receptor (PR) mRNA expression in 13 patients with Becker's naevus (BN) and 10 healthy controls. Results shown are mean \pm standard deviation (SD). * p < 0.01, compared with lesional skin; Δp < 0.01, compared with perilesional skin.

Relationship between immunohistochemical expression of androgen, oestrogen and progesterone receptors in the epidermis

Except for a significant positive correlation between ER α and ER β immunoreactivity ($r=0.524$, $p=0.018$), no significant relationship was observed among AR, ER and PR expression in the epidermis.

DISCUSSION

There have been a few reports on AR expression in BN lesions. Ligand-binding assay showed incremental AR amount in 1 boy (13) and 2 girls with ipsilateral breast hypoplasia (14). RT-PCR and ligand-binding assay revealed higher AR levels of the cultured fibroblasts from

a man (15). Immunohistochemical staining showed AR overexpression in the epidermis (12) and dermal fibroblasts (11). Similarly, our results displayed higher levels of AR mRNA and protein in the epidermis and pilosebaceous glands of BN lesions compared with perilesional and control skin.

Androgen can stimulate epidermal proliferation (20) and regulate hair growth in a body-site-dependent manner in humans (21). Androgen/AR signalling accelerated premature senescence in human dermal papilla cells (22). AR modulated the hair cycle via suppressing Wnt/ β -catenin signalling in adult mouse epidermis (23). On the other hand, previous studies showed that androgen alone stimulated proliferation, but did not induce differentiation and lipogenesis in cultured human sebocytes, while a recent report found that androgen induced sebaceous

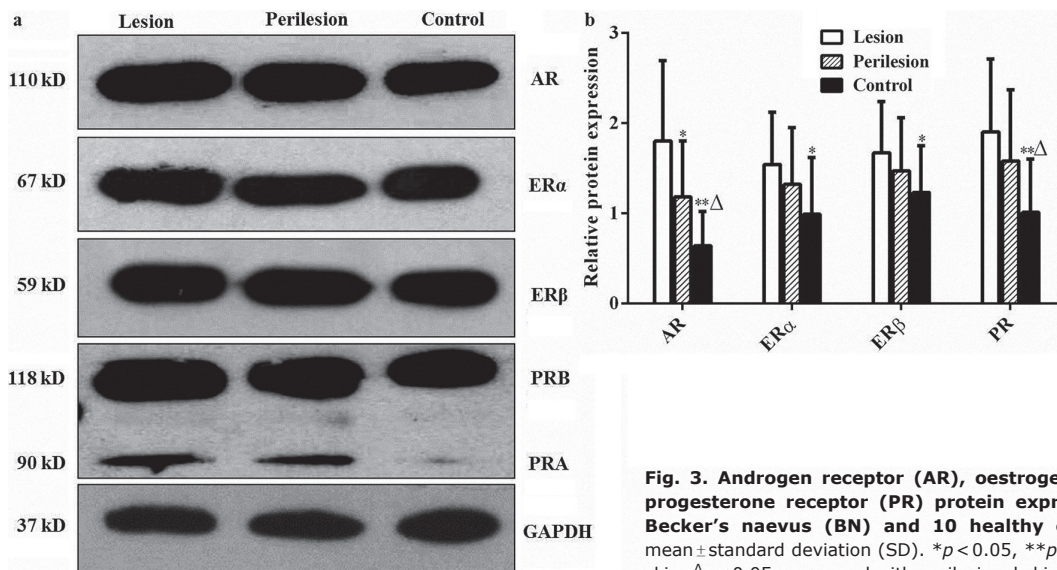


Fig. 3. Androgen receptor (AR), oestrogen receptor (ER) α , ER β and progesterone receptor (PR) protein expression in 13 patients with Becker's naevus (BN) and 10 healthy controls. Results shown are mean \pm standard deviation (SD). * p < 0.05, ** p < 0.01, compared with lesional skin; Δp < 0.05, compared with perilesional skin.

proliferation, differentiation, lipogenesis and apoptosis in SEBO662 sebocytes (24). AR activation promoted MYC-induced sebaceous gland differentiation in mice (25). Therefore, AR hyperactivity in this study is likely to explain the pubescent onset and clinicopathological alterations of acne, hirsutism, acanthosis, dermal thickening and smooth muscle hyperplasia in BN (11).

The current study showed that levels of ER α and ER β mRNA and protein were higher in BN lesions than in perilesional and control skin. ER α and ER β immunoreactivity was upregulated in hair follicles, but not in sebaceous glands of lesional skin compared with perilesional skin. Oestrogen increases collagen content, dermal thickness and water content in human skin (26). Oestrogen can stimulate keratinocyte proliferation in human epidermis and hair follicles, and suppress epidermal keratinocyte apoptosis (27). Oestrogen was originally described to inhibit lipogenesis in human sebaceous glands, but it had no influence on proliferation of, and lipid synthesis in, SZ95 sebocytes (28). Physiological concentration of oestradiol stimulated keratinocyte proliferation by upregulating the level of ER α (29), while pharmacological activation of ER β , but not ER α , induced keratinocyte proliferation and differentiation (30). ER α generally exhibits pro-proliferative and anti-apoptotic effects, while ER β has the opposite effect. Because ER β can counteract the stimulatory effects of ER α through their heterodimerization, the response of the target cell to oestrogen may rely on the ER α /ER β ratio (31). Thus, the results of the current study suggest that oestrogen might enhance acanthosis and hypertrichosis via the dominant ER α .

The role of progesterone in skin and pilosebaceous glands is unclear. Progesterone enhances keratinocyte proliferation and blocks the activity of 5 α -reductase (32). Progesterone significantly inhibited dihydrotestosterone synthesis in dermal papillae of human hair follicles (33). Progesterone increased human sebum secretion (9), but did not affect proliferation and lipid synthesis in SZ95 cells (28). In this study, BN lesions showed higher levels of PR mRNA and protein compared with control skin. Immunostaining scores of PR were incremental in hair follicles other than sebaceous glands in lesional vs. perilesional skin. These results imply that progesterone could facilitate epidermal proliferation, but suppress hair follicle growth.

Hyperpigmentation is the main manifestation of BN, but its mechanism is unknown. In a previous study we found an increase in Melan-A⁺ melanocytes in BN lesions (1). Androgen reduced tyrosinase activity in human melanocytes (34), while oestrogen promoted proliferation, tyrosinase activity and pigment synthesis (35). Oestrogen increased, but progesterone decreased pigment production in human melanocytes (10). Meanwhile, melanocortin 1 receptor plays a central role in determining human cutaneous pigmentation. Oestradiol increased, testosterone reduced, while progesterone had

no effect on melanocortin 1 receptor expression in human melanocytes (36). Therefore, ER overexpression may be primarily responsible for the hyperpigmentation in BN.

AR, ER α , ER β and PR expression was usually higher in perilesional normal-appearing skin than in control skin in this study, suggesting that the abnormal activities of these sex hormones may be present in perilesional skin despite its inconspicuous appearance (12).

It is noteworthy that steroid receptors can cross-talk with one another (37). Androgen can mimic the progesterone actions via an AR-independent mechanism, while progesterone can imitate, inhibit and reinforce the androgen effects (38). Oestrogen activates AR in the absence of testosterone and dihydrotestosterone (39), whereas testosterone metabolites motivate ER β in mouse prostate, leading to a reduction in the level of AR (37). PR activation can reduce ER α -driven proliferation in breast cancer cells (7), while progesterone-induced rapid ER α activation can upregulate expression of PR (40). Collectively, local balance among androgen, oestrogen and progesterone levels may serve to fine-tune their actions in the target cells (37). Seleit et al. (27) found a positive correlation between ER β and AR immunoreactivity in 60 normal skin samples. However, this study revealed that epidermal AR expression was not correlated with ER and PR expression, except for a direct relationship between ER α and ER β immunostaining in 20 BN lesions. Although the effect of sample size and biopsy site may not be excluded, our results imply an imbalance of these sex hormone receptors in BN lesions. The interdependence of AR, ER and PR signalling pathways needs to be determined in normal skin and BN lesions.

A limitation of this study was the small sample size, thus the statistical power may be limited and correlation analysis was not performed between clinicopathological variables and sex hormone receptors. In addition, the sex difference in epidermal AR and ER β immunoreactivity is insignificant in patients with BN and normal subjects (12, 27). The male/female ratio of BN was 4.5:1 in our previous survey (1). Thus, 17 male and 3 female patients with BN were enrolled in this study.

In conclusion, these results suggest that the simultaneous overexpression of AR, ER α , ER β and PR might be implicated in the pathogenesis of BN. The abnormal activities of these sex hormone receptors are present in perilesional normal-appearing skin. Large sample studies are needed to demystify the potential roles of AR, ER and PR signalling pathways and their interactions in BN.

ACKNOWLEDGEMENTS

This study was supported by grants from the Scientific and Technological Project of Zhanjiang City (number 2014B101) and Outstanding Master Cultivation Programme of Guangdong Medical University (number 4CX14091G).

The authors have no conflicts of interest to declare.

REFERENCES

- Sheng P, Cheng YL, Cai CC, Guo WJ, Zhou Y, Shi G, et al. Clinicopathological features and immunohistochemical alterations of keratinocyte proliferation, melanocyte density, smooth muscle hyperplasia and nerve fiber distribution in Becker's nevus. *Ann Dermatol* 2016; 28: 697–703.
- Patel P, Malik K, Khachemoune A. Sebaceous and Becker's nevus: overview of their presentation, pathogenesis, associations, and treatment. *Am J Clin Dermatol* 2015; 16: 197–204.
- Cai ED, Sun BK, Chiang A, Rogers A, Bernet L, Cheng B, et al. Postzygotic mutations in beta-actin are associated with Becker's nevus and Becker's nevus syndrome. *J Invest Dermatol* 2017; 137: 1795–1798.
- Davey RA, Grossmann M. Androgen receptor structure, function and biology: from bench to bedside. *Clin Biochem Rev* 2016; 37: 3–15.
- Ellmann S, Sticht H, Thiel F, Beckmann MW, Strick R, Strissel PL. Estrogen and progesterone receptors: from molecular structures to clinical targets. *Cell Mol Life Sci* 2009; 66: 2405–2426.
- Thornton MJ. Estrogens and aging skin. *Dermatoendocrinol* 2013; 5: 264–270.
- Grimm SL, Hartig SM, Edwards DP. Progesterone receptor signaling mechanisms. *J Mol Biol* 2016; 428: 3831–3849.
- Zouboulis CC, Chen WC, Thornton MJ, Qin K, Rosenfield R. Sexual hormones in human skin. *Horm Metab Res* 2007; 39: 85–95.
- Kanda N, Watanabe S. Regulatory roles of sex hormones in cutaneous biology and immunology. *J Dermatol Sci* 2005; 38: 1–7.
- Natale CA, Duperrret EK, Zhang J, Sadeghi R, Dahal A, O'Brien KT, et al. Sex steroids regulate skin pigmentation through nonclassical membrane-bound receptors. *Elife* 2016; 5: e15104.
- Grande Sarpa H, Harris R, Hansen CD, Callis Duffin KP, Florell SR, Hadley ML. Androgen receptor expression patterns in Becker's nevi: an immunohistochemical study. *J Am Acad Dermatol* 2008; 59: 834–838.
- Kim YJ, Han JH, Kang HY, Lee ES, Kim YC. Androgen receptor overexpression in Becker nevus: histopathologic and immunohistochemical analysis. *J Cutan Pathol* 2008; 35: 1121–1126.
- Person JR, Longcope C. Becker's nevus: an androgen-mediated hyperplasia with increased androgen receptors. *J Am Acad Dermatol* 1984; 10: 235–238.
- Formigón M, Alsina MM, Mascaró JM, Rivera F. Becker's nevus and ipsilateral breast hypoplasia – androgen – receptor study in two patients. *Arch Dermatol* 1992; 128: 992–993.
- Nirdé P, Dereure O, Belon C, Lumbroso S, Guilhou JJ, Sultan C. The association of Becker nevus with hypersensitivity to androgens. *Arch Dermatol* 1999; 135: 212–214.
- Hoon Jung J, Chan Kim Y, Joon Park H, Woo Cinn Y. Becker's nevus with ipsilateral breast hypoplasia: improvement with spironolactone. *J Dermatol* 2003; 30: 154–156.
- Taheri A, Mansoori P, Sandoval LF, Feldman SR. Treatment of Becker nevus with topical flutamide. *J Am Acad Dermatol* 2013; 69: e147–148.
- Leake R, Barnes D, Pinder S, Ellis I, Anderson L, Anderson T, et al. Immunohistochemical detection of steroid receptors in breast cancer: a working protocol. UK Receptor Group, UK NEQAS, The Scottish Breast Cancer Pathology Group, and The Receptor and Biomarker Study Group of the EORTC. *J Clin Pathol* 2000; 53: 634–635.
- Wasielowski Rv, Hasselmann S, Rüschoff J, Fisseler-Eckhoff A, Kreipe H. Proficiency testing of immunohistochemical biomarker assays in breast cancer. *Virchows Arch* 2008; 453: 537–543.
- Fimmel S, Kurfurst R, Bonté F, Zouboulis CC. Responsiveness to androgens and effectiveness of antisense oligonucleotides against the androgen receptor on human epidermal keratinocytes is dependent on the age of the donor and the location of cell origin. *Horm Metab Res* 2007; 39: 157–165.
- Inui S, Itami S. Androgen actions on the human hair follicle: perspectives. *Exp Dermatol* 2013; 22: 168–171.
- Yang YC, Fu HC, Wu CY, Wei KT, Huang KE, Kang HY. Androgen receptor accelerates premature senescence of human dermal papilla cells in association with DNA damage. *PLoS One* 2013; 8: e79434.
- Kretzschmar K, Cottle DL, Schweiger PJ, Watt FM. The androgen receptor antagonizes Wnt/ β -catenin signaling in epidermal stem cells. *J Invest Dermatol* 2015; 135: 2753–2763.
- Barrault C, Garnier J, Pedretti N, Cordier-Dirikoc S, Ratineau E, Deguercy A, et al. Androgens induce sebaceous differentiation in sebocyte cells expressing a stable functional androgen receptor. *J Steroid Biochem Mol Biol* 2015; 152: 34–44.
- Cottle DL, Kretzschmar K, Schweiger PJ, Quist SR, Gollnick HP, Natsuga K, Aoyagi S, Watt FM. c-MYC-induced sebaceous gland differentiation is controlled by an androgen receptor/ $p53$ axis. *Cell Rep* 2013; 3: 427–441.
- Rieger S, Zhao H, Martin P, Abe K, Lisse TS. The role of nuclear hormone receptors in cutaneous wound repair. *Cell Biochem Funct* 2015; 33: 1–13.
- Seleit I, Bakry OA, El Repey HS, Ali R. Intrinsic versus extrinsic aging: a histopathological, morphometric and immunohistochemical study of estrogen receptor β and androgen receptor. *Skin Pharmacol Physiol* 2016; 29: 178–189.
- Tóth BI, Oláh A, Szöllosi AG, Czifra G, Bíró T. "Sebocytes' makeup": novel mechanisms and concepts in the physiology of the human sebaceous glands. *Pflugers Arch* 2011; 461: 593–606.
- Verdier-Sevrain S, Yaar M, Cantatore J, Traish A, Gilchrist BA. Estradiol induces proliferation of keratinocytes via a receptor mediated mechanism. *FASEB J* 2004; 18: 1252–1254.
- Perželová V, Sabol F, Vasilenko T, Novotný M, Kováč I, Slezák M, et al. Pharmacological activation of estrogen receptors- α and - β differentially modulates keratinocyte differentiation with functional impact on wound healing. *Int J Mol Med* 2016; 37: 21–28.
- Powell E, Shanle E, Brinkman A, Li J, Keles S, Wisinski KB, et al. Identification of estrogen receptor dimer selective ligands reveals growth-inhibitory effects on cells that co-express ER α and ER β . *PLoS One* 2012; 7: e30993.
- Im S, Lee ES, Kim W, Song J, Kim J, Lee M, et al. Expression of progesterone receptor in human keratinocytes. *J Korean Med Sci* 2000; 15: 647–654.
- Niiyama S, Happle R, Hoffmann R. Influence of estrogens on the androgen metabolism in different subunits of human hair follicles. *Eur J Dermatol* 2001; 11: 195–198.
- Tadokoro T, Rouzaud F, Itami S, Hearing VJ, Yoshikawa K. The inhibitory effect of androgen and sex-hormone-binding globulin on the intracellular cAMP level and tyrosinase activity of normal human melanocytes. *Pigment Cell Res* 2003; 16: 190–197.
- Tang J, Li Q, Cheng B, Huang C, Chen K. Effects of diethylstilbestrol on the proliferation and tyrosinase activity of cultured human melanocytes. *Biomed Rep* 2015; 3: 499–502.
- Scott MC, Suzuki I, Abdel-Malek ZA. Regulation of the human melanocortin 1 receptor expression in epidermal melanocytes by paracrine and endocrine factors and by ultraviolet radiation. *Pigment Cell Res* 2002; 15: 433–439.
- Ohnemus U, Uenal M, Inzunza J, Gustafsson JA, Paus R. The hair follicle as an estrogen target and source. *Endocr Rev* 2006; 27: 677–706.
- Pihlajamaa P, Sahu B, Jänne OA. Determinants of receptor- and tissue-specific actions in androgen signaling. *Endocr Rev* 2015; 36: 357–384.
- Lai JJ, Chang P, Lai KP, Chen L, Chang C. The role of androgen and androgen receptor in skin-related disorders. *Arch Dermatol Res* 2012; 304: 499–510.
- Diep CH, Ahrendt H, Lange CA. Progesterone induces progesterone receptor gene (PGR) expression via rapid activation of protein kinase pathways required for cooperative estrogen receptor alpha (ER) and progesterone receptor (PR) genomic action at ER/PR target genes. *Steroids* 2016; 114: 48–58.