

## Ichthyosis Prematurity Syndrome due to a Novel *SLC27A4* Homozygous Mutation in an Italian Patient

Andrea DIOCIAIUTI<sup>1</sup>, Enrico ROSATI<sup>2</sup>, Maria Giovanna PAGLIETTI<sup>3</sup>, Paola VACCA<sup>2</sup>, Renata BOLDRINI<sup>4</sup>, Elisa PISANESCHI<sup>5</sup>, Daniele CASTIGLIA<sup>6</sup>, Antonio NOVELLI<sup>5</sup> and May EL HACHEM<sup>1</sup>

<sup>1</sup>Dermatology Unit, <sup>2</sup>Respiratory Unit, <sup>3</sup>Pathology Unit and <sup>5</sup>Laboratory of Medical Genetics, Bambino Gesù Children's Hospital-IRCCS, Rome, <sup>2</sup>Neonatology Unit, Perrino Hospital, Brindisi, and <sup>6</sup>Laboratory of Molecular and Cell Biology, Istituto Dermatologico dell'Immacolata, IRCCS, Rome, Italy. E-mail: andrea.diociaiuti@opbg.net

Accepted Apr 26, 2018; Epub ahead of print Apr 27, 2018

Ichthyosis prematurity syndrome (IPS) (OMIM #608649) is a rare autosomal recessively inherited syndromic ichthyosis characterized by prematurity and respiratory distress, a thick vernix caseosa-like material and transient eosinophilia. Ichthyosis manifestations rapidly improve, while the majority of patients develop atopy signs and increased levels of IgE (1, 2). The disease gene, *SLC27A4*, encodes the fatty acid transporter protein 4 (FATP4), a member of the FATP family involved in fatty acid trafficking (2), expressed in the epidermis. IPS is observed mainly in Scandinavian countries, but isolated cases have been described worldwide (1–8). We report here the first molecular characterization of an Italian case of IPS.

### CASE REPORT

The proband is a male, born at 29-week gestation weighing 1,744 g with healthy non-consanguineous parents. During pregnancy, polyhydramnios with hyperechogenic amniotic fluid had been detected on ultrasound examination. At birth, severe respiratory distress (Apgar scores 1, 4, 7 at 1, 5 and 10 min) required intubation. Laboratory examination showed marked eosinophilia (38%). The neonate was extubated on day 10, and remained dependent on inhaled oxygen until day 40. Chest X-ray repeatedly showed bilateral lung atelectasis. At birth, the skin appeared erythrodermic and oedematous (Fig. 1a) with a thick vernix caseosa-like desquamation, rapidly shed with hair loss. Erythroderma also disappeared, leaving a xerotic skin with cobblestone appearance and whitish scales (Fig. 1b). IPS was suspected, and molecular testing requested to our Medical Genetic Laboratory, following informed consent. Variant analysis, performed on genomic DNA from the infant and his parents using a next generation sequencing panel with inherited ichthyosis genes (9), revealed a novel homozygous missense variant c.931C>T, p.Arg311Trp in the *SLC27A4* gene (NM\_005094.3) in the proband. Sanger sequencing confirmed the mutation in homozygous and heterozygous status in the patient and his parents, respectively. Mutation p.Arg311Trp has not been previously reported, and is not annotated in any database of human

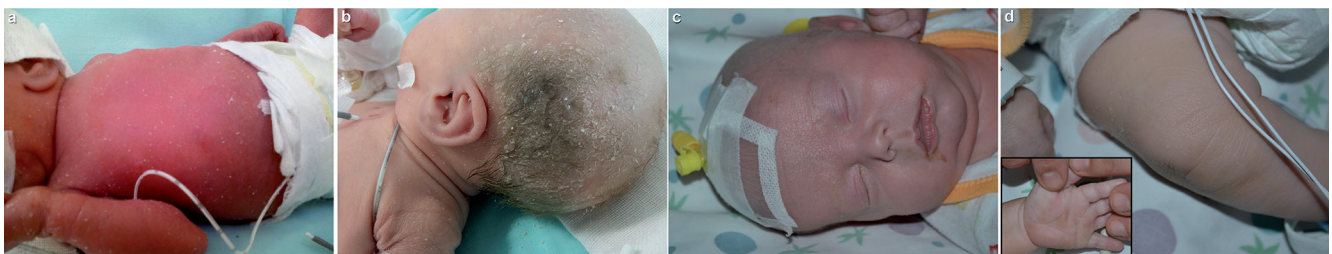genetic variations; pathogenicity prediction software define it as deleterious and probably damaging (SIFT: 0; PolyPhen-2: 0.998) supporting its pathogenic role (Fig. 2a). Alignment of domains from orthologous and paralogous FATP proteins shows a strong predilection for a charged basic amino acid at position 311, with arginine being the most conserved residue, attesting at mutation functional relevance (Fig. S1<sup>1</sup>).

At 2 months of age, the patient was transferred to our hospital to manage his respiratory distress. Physical examination showed diffuse hyperkeratosis, accentuated skin markings, mild palmoplantar keratoderma, and persistent alopecia (Fig. 1c, d). Eosinophilia was still present (16%). He was dyspnoeic and tachypneic, and chest X-ray confirmed persistent lung atelectasis. A bronchoscopy did not reveal significant involvement of the upper airways. Nevertheless, ultrastructural examination of bronchoalveolar lavage (BAL) fluid showed the presence of remnants of shed stratum corneum composed of corneocytes containing the typical multilamellar structures in the cytoplasm (Fig. 2b). The same structures were also seen in the granular and horny layer in a skin biopsy (Fig. 2c). During hospitalization, the patient's skin condition improved further (Fig. S2<sup>1</sup>), but the infant manifested severe itching, gastro-oesophageal reflux, and continued to experience episodes of polypnoea. Training for non-invasive mechanical ventilation to enhance alveolar recruitment improved the respiratory symptoms, allowing the infant to be discharged. However, recurrent infectious episodes required additional hospitalization. At 7 months of age, cow's milk protein allergy was diagnosed. At present, the child, aged 10 months, presents dry skin with minimal scaling, and scalp hair regrowth, while itching remains severe.

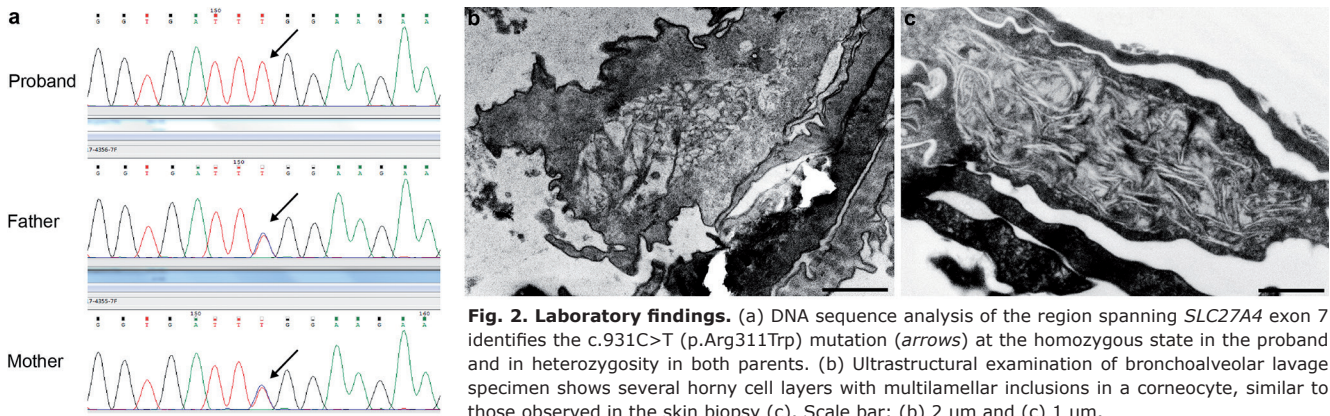
### DISCUSSION

IPS is a very rare syndromic ichthyosis (1–8, 10). Pregnancy complications are polyhydramnios and a hyperechogenic amniotic fluid due to massive foetal epidermal cell shedding. Like most cases of IPS, our

<sup>1</sup><https://doi.org/10.2340/00015555-2957>



**Fig. 1. Patient's clinical features.** (a) Erythroderma with oedema and trunk desquamation at birth. (b) Hyperkeratosis with accentuation of skin markings, and desquamation, the latter particularly marked on the partially alopecic scalp, at week 2. (c) Improved ichthyosis manifestations at 2 months of age: (c) forehead hyperkeratosis and scaling with scalp hair, eyelash and eyebrow loss; (d) hyperkeratosis with accentuation of skin markings and mild desquamation of lower limb, and palmar hyperkeratosis (*inset*). Permission is given by the parents to publish these photos.



**Fig. 2. Laboratory findings.** (a) DNA sequence analysis of the region spanning *SLC27A4* exon 7 identifies the c.931C>T (p.Arg311Trp) mutation (arrows) at the homozygous state in the proband and in heterozygosity in both parents. (b) Ultrastructural examination of bronchoalveolar lavage specimen shows several horny cell layers with multilamellar inclusions in a corneocyte, similar to those observed in the skin biopsy (c). Scale bar: (b) 2  $\mu$ m and (c) 1  $\mu$ m.

patient had neonatal asphyxia, requiring intubation and long-term hospitalization. Respiratory symptoms are related to aspiration of corneocyte-containing amniotic fluid, as documented for the first time *in vivo* in our patient by the presence of corneocytes with lamellar inclusions in the BAL samples. Lamellar membranes in the uppermost epidermis represented the ultrastructural hallmark of IPS until the identification of the causative gene (1, 2, 11). In contrast, the impressive skin manifestations at birth improve rapidly (1, 2, 4–8). Transient eosinophilia and the increase in IgE levels are frequently accompanied by gastrointestinal and/or respiratory atopy manifestations (1, 6). The severe pruritus experienced by IPS patients can probably be ascribed to both ichthyotic skin and atopy.

FATP4 protein acts as a fatty acid transporter and an acyl-coenzyme A synthetase in the epidermis. A deficiency of both functions is responsible for altered lipid transport and composition in IPS, as attested by disease mouse models (2, 12). Our patient is homozygous for a previously undescribed *SLC27A4* missense mutation, p.Arg311Trp, which changes a highly conserved residue of the ATP/AMP motif (aa 243–345) in the AMP-binding domain (aa 103–536), a critical region for FATP4 function. To date, 18 *SLC27A4* point mutations have been reported, the majority affecting the AMP-binding domain (Table S1<sup>1</sup>) (1, 2, 4, 8, 13–15). However, no genotype-phenotype correlation has been delineated.

In conclusion, awareness of IPS is mandatory to guarantee optimal neonatal care and improve prognosis.

## REFERENCES

1. Khnykin D, Rønnevig J, Johnsson M, Sitek JC, Blaas HG, Hausser I, et al. Ichthyosis prematurity syndrome: clinical evaluation of 17 families with a rare disorder of lipid metabolism. *J Am Acad Dermatol* 2012; 66: 606–616.
2. Klar J, Schweiger M, Zimmerman R, Zechner R, Li H, Torma H, et al. Mutations in the fatty acid transport protein 4 gene cause the ichthyosis prematurity syndrome. *Am J Hum Genet* 2009; 85: 248–253.
3. Brusasco A, Gelmetti C, Tadini G, Caputo R. Ichthyosis congenita type IV: a new case resembling mastocytosis. *Br J Dermatol* 1997; 136: 377–379.
4. Morice-Picard F, Léauté-Labrèze C, Decor A, Boralevi F, Lacombe D, Taieb A, et al. A novel mutation in the fatty acid transport protein 4 gene in a patient initially described as affected by self-healing congenital verruciform hyperkeratosis. *Am J Med Genet* 2010; 152A: 2664–2665.
5. Tsuge I, Morishita M, Kato T, Tsutsumi M, Inagaki H, Mori Y, et al. Identification of novel FATP4 mutations in a Japanese patient with ichthyosis prematurity syndrome. *Hum Genome Var* 2015; 2: 15003.
6. George R, Santhanam S, Samuel R, Chapla A, Hilmarsen HT, Braathen GJ, et al. Ichthyosis prematurity syndrome caused by a novel missense mutation in FATP4 gene – a case report from India. *Clin Case Rep* 2015; 4: 87–89.
7. Kiely C, Devaney D, Fischer J, Lenane P, Irvine AD. Ichthyosis prematurity syndrome: a case report and review of known mutations. *Pediatr Dermatol* 2014; 31: 517–518.
8. Inhoff O, Hausser I, Schneider SW, Khnykin D, Jahnsen FL, Sartoris J, et al. Ichthyosis prematurity syndrome caused by a novel fatty acid transport protein 4 gene mutation in a German infant. *Arch Dermatol* 2011; 147: 750–752.
9. Diociaiuti A, El Hachem M, Pisaneschi E, Giancristoforo S, Genovese S, Sirleto P, et al. Role of molecular testing in the multidisciplinary diagnostic approach of ichthyosis. *Orphanet J Rare Dis* 2016; 11: 4.
10. Pigg MH, Bygum A, Gånemo A, Virtanen M, Brandrup F, Zimmer AD, et al. Spectrum of autosomal recessive congenital ichthyosis in Scandinavia: clinical characteristics and novel and recurrent mutations in 132 patients. *Acta Derm Venereol* 2016; 96: 932–937.
11. Niemi KM, Kuokkanen K, Kanerva L, Ignatius J. Recessive ichthyosis congenita type IV. *Am J Dermatopathol* 1993; 15: 224–228.
12. Lin MH, Miner JH. Fatty acid transport protein 1 can compensate for fatty acid transport protein 4 in the developing mouse epidermis. *J Invest Dermatol* 2015; 135: 462–470.
13. Sobol M, Dahl N, Klar J. FATP4 missense and nonsense mutations cause similar features in Ichthyosis Prematurity Syndrome. *BMC Res Notes* 2011; 4: 90.
14. Bueno E, Cañueto J, García-Patos V, Vicente MA, Bodet-Castillo D, Hernández-Ruiz ME, et al. Novel mutations in FATP4 gene in two families with ichthyosis prematurity syndrome. *J Eur Acad Dermatol Venereol* 2017; 31: e11–e13.
15. Gertow K, Bellanda M, Eriksson P, Boquist S, Hamsten A, Sunnerhagen M, et al. Genetic and structural evaluation of fatty acid transport protein-4 in relation to markers of the insulin resistance syndrome. *J Clin Endocrinol Metab* 2004; 89: 392–399.