

A Postzygotic *SMO* Mutation Caused the Original Case of Happle-Tinschert Syndrome

Martin ZENKER¹, Sigrid TINSCHERT^{2,3}, Ilse WIELAND¹, Denny SCHANZE¹ and Rudolf HAPPLE⁴

¹Institute of Human Genetics, University Hospital Magdeburg, Otto-von-Guericke University, Leipziger Str. 44, DE-39120 Magdeburg, ²Medical Faculty Carl Gustav Carus, Technical University, Dresden, Germany, ³Division of Human Genetics, Medical University of Innsbruck, Austria, and ⁴Department of Dermatology, Medical Center – University of Freiburg, Germany. E-mail: martin.zenker@med.ovgu.de
Accepted Jan 15, 2018; Epub ahead of print Jan 16, 2018

In 2008, we delineated a distinct sporadically occurring syndrome in the form of segmentally arranged basaloid follicular hamartomas with osseous, dental and cerebral anomalies (1). The reported patient was a 39-year-old man with multiple skin tumours that showed, in part, comedo-like plugging and were arranged in a unilateral, systematized pattern following Blaschko's lines (Fig. 1a). The patient's ipsilateral (right) leg was 22.5 cm shorter than the left leg. Rudimentary preaxial polydactyly was noted on the left hand and right foot. The right maxillary teeth were hypoplastic. Moreover, the right side of his chest was rather hairless, and linear areas of atrophoderma and hyperpigmentation involved the right arm and lower leg. Eight similar cases were found in the literature, and we argued that this disorder should not be conflated with mosaic forms of Gorlin syndrome (1). Subsequently, several similar cases were reported (2–6), and the name "Happle-Tinschert syndrome" (HTS) was proposed (2).

In 2016, Khamaysi et al. (7) reported an activating *SMO* mutation in what they believed to represent a mosaic form of Gorlin syndrome. In a Letter to the Editor (8), we argued that their patient did not have "segmental basal cell naevus syndrome", but HTS. Moreover, we suggested that HTS may turn out to be a clinical variant of Curry-Jones syndrome (CJS) that is likewise caused by postzygotic *SMO* mutations (9). In their reply, however, Khamaysi et al. (10) upheld their opinion that the presented case belonged to the spectrum of Gorlin syndrome because the patient "displayed diagnostic criteria for Gorlin syndrome but not for HTS or CJS".

Meanwhile, we had the opportunity to analyse the *SMO* gene in DNA from a native cryoconserved tissue sample obtained from a skin area with basaloid follicular hamartomas of the original HTS patient reported in 2008 (1). Genotyping was performed by standard Sanger sequencing. As demonstrated in Fig. 1b, we could identify the sequence change c.1234C>T in the DNA sample. The fraction of mutated DNA was calculated to be 20–30%, thus suggesting a mosaic status. The observed mutation predicts the missense change p.Leu412Phe in the *SMO* protein and is the known recurrent *SMO* mutation that had been found in CJS (9) and in the patient reported by Khamaysi et al. (7). These findings corroborate our previous hypothesis that HTS is indeed caused by mosaic *SMO* mutations and represents a variant of CJS. We therefore postulate that the phenotype reported by Khamaysi et al. (7) belongs to this spectrum of sporadically occurring mosaic *SMO* disorders.

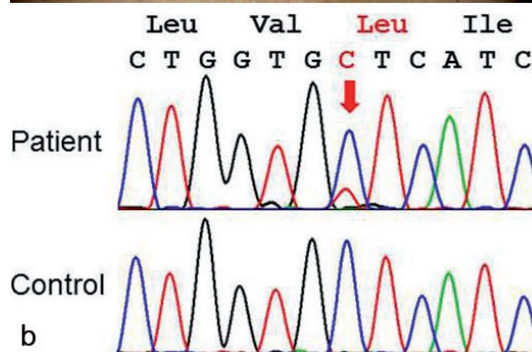
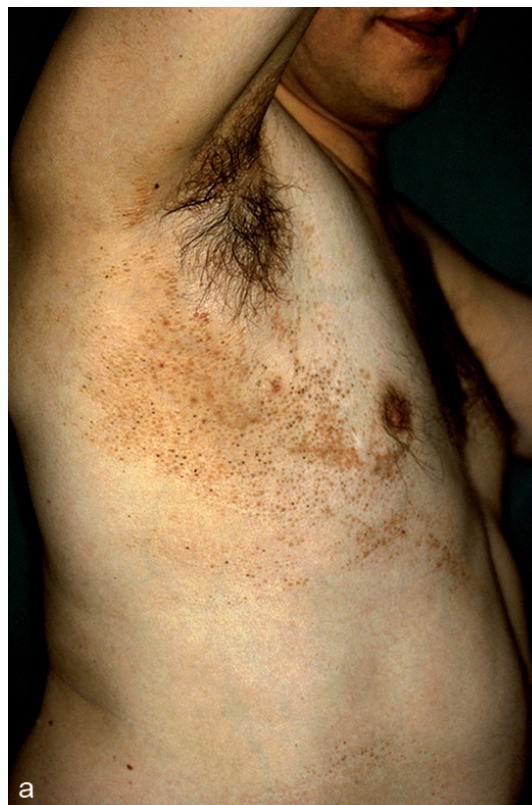

Fig. 1. Happle-Tinschert syndrome. (a) Unpublished photograph of multiple basaloid follicular hamartomas in the original case from 2008 (1). (b) Demonstration of the mosaic *SMO* mutation c.1234C>T (p.Leu412Phe) in lesional tissue from the patient.

The authors have no conflicts of interest to declare.

REFERENCES

- Happle R, Tinschert S. Segmentally arranged basaloid follicular hamartomas with osseous, dental and cerebral anomalies: a distinct syndrome. *Acta Derm Venereol* 2008;

- 88: 382–387.
2. Itin PH. Happle-Tinschert syndrome: segmentally arranged basaloid follicular hamartomas, linear atrophoderma with hypo- and hyperpigmentation, enamel defects, ipsilateral hypertrichosis, and skeletal and cerebral anomalies. *Dermatology* 2009; 218: 221–225.
 3. Boccaletti V, Accorsi P, Pinelli L, Ungari M, Giordano L, Neri I, et al. Congenital systematized basaloid follicular hamartoma with microphthalmia and hemimegalencephaly. *Pediatr Dermatol* 2011; 28: 555–560.
 4. Lo CS, Wu YF, Hsiao YW, Chung WH, Yang CH. Unilateral segmentally arranged basaloid follicular hamartomas with osteoma cutis and hypodontia: a case of Happle-Tinschert syndrome. *Clin Exp Dermatol* 2013; 38: 862–865.
 5. Özgür A, Çabuk G, Arpacı R, Baz K, Katar D. Happle-Tinschert syndrome: report of a case with hemimegalencephaly. *Korean J Radiol* 2014; 15: 534–537.
 6. Haneef NS, Ramachandra S, Metta AK, Sushmalatha B, Belam SS, Ohatkar N. Happle-Tinschert syndrome: report of a newly delineated entity. *Indian J Dermatol Venereol Leprol* 2014; 80: 71–73.
 7. Khamaysi Z, Bochner R, Indelman M, Magal L, Avitan-Hersh E, Sarig O, et al. Segmental basal cell naevus syndrome caused by an activating mutation in *smoothed*. *Br J Dermatol* 2016; 175: 178–181.
 8. Happle R, Tinschert S. Happle-Tinschert syndrome can be caused by a mosaic *SMO* mutation and is suggested to be a variant of Curry-Jones syndrome. *Br J Dermatol* 2016; 175: 1108.
 9. Twigg SRF, Hufnagel RB, Miller KA, Zhou Y, McGowan SJ, Taylor J, et al. A recurrent mosaic mutation in *SMO*, encoding the hedgehog signal transducer *Smoothed*, is the major cause of Curry-Jones syndrome. *Am J Hum Genet* 2016; 98: 1256–1265.
 10. Khamaysi Z, Sprecher E, Bergman R. Happle-Tinschert syndrome can be caused by a mosaic *SMO* mutation and is suggested to be a variant of Curry-Jones syndrome: reply from the authors. *Br J Dermatol* 2016; 175: 1109.