

## Allergic Contact Dermatitis Due to Ripasudil Hydrochloride Hydrate in Eye-drops: A Case Report

Minori KUSAKABE, Yasutomo IMAI\*, Masaru NATSUAKI and Kiyofumi YAMANISHI

Department of Dermatology, Hyogo College of Medicine, 1-1, Mukogawa-cho, Nishinomiya, Hyogo 663-8501, Japan. \*E-mail: imai-yas@hyo-med.ac.jp

Accepted Oct 31, 2017; Epub ahead of print Nov 7, 2017

Ripasudil is a rho kinase (rho-associated coiled-coil-containing protein kinase/ROCK) inhibitor, which decreases intraocular pressure (IOP) by increasing outflow facility (1). Glanatec® ophthalmic solution 0.4% (Kowa Company Ltd, Nagoya, Japan) containing ripasudil hydrochloride hydrate was approved only in Japan in December 2014 for treatment of glaucoma and ocular hypertension (2). To date no adverse skin reactions to the drug have been documented. We report here the first case of allergic contact dermatitis due to ripasudil hydrochloride hydrate in Glanatec® eye-drops.

### CASE REPORT

A 74-year-old Japanese woman with glaucoma had been treated with eye-drops for 13 years. She had applied 4 types of eye-drops: brimonidine tartrate 0.2% (Aiphagan®; Senju Pharmaceutical Co., Ltd, Osaka, Japan), brinzolamide 1% (Azopt®; Alcon Japan Ltd, Tokyo, Japan), travoprost 0.004% and timolol maleate 0.5% (DuoTrav® combination ophthalmic solution; Alcon Japan Ltd), and bunazosin hydrochloride 0.01% (Detantol®; Eisai, Tokyo, Japan). However, because her IOP was uncontrolled, Glanatec® was prescribed in place of Detantol®. Three months later, painful and itchy erythemas appeared on

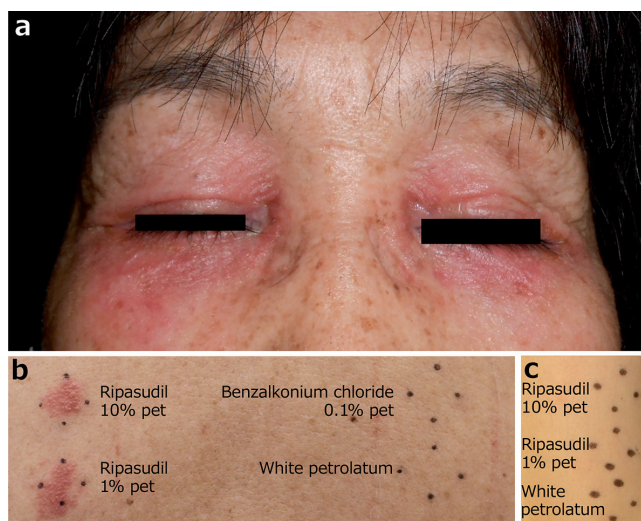
both of her periocular regions. She visited several clinics and was treated with prednisolone acetate ophthalmic ointment and oral fexofenadine for one year, but these treatments were not effective.

At her first visit to our department, marked erythemas were observed on her periocular areas (Fig. 1a). Allergic contact dermatitis due to the eye-drops was suspected, and patch-testing was performed using a Finn Chambers® (Smart Practice Japan, Yokohama, Japan). Reactions were evaluated 2 and 3 days after application of the suspected drugs, according to the recommendation of the International Contact Dermatitis Research Group. Glanatec®, as is, was positive (D2<sup>++</sup>/D3<sup>++</sup>), and patch testing for each ingredient of Glanatec® was positive (D2<sup>++</sup>/D3<sup>++</sup>) for ripasudil (10% pet, 1% pet), but negative for benzalkonium chloride, which was added as a preservative (Fig. 1b). No reactions to ripasudil were seen in the healthy control subjects (Fig. 1c). Therefore, allergic contact dermatitis caused by ripasudil, an active ingredient of Glanatec®, was diagnosed. After switching from Glanatec® to Detantol® and applying topical hydrocortisone butyrate ointment, the woman's periocular erythemas were resolved. Control patch tests were performed on 3 healthy subjects.

### DISCUSSION

Glaucoma is a disorder with elevated IOP, which damages the ophthalmic nerves and may lead to blindness. This ocular disease is the world's most frequent cause of acquired loss of eyesight (3). Different kinds of eye-drops, such as prostaglandins,  $\beta$ -blocker,  $\alpha\beta$ -blocker,  $\alpha$ 1-blocker, carbonic anhydrase-blocker, sympathomimetic stimulant,  $\alpha$ 2-stimulant, and rho kinase blocker, are available to control IOP. It is recommended that treatment to control IOP starts with only one drug, but several types of drugs are sometimes applied in combination. In such cases, the risk of contact dermatitis is thought to increase (4). In the present case, the woman may have been sensitized to ripasudil through using several eye-drops, including Glanatec®. Patch-testing for benzalkonium chloride was negative, and therefore she could use another eye-drop, Detantol®, which contained the same preservative.

This is the first report of a case of contact dermatitis due to ripasudil. As Glanatec® will be used for the treatment of glaucoma worldwide, similar cases might be likely to increase in the future.



**Fig. 1. Clinical features and results of patch testing.** (a) Bilateral periocular erythemas. (b) The patient had positive reactions to both ripasudil hydrochloride hydrate (ripasudil) 10% and 1% pet in patch testing. (c) The healthy control subjects had negative reactions to ripasudil in patch testing. Data shown are representative of 3 volunteers. A written permission from the patient is given to publish this photo.

## ACKNOWLEDGEMENTS

This work was supported in part by the Manabe Research Foundation Award.

*The authors have no conflicts of interest to declare.*

## REFERENCES

1. Kaneko Y, Ohta M, Inoue T, Mizuno K, Isobe T, Tanabe S, et al. Effects of K-115 (Ripasudil), a novel ROCK inhibitor, on trabecular meshwork and Schlemm's canal endothelial cells. *Sci Rep* 2016; 6: 19640.
2. Garnock-Jones KP. Ripasudil: first global approval. *Drugs* 2014; 74: 2211–2215.
3. Jonas JB, Aung T, Bourne RR, Bron AM, Ritch R, Panda-Jonas S. Glaucoma. *Lancet* 2017; 390: 2183–2193.
4. Zheng Y, Chaudhari PR, Maibach HI. Allergic contact dermatitis from ophthalmics: 2007. *Contact Dermatitis* 2007; 57: 11–13.

1. Kaneko Y, Ohta M, Inoue T, Mizuno K, Isobe T, Tanabe S, et