

Lipoid Proteinosis: A Previously Unrecognized Mutation and Therapeutic Response to Acitretin

Claudia CARNEVALE¹, Daniele CASTIGLIA², Andrea DIOCIUTI¹, Vittoria PROTO², Simona GIANCRISTOFORO¹, Renata BOLDRINI³, Giovanna ZAMBRUNO¹ and May EL HACHEM¹

¹Dermatology Division, ²Pathology Unit, Bambino Gesù Children's Hospital-IRCCS, P.zza St Onofrio 4, IT-00165 Rome, ³Laboratory of Molecular and Cell Biology, Istituto Dermatologico dell'Immacolata, IDI-IRCCS, Rome, Italy. E-mail: may.elhachem@opbg.net
Accepted Jul 5, 2017; Epub ahead of print Jul 6, 2017

Lipoid proteinosis (LP), also referred to as hyalinosis cutis et mucosae or Urbach-Wiethe disease, is a rare autosomal recessive genodermatosis characterized by a hoarse voice, and thickening of the skin and mucous membranes with pox-like scarring (1, 2). Onset is usually in infancy, with hoarse cry, while skin lesions can manifest in early childhood or later. They consist of yellowish infiltrated papules and nodules, and verrucous hyperkeratosis of the elbows, knees and buttocks. Beaded papules of the eyelids, also known as moniliform blepharosis, are the most typical sign of the disease. In addition, skin fragility may be present during childhood, resulting in trauma-induced vesicles and blisters with residual acneiform scars. Mucosal lesions always comprise vocal cord and laryngeal thickening, accompanied by variable tongue, palate, and lip infiltration. Extracutaneous signs may include epilepsy and neuropsychiatric disorders associated with cerebral calcifications (1, 2). LP is characterized by periodic acid–Schiff (PAS)-positive basement membrane thickening around blood vessels, adnexa, and along the dermal–epidermal junction (DEJ), as well as hyaline deposition in the dermis. The disease is due to mutations in the *ECMI* gene, which has 4 major splice variants encoding isoforms of extracellular matrix protein 1 involved in the structural organization of the dermis (1–4).

CASE REPORT

A 17-year-old male was referred to our Rare Skin Disease Center with hoarseness worsening over the previous 2 years. He was the first son of healthy non-consanguineous parents. In infancy he had presented trauma-induced vesicles and blisters on the legs and nappy area, followed a few months later, by similar lesions on the hands and dysphonia. At the age of 3 years, he had received a diagnosis of epidermolysis bullosa simplex. In the

following years, skin thickening over the elbows, knees, and buttocks developed gradually, while skin fragility waned. Papular lesions on the eyelid borders were noticed at 11 years of age. On admission, physical examination revealed beaded papules of the eyelids, atrophic and hypochromic scars on the limbs and buttocks, verrucous skin plaques of the knees, buttocks and elbows (Fig. 1a, c). The lip commissures presented small waxy papules, and the tongue was slightly thickened with reduced mobility due to a short and infiltrated frenulum (Fig. 1e). The hair and nails were not affected. In addition, the patient presented hoarseness, but no breathing problems. He was otherwise healthy and never manifested epilepsy or other neurological signs. LP was suspected and laryngoscopy, cerebral computed tomography (CT) scan and a skin biopsy performed. Laryngoscopy showed focal thickening of the

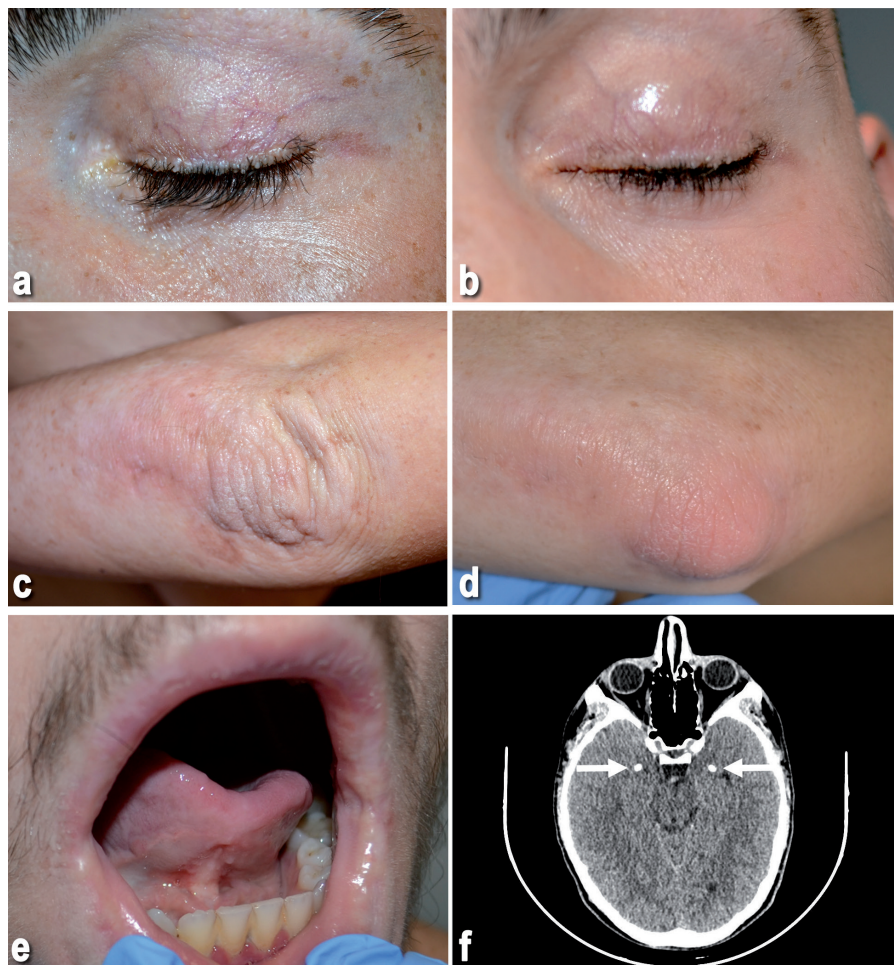


Fig. 1. Patient's clinical and imaging features. (a) Moniliform blepharosis at presentation and (b) after 6 months of acitretin therapy. (c) Elbow skin thickening and hyperkeratosis also appear markedly improved (d) after 6 months of acitretin treatment. (e) Lingual frenulum and lip commissure infiltration. (f) Cerebral computed tomography (CT) scan showing bilateral symmetrical calcifications of the mesial-temporal lobes (arrows).

vocal cords and waxy papular infiltration of the laryngeal posterior commissure. In addition, CT scan revealed bilateral symmetrical hyperintense nodules of 3–4 mm size, localized on the mesial temporal lobes, compatible with calcifications (Fig. 1f). Histopathological examination revealed PAS-positive thickening of DEJ, around vessels and adnexa and accumulation of a hyaline material in the dermis. Immunofluorescence demonstrated broad reticular staining for type IV collagen along the DEJ, in the upper dermis and around the vessels (Fig. S1a, b¹). Ultrastructural examination confirmed the presence of numerous lamina densa duplications around dermal vessels (Fig. S1c¹). Altogether, these findings were consistent with LP. The diagnosis was also confirmed by mutation screening of the *ECM1* gene, which showed 2 heterozygous truncating mutations, c.735_736delTG (p.Cys245*) in exon 7 and c.1446_1450delCCCTG (p.Ala484Leufs*9) in exon 10 (mutation designation according to NM_004425.3 NCBI reference sequence) inherited from the father and the mother, respectively (Fig. S1d¹) (5). The former variant is a mutation previously described in LP patients; the latter variant is here reported for the first time associated with LP (3–6). Both variants were screened and never detected in the constitutive DNA of 60 Italian individuals. At protein level, the p.Ala484Leufs*9 results in a short missense sequence, which alters one of the typical cysteine-containing motifs [CC-(X7-10)C] of ECM1, followed by a premature termination codon that deletes the last 47 amino acids from the C-terminus. This region is known to interact with perlecan, an important component of basement membranes (4, 7). The c.1446_1450delCCCTG is found neither in 1,000 genomes nor ExAc browser databases, while it is annotated in the Exome Variant Server as marking 47 alleles out of 12,473 (allele frequency: 0.0038) of the American subpopulation of African and European origin (ESP6500 release) that comprises healthy controls, but also individuals with heart, lung and blood disorders or with extremes of specific traits inherent to these conditions. Unexpectedly, 46 out of 47 of these alleles are entered in homozygosity and only one in heterozygosity. An explanation for the occurrence of homozygote genotypes is that these individuals might have subclinical or disregarded LP phenotype, or a different disease trait not directly correlated with LP. However, cohort or phenotype information about any particular individual of ESP6500 is not publicly available. In addition, large-scale validation by Sanger sequencing of ESP variants was not performed (<http://evs.gs.washington.edu/EVS/>). Thus, the possibility that ESP6500 data released for the c.1446_1450delCCCTG variant are not correct should also be considered.

Our patient was started on oral acitretin treatment (0.5 mg/kg/day), which resulted in major improvement in moniliform blepharosis, skin thickening and verrucous lesions, already evident after 3 months and more marked at 6 months (Fig. 1b, d). Hoarseness also appeared reduced, while laryngoscopy did not show significant modifications. Acitretin was discontinued due to the development of multiple and painful toenail pyogenic granulomas.

DISCUSSION

In childhood, our patient received a diagnosis of epidermolysis bullosa based on the presence of trauma-induced blistering. In the first years of life, differential diagnosis of LP also includes erythropoietic protoporphyria, which can show photo-induced vesicular lesions. However, the cardinal features of hoarseness and moniliform blepharosis usually orientate the clinician towards LP, which is then confirmed by histopathological examination.

Our patient presented a mild phenotype with limited scarring sequelae and modest mucosal involvement. In theory, transcripts with mutation c.1446_1450delCCCTG in the most 3' exon (exon 10) are predicted to escape from nonsense mRNA decay leading to the synthesis of truncated polypeptides, while mutation p.Cys245* in exon 7 allows the expression of the *ECM1b* splice variant, which lacks exon 7 (4). However, survey of the global *ECM1* mutation database (HGMD Professional) (3–6, 8–10) reveals that homozygous nonsense mutations in exon 10, such as the p.Arg481*, result in full-blown disease, and that LP patients with mutation in exon 7 are often not milder than individuals carrying mutations outside this exon. Moreover, intra-familial and inter-familial disease variability is recognized in LP (4, 9). Therefore, with respect to type and position of the pathogenic mutations described thus far, no clear genotype-phenotype correlation is evident. Patient age and, as-yet unidentified, genetic and environmental modifiers are likely additional determinants of disease severity (4, 9).

Oral retinoid efficacy in LP has been reported in single cases and one small case series (11–14). Acitretin administration at doses of 0.5 mg/kg/day has been described to lead to variable improvement in cutaneous papules and plaques, skin softening, reduction in blistering and concomitant amelioration of mucosal lesions and hoarseness. In the majority of patients acitretin efficacy was more evident on mucosal than on skin lesions. The specific mechanism of action of acitretin in LP has not been investigated. It may be related to the modulation of connective tissue metabolism and basement membrane synthesis by retinoids, but also due to a direct effect on the *ECM1* gene, which has been shown to be a retinoic acid-regulated gene in the developing kidney (15). In our patient, skin improvement was particularly impressive, with almost complete disappearance of moniliform blepharosis, verrucous plaques of elbows and knees, and flattening of buttock and perianal lesions (Fig. 1b, d). Hoarseness was also improved. Unfortunately, acitretin was interrupted due to the progressive development of multiple toenail pyogenic granulomas.

ACKNOWLEDGEMENTS

This study was supported by grants from Italian Ministry of Health (Ricerca Corrente Program) to DC.

REFERENCES

- Mcgrath JA. Lipoid proteinosis. *Handb Clin Neurol* 2015; 132: 317–322.
- Vahidnezhad H, Youssefian L, Uitto J. Lipoid proteinosis. 2016 Jan 21. In: Pagon RA, Adam MP, Ardinger HH, Wallace SE, Amemiya A, Bean LJH, et al. editors. *GeneReviews*®. Seattle, WA: University of Washington, Seattle; 1993–2017.
- Hamada T, McLean WH, Ramsay M, Ashton GH, Nanda A, Jenkins T, et al. Lipoid proteinosis maps to 1q21 and is caused by mutations in the extracellular matrix protein 1 gene (*ECM1*). *Hum Mol Genet* 2002; 11: 833–840.

¹<https://doi.org/10.2340/00015555-2752>

4. Chan I, Liu L, Hamada T, Sethuraman G, McGrath JA. The molecular basis of lipoid proteinosis: mutations in extracellular matrix protein 1. *Exp Dermatol* 2007; 16: 881–890.
5. Hamada T, Wessagowit V, South AP, Ashton GH, Chan I, Oyama N, et al. Extracellular matrix protein 1 gene (ECM1) mutations in lipoid proteinosis and genotype-phenotype correlation. *J Invest Dermatol* 2003; 120: 345–350.
6. Almeida TF, Soares DC, Quaio CR, Honjo RS, Bertola DR, McGrath JA, et al. Lipoid proteinosis: rare case confirmed by ECM1 mutation detection. *Int J Pediatr Otorhinolaryngol* 2014; 78: 2314–2315.
7. Mongiat M, Fu J, Oldershaw R, Greenhalgh R, Gown AM, Iozzo RV. Perlecan protein core interacts with extracellular matrix protein 1 (ECM1), a glycoprotein involved in bone formation and angiogenesis. *J Biol Chem* 2003; 278: 17491–17499.
8. Rey LK, Kohlhasse J, Möllenhoff K, Dekomien G, Eppelen JT, Hoffjan S. A novel ECM1 splice site mutation in lipoid proteinosis: case report plus review of the literature. *Mol Syndromol* 2016; 7: 26–31.
9. Horev L, Wollina DU, Potikha T, Hafner A, Ingber A, Liu L, et al. Lipoid proteinosis: identification of two novel mutations in the human ECM-1 gene and lack of genotype-phenotype correlation. *Acta Derm Venereol* 2009; 89: 528–529.
10. Horev L, Potikha T, Ayalon S, Molho-Pessach V, Ingber A, Gany MA, et al. A novel splice-site mutation in ECM-1 gene in a consanguineous family with lipoid proteinosis. *Exp Dermatol* 2005; 14: 891–897.
11. Bakry OA, Samaka RM, Houla NS, Basha MA. Two Egyptian cases of lipoid proteinosis successfully treated with acitretin. *J Dermatol Case Rep* 2014; 8: 29–34.
12. Zhang R, Liu Y, Xue Y, Wang Y, Wang X, Shi S, et al. Treatment of lipoid proteinosis due to the p.C220G mutation in ECM1, a major allele in Chinese patients. *J Transl Med* 2014; 12: 85.
13. Dertlioğlu SB, Çalık M, Çiçek D. Demographic, clinical, and radiologic signs and treatment responses of lipoid proteinosis patients: a 10-case series from Şanlıurfa. *Int J Dermatol* 2014; 53: 516–523.
14. Luo XY, Li Q, Tan Q, Yang H, Xiang J, Miao JK, et al. Treatment of lipoid proteinosis with acitretin in two patients from two unrelated Chinese families with novel nonsense mutations of the ECM1 gene. *J Dermatol* 2016; 43: 804–807.
15. Takayama M, Miyatake K, Nishida E. Identification and characterization of retinoic acid-responsive genes in mouse kidney development. *Genes Cells* 2014; 19: 637–649.