

Concurrent Double Fungal Infections of the Skin Caused by *Phialemoniopsis endophytica* and *Exophiala jeanselmei* in a Patient with Microscopic Polyangiitis

Ayako ITO^{1*}, Nanako YAMADA¹, Ryoko KIMURA¹, Natsumi TANAKA², Jun KURAI², Kazushi ANZAWA³, Takashi MOCHIZUKI³ and Osamu YAMAMOTO¹

¹Division of Dermatology, Department of Medicine of Sensory and Motor Organs, ²Division of Respiratory Medicine and Rheumatology, Faculty of Medicine, Tottori University, 86 Nishi-cho, Yonago, 683-8503, and ³Department of Dermatology, Kanazawa Medical University, Ishikawa, Japan. E-mail: ayama813@med.tottori-u.ac.jp

Accepted Jun 22, 2017; Epub ahead of print Jun 27, 2017

Phaeohyphomycosis is an infection characterized by melanized hyphae, yeast cells, moniliform hyphae, or a mix of these morphotypes in tissue. The causative agents mostly belong to the genera *Exophiala* and *Scedosporium* (1). Hyalohyphomycosis is characterized by hyaline hyphae, such as *Fusarium*, *Scedosporium*, *Acremonium*, *Scopulariopsis*, *Purpureocillium* and *Paecilomyces* (2). We report here a case of concurrent double fungal infections of the skin caused by 2 different species of fungi in an immunocompromised patient: hyalohyphomycosis of the foot due to *Phialemoniopsis endophytica* and phaeohyphomycosis of the hand due to *Exophiala jeanselmei*. This is also the first case report of infection

by *P. endophytica*, which has been described recently as a new species of *Phialemoniopsis*.

CASE REPORT

An 87-year-old Japanese man diagnosed with microscopic polyangiitis presented with polyneuropathy of the lower extremities and renal involvement. He was started on therapy with oral prednisolone, 50 mg daily for a week, following intravenous methylprednisolone, 1,000 mg for 3 days. After gradually tapering the dosage, he had been maintained on prednisolone, 10 mg daily, for 8 years. He was admitted to the department of internal medicine in our hospital for treatment of cholangitis. He had a history for several months of a nodule on his right ankle and a cyst on his right hand. Physical examination revealed an asymptomatic

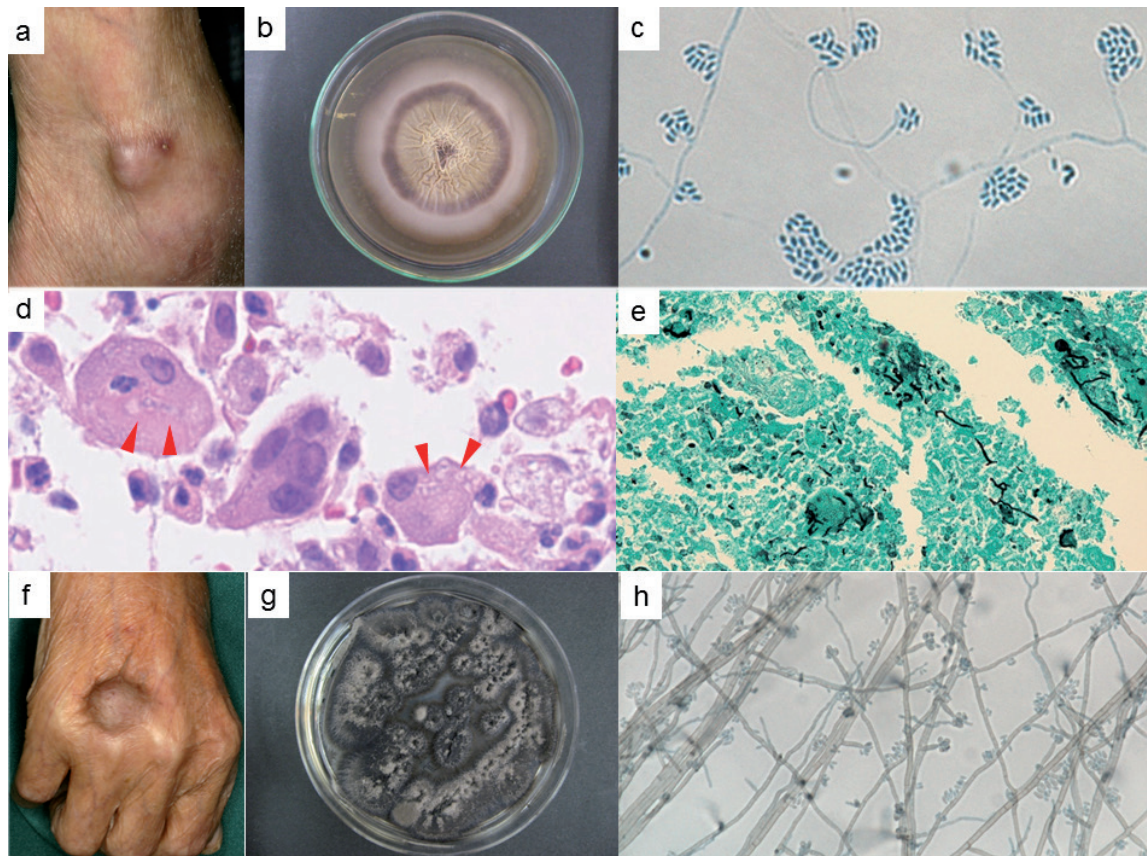


Fig. 1. Phaeohyphomycosis. (a) Greyish pink nodule on the right ankle. (b) *Phialemoniopsis endophytica*. A colony surface after 56 days of incubation on Sabouraud dextrose agar at 27°C. (c) Slide culture after 14 days of incubation. (d) Haematoxylin-eosin stain showing micro-organisms in multinucleated giant cells (arrows). (e) Grocott-Gomori's methenamine silver stain. (f) Subcutaneous cyst on the right hand. (g) *Exophiala jeanselmei*. A colony surface after 14 days of incubation on Sabouraud dextrose agar at 27°C. (h) Slide culture after 14 days of incubation. (c–e, h: original magnification 400x. c, h Lactophenol cotton blue stain.)

greyish pink nodule, 20 mm in size, with purulent discharge on his right ankle (Fig. 1a) and a greyish-brown subcutaneous cyst, 25 mm in size, on the dorsum of his right hand (Fig. 1f). Biopsy and tissue culture from the ankle lesion were performed. Histopathological examination showed a thick-walled cyst in the dermis to the subcutaneous tissue surrounded by multiple mixed-cellular granulomatous inflammations. Round-to-oval thick-walled organisms with hyaline septate hyphae were observed in histiocytes and multinucleated giant cells in the granuloma (Fig. 1d). Grocott-Gomori's methenamine silver stain clearly confirmed these elements to be fungi (Fig. 1e). No melanin pigments were detected in Fontana-Masson staining. Culture of the biopsied specimen resulted in the formation of a brown-white-coloured colony with an annular structure and radial folds after 56 days of incubation on Sabouraud dextrose agar at 27°C (Fig. 1b). The slide culture of the isolate (KMU 9847) showed broad, branched hyphae and aggregation of oval microconidia (Fig. 1c), suggesting *Acremonium* spp. The isolate was identified as *Phialemoniopsis endophytica* by sequence analysis of the internal transcribed spacer regions of ribosomal DNA gene, with one base difference from that of the type strain, ACCC 38980T. The same mycological and molecular results were obtained from a fungal strain (KMU 9921) cultured from discharge from the ankle examined by a general physician 8 days before the patient consulted us.

Direct microscopic examination of aspiration fluid from the cyst on his right hand showed some brown hyphae, and olive-black-coloured colonies grew after 14 days of incubation of fluid content on Sabouraud dextrose agar at 27°C (Fig. 1g). Slide culture showed brownish hyphae and ellipsoidal conidia on brown, bottle-shaped, conidiogenous cells (Fig. 1h). The isolate was identified as *E. jeanselmei* by sequence analysis of the internal transcribed spacer regions of ribosomal DNA gene. Laboratory data showed serum IgG 758 mg/dl (870–1,700 mg/dl), albumin 3.5 g/dl (4.0–5.0 g/dl) and β -D glucan 16.0 pg/ml (<11.0 pg/ml). The patient was in an immunocompromised and poor nutritional state. There was no growth of any organism in blood culture. Computed tomography showed no evidence of systemic involvement.

A diagnosis of hyalohyphomycosis of the foot due to *P. endophytica* and phaeohyphomycosis of the hand due to *E. jeanselmei* was established on the basis of the above findings. Treatment with voriconazole was initiated at a dose of 300 mg/day. Subsequently, each lesion disappeared and the β -D glucan level became normal within 2 months. Additional 4-month treatment with voriconazole was terminated and there was no sign of recurrence after 3 months of follow-up.

DISCUSSION

Recent advances in molecular biology have provided new techniques for identifying dermatophytes and have enabled progress in reclassification of taxa (3). In our case, *P. endophytica* was confirmed as a possible causative agent of infection in human skin by molecular biology techniques.

Phialemoniopsis is a new genus established by Perdomo et al. (4) after phylogenetic investigation of the unidentified clinical isolates of *Acremonium*, *Phialemonium* and *Lecythophora* by detailed morphological and molecular analyses (4, 5). The genus includes 5 species: *P. ocularis* (= *Srcopodium oculorum*), *P. curvata* (= *Phialemonium curvata*), *P. cornearis*, *P. pluriloculosa* and *P. hongkongensis* (4, 6). These species are widely distributed in various environments, including air, indu-

strial water, plant materials, river water, sewage and soil (4). *Phialemoniopsis endophytica*, which was identified in our case, is a novel sixth species of *Phialemoniopsis* that was isolated from the lower stem of *Luffa cylindroca* during a survey of endophytic fungi in cucurbit plants in China by Su et al. in 2016 (5). There is a possibility that traumatic implantation from plants to the patient's skin occurred because he did gardening every day.

Four cases of skin infections caused by *Phialemoniopsis* have been reported previously (6–9). *P. curvata* (7, 8), *P. hongkongensis* (6) and *P. ocularis* (9) were isolated from nodules on the foot (7–9) or forearm (6), and the patients were treated with surgical debridement (8), amphotericin B and ketoconazole with debridement (7), itraconazole (6) or voriconazole (9). Although 2 of the patients were immunocompromised (7, 8), none had systemic involvement. It is notable that a molecular technique was not used to identify the pathogen in 2 cases of skin infection with *P. curvata* (7, 8). *Phialemoniopsis* had been classified into unidentified clinical isolates in *Acremonium*, *Phialemonium* and *Lecythophora* infections before it was established as a new genus. There is a possibility that skin infections caused by *P. endophytica* have been included in such cases. In our case, *P. endophytica* confirmed by molecular technique was isolated for the first time from a lesion of human skin infection.

Among *Phialemoniopsis* species, *P. curvata* has been reported to cause severe systemic and deep-seated organ infections compared with the other 4 species (10). *P. curvata* shows good growth at 37°C and the other 4 species grow at temperatures below 37°C (6). It is widely accepted that fungi growing at 37°C are potential pathogens in a suitable susceptible host (1). The difference in the degree of serious symptoms among species might be related to the difference in degrees of thermotolerance of species. *P. endophytica*, which was identified in our case, grew at less than 37°C, which may explain why there was no evidence of deep-seated organ infection in our case.

It is known that concurrent skin infections due to dual micro-organisms of different species occur in immunocompromised patients (11). The possibility of concurrent double fungal skin infections must be taken into consideration in patients with multiple skin lesions, particularly in immunocompromised patients, as well as skin involvement of disseminated systemic fungal infection. In addition, if the culture is successfully done, recent advances in molecular biology may enable identification of new species as causative agents and thus contribute to the establishment of a therapeutic strategy.

REFERENCES

1. Reiss E, Shadomy HJ, Lyon GM. Fundamental medical mycology. First edition. Hoboken, NJ: John Wiley & Sons, Inc.; 2012.
2. Ajello L. Hyalohyphomycosis and phaeohyphomycosis: two global disease entities of public health importance. Eur J Epidemiol 1986; 2: 243–251.

3. Mochizuki T, Takeda K, Anzawa K. Molecular markers useful for intraspecies subtyping and strain differentiation of dermatophytes. *Mycopathologia* 2017; 182: 57–65.
4. Perdomo H, García D, Gené J, Cano J, Sutton DA, Summerbell R, et al. *Phialemoniopsis*, a new genus of Sordariomycetes, and new species of *Phialemonium* and *Lecythophora*. *Mycologia* 2013; 105: 398–421.
5. Su, L, Deng H, Niu YC. *Phialemoniopsis endophytica* sp. nov., a new species of endophytic fungi from *Luffa cylindrica* in Henan, China. *Mycol Progress* 2016; 15: 48.
6. Tsang CC, Chan JF, Ip PP, Ngan AH, Chen JH, Lau SK, et al. Subcutaneous phaeohyphomycotic nodule due to *Phialemoniopsis hongkongensis* sp. nov. *J Clin Microbiol* 2014; 52: 3280–3289.
7. Heins-Vaccari EM, Machado CM, Saboya RS, Silva RL, Dulley FL, Lacaz CS, et al. *Phialemonium curvatum* infection after bone marrow transplantation. *Rev Inst Med Trop Sao Paulo* 2001; 43: 163–166.
8. King D, Pasarell L, Dixon DM, McGinnis MR, Merz WG. A phaeohyphomycotic cyst and peritonitis caused by *Phialemonium* species and a reevaluation of its taxonomy. *J Clin Microbiol* 1993; 31: 1804–1810.
9. Desoubeaux G, García D, Bailly E, Augereau O, Bacle G, De Muret A, et al. Subcutaneous phaeohyphomycosis due to *Phialemoniopsis ocularis* successfully treated by voriconazole. *Med Mycol Case Rep* 2014; 5: 4–8.
10. Rivero M, Hidalgo A, Alastruey-Izquierdo A, Cía M, Torroba L, Rodríguez-Tudela JL. Infections due to *Phialemonium* species: case report and review. *Med Mycol* 2009; 47: 766–774.
11. Takahara M, Imafuku S, Matsuda T, Uenotsuchi T, Matsumoto T, Padhye AA, et al. Concurrent double infections of the skin: phaeohyphomycosis and nocardiosis in a patient with idiopathic thrombocytopenic purpura. *J Am Acad Dermatol* 2005; 53: 277–280.