



A Novel Actinic Keratosis Field Assessment Scale for Grading Actinic Keratosis Disease Severity

Brigitte DRÉNO¹, Rino CERIO², Thomas DIRSCHKA³, Ignasi FIGUERAS NART⁴, John T. LEAR⁵, Ketty PERIS⁶, Andrés RUIZ DE CASAS⁷, Shaniko KALECI⁸ and Giovanni PELLACANI⁹; Progressing Evidence in AK (PEAK) Working Group

¹Department of Dermato Cancerology, University of Nantes, Nantes, France, ²Department of Cutaneous Medicine and Surgery, The Royal London Hospital and QMUL, Bart's Health NHS Trust, London, UK, ³CentroDerm® Clinic, Wuppertal, and Faculty of Health, University Witten-Herdecke, Witten, Germany, ⁴Department of Dermatology, Bellvitge Hospital, Barcelona, Spain, ⁵Manchester Academic Health Science Centre, MAHSC, Manchester University and Salford Royal NHS Foundation Trust, Royal Infirmary, The University of Manchester, Manchester, UK, ⁶Department of Dermatology, Catholic University of Rome, Rome, Italy, ⁷Dermatology Unit, Virgen Macarena University Hospital, Seville, Spain, ⁸Statistics Unit, Department of Diagnostic Medicine, Clinical and Public Health, and ⁹Department of Dermatology, University of Modena and Reggio Emilia, Modena, Italy

Actinic keratosis (AK) lesions are surrounded by field cancerization (areas of subclinical, non-visible sun damage). Existing AK grading tools rely on AK counts, which are not reproducible. An Actinic Keratosis Field Assessment Scale (AK-FAS) for grading the severity of AK/field was developed. Standardized photographs of patients representing the full range of AK severity were collected. Six investigators independently rated each photograph according to 3 criteria: AK area (total skin area affected by AK lesions), hyperkeratosis and sun damage. Inter-rater reproducibility was good for all 3 criteria. Validation of the AK-FAS showed good reproducibility for AK area and hyperkeratosis, even for dermatologists untrained on use of the scale. In conclusion, the AK-FAS is objective, easy to use and implement, and reproducible. It incorporates assessment of the entire field affected by AK instead of relying on lesion counts. Use of the AK-FAS may standardize AK diagnosis, making it relevant to routine clinical practice.

Key words: actinic keratosis; field cancerization; grading scale.

Accepted May 22, 2017; Epub ahead of print May 24, 2017

Acta Derm Venereol 2017; 97: 1108–1113.

Corr: Brigitte Dréno, Department of Dermato Cancerology, University of Nantes, FR-44093 Nantes, France. E-mail: brigitte.dreno@wanadoo.fr

Actinic keratosis (AK) is a prevalent disease typically affecting areas of sun-exposed skin (1). Estimates of AK prevalence range between 6 and 60% (depending on skin phototype, geographical location, age, and other predisposing factors), and prevalence appears to be increasing. Therefore, AK presents a substantial socio-economic burden, the weight of which will inevitably increase with an ageing population (1, 2).

Surrounding visible AK lesions are areas of subclinical, non-visible sun damage prone to the development of clinically visible or recurrent AK lesions and sun-related skin cancers. This is known as field cancerization (3). In this context, AK can be considered a chronic disease. Treating field cancerization is instrumental in reducing rates of AK recurrence, thus reducing the burden of AK

(4–6). Consequently, recent guidelines advocate treating field cancerization instead of only individual, visible AK lesions (4, 7, 8).

Key barriers to shifting the treatment paradigm in accordance with current guidelines are the lack of a standardized definition of field cancerization and of a reproducible assessment scale for grading the whole area affected by AK. Instead, existing AK grading tools, such as the Olsen clinical classification scale and the Roewert-Huber histological classification scale, assess individual, isolated AK lesions (9–11) and current guidelines rely on lesion counts, which are not reproducible even among experts, to assess AK severity (4, 7, 8, 12–14). A recent study assessing the correlation between clinical and histological assessment of single AK lesions showed that only approximately half of the investigated lesions matched in terms of grading severity on the Olsen and Roewert-Huber scales, thus supporting the notion that clinical classification of single lesions does not accurately assess the underlying histology (15).

The need for a reproducible assessment scale to guide the identification and diagnosis of AK has been highlighted by therapy experts. Such a scale could help to make appropriate treatment decisions and to quantitatively assess response to treatment. The purpose of this study was to develop, test and validate an Actinic Keratosis Field Assessment Scale (AK-FAS) based on photographic clinical cases.

METHODS

Development of Actinic Keratosis Field Assessment Scale (AK-FAS)

Six investigators met on 15 July 2016 to develop and test the AK-FAS.

The initial draft of the AK-FAS was based on a combination of Olsen criteria for AK (9) and an assessment scale developed by the lead investigator, with the following definitions:

- Grade 0 = no AKs on sun-damaged skin.
- Grade I = AK on surrounding skin that is <25% sun damaged.
- Grade II = multiple flat AKs on surrounding skin that is 25–74% sun damaged.
- Grade III = multiple AKs (of visible thickness) on surrounding skin that is >75% sun damaged.

This draft was discussed by the investigators, who identified both the limitations of the scale and potential solutions to overcome these limitations. They found that the proposed definitions were difficult to interpret consistently as many clinical presentations could fall between grades.

A second version of the scale was drafted to overcome these limitations. In this version, the assessment criteria were separated into 3 criteria that could be assessed individually: AK area, hyperkeratosis, and sun damage. AK area is the most important criterion in the scale and the key differentiator from previous tools. Instead of counting AK lesions, all visible alterations identified as AK lesions are assessed, with the AK area defined as the combined total area of the skin affected by AK lesions, given as a percentage of the total skin area assessed (i.e. whole face or scalp), which also includes sub-clinical, non-visible lesions. AK area was graded on a 5-point scale, depending on the percentage range of skin area covered by AK lesions. This should increase reproducibility compared with lesion counts (Table I). Hyperkeratosis and sun damage in the area were then marked as either present or absent. Preliminary testing of this scale, carried out in 12 photographic cases (8 faces and 4 scalps), highlighted that it was limited by differing interpretations of hyperkeratosis presence or absence, which led to discrepancies in clinical assessment. In addition, sun damage had little value as a category as it was always marked as present.

Therefore, in producing the final scale, the grading for AK area was retained and definitions of hyperkeratosis and sun damage presence or absence in terms of their severity were added. Signs considered during the evaluation of sun damage included: erythema, telangiectasia, inflammation, atrophy and pigmentation disorders. Sun damage was defined as moderate or severe if it would lead the investigator to follow up the patient more frequently vs none/mild sun damage, according to the investigator's own judgement. The final AK-FAS is presented in Table I. Photographs representing AK grades I-IV and hyperkeratosis presence/absence, are shown in Fig. 1 and Fig S1¹, respectively.

Validation using selected photographs

Photographs of 108 patients with AK seen in clinical practice by the investigators were provided. All patients provided written permission to use their photographs for research purposes. The photography was standardized, with photographs taken using a digital camera, against a black, blue or white background at a resolution >3 megapixels. Photographs were taken of the first 2 AK patients seen each day by each of the 8 investigators during a 2–3-week period (May–July 2016) and included patients with a range of disease severity on the face or face and scalp. For the face, 3 photographs were taken: front profile and right and left profiles (at an angle of 45° or 90°). One photograph of the scalp was taken in bald patients. To ensure good quality, the first 2 sets

of patient photographs taken by each investigator were assessed by the same reviewer within 2 days of the photographs being taken and feedback was given on their suitability. For standardized presentation, photographs of the face were cropped between the top of the head and the jaw-line, and those of the scalp between the top of the scalp and the eyebrows. The forehead was considered as part of the face and was delineated from the scalp using a demarcation line to ensure that all investigators were assessing exactly the same area when applying the AK-FAS. The entire area shown in the photograph (face or scalp) should be considered when applying the scale.

Once all cases had been collected, each investigator selected the best clinical cases (in terms of image quality) based on their expert judgement, ensuring equal spread across AK severity. All collected cases were submitted to a central server. The pictures considered by the investigators as the best cases ($n=96$) were used for evaluation and validation of the final AK-FAS; the remaining cases ($n=12$) were used during the development of the AK-FAS for preliminary testing.

Testing of Actinic Keratosis Field Assessment Scale (AK-FAS)

The final AK-FAS was tested separately on face and scalp areas (on 66 and 30 photographic cases, respectively). Assessment for each area was repeated (with at least 1 h between assessments) to allow evaluation of inter- and intra-rater agreement. The order of the photographic cases was randomly changed in the repeat assessment, in order to minimize grading by memory. The investigators had not previously seen any of the cases provided by their colleagues and were not allowed to confer during the assessment. Assessment took place using a keypad device that allowed each investigator to grade each case anonymously. For the first assessment session (face) investigators had 15 s (i.e. 45 s in total) to grade each category in the scale (AK area, hyperkeratosis and sun damage) with a 10-s gap (blank screen) in between. For subsequent sessions (repeat face, scalp and repeat scalp) there was no minimum time to select a grade, moving between cases as soon as assessment on all categories had been completed by all investigators. Conditions (lighting and distance from the screen) were standardized and recorded to ensure they were reproducible between sessions.

Validation of Actinic Keratosis Field Assessment Scale (AK-FAS)

The same process described above was subsequently repeated (also face-to-face) by 2 untrained investigators who were not involved in the development of the AK-FAS. They assessed the same photographic cases under the same conditions. Both received only a written description of the final AK-FAS with no training (Table I). Only brief training on the use of the keypad devices used in the anonymous grading of cases was provided, practicing on the same 12 cases used for preliminary testing during the development process.

Statistical methods

Kappa (κ) is commonly used in the medical literature to measure inter-observer variation. The calculation is based on the difference between how much agreement is actually present ("observed" agreement) compared with how much agreement would be expected to be present by chance alone ("expected" agreement) (17). Cohen's κ was calculated to evaluate inter- and intra-rater agreement in the grading of AK using the newly developed AK-FAS for the following situations: face and scalp combined; face only; scalp only. Inter- and intra-rater agreement was assessed for the 6 investigators involved in development of the scale and the 2 investigators involved in validation of the scale.

¹<https://doi.org/10.2340/00015555-2710>

Table I. Final Actinic Keratosis Field Assessment Scale (AK-FAS)

AK Grade	0	I	II	III	IV
AK area (% area covered by AK) ^a	0	<10	10–25	>25–50	>50
Hyperkeratosis severity	+ : ≥ 1 AK(s) with grade II or III and hyperkeratosis ^b ≥ 5 mm in diameter are present in the area – : no hyperkeratosis or grade I hyperkeratosis ^b is present				
Sun damage severity	+ : moderate or severe sun damage, leading to more frequent patient follow-up – : none or mild sun damage Signs considered in the evaluation: erythema, telangiectasia, inflammation, atrophy and pigmentation disorders				

^aIn either face or scalp. ^bAs defined by the Primary Care Dermatology Society (16).

The κ statistic was selected because the variable of interest was binary for hyperkeratosis and sun damage, and could be weighted for categorical AK (Grades 0 to 4). κ is a measure of difference standardized to fit on a -1 to 1 scale, where 1 is perfect agreement, 0 is exactly what would be expected by chance, and negative values indicate agreement less than chance (i.e. potential systematic disagreement between the raters). The interpretation of agreement adopted here is: less than chance agreement ($\kappa < 0$), slight agreement ($\kappa = 0.01-0.20$), fair agreement ($\kappa = 0.21-0.40$), moderate agreement ($\kappa = 0.41-0.60$), substantial agreement ($\kappa = 0.61-0.80$), and almost perfect agreement ($\kappa = 0.81-0.99$) (18). The interpretation of reproducibility adopted is: marginal ($\kappa = 0.00-0.40$), good ($\kappa = 0.40-0.75$) and excellent ($\kappa > 0.75$) (19).

RESULTS

Validation of Actinic Keratosis Field Assessment Scale (AK-FAS) by investigators

Inter-rater reproducibility. There was substantial agreement for 2 criteria (AK area and hyperkeratosis) and moderate agreement for the third criteria (sun damage), indicating good reproducibility between the 6 investigators who developed and tested the scale. For face and scalp combined, the inter-rater κ scores were 0.69, 0.71 and 0.51, respectively (**Table II**). Similar results were

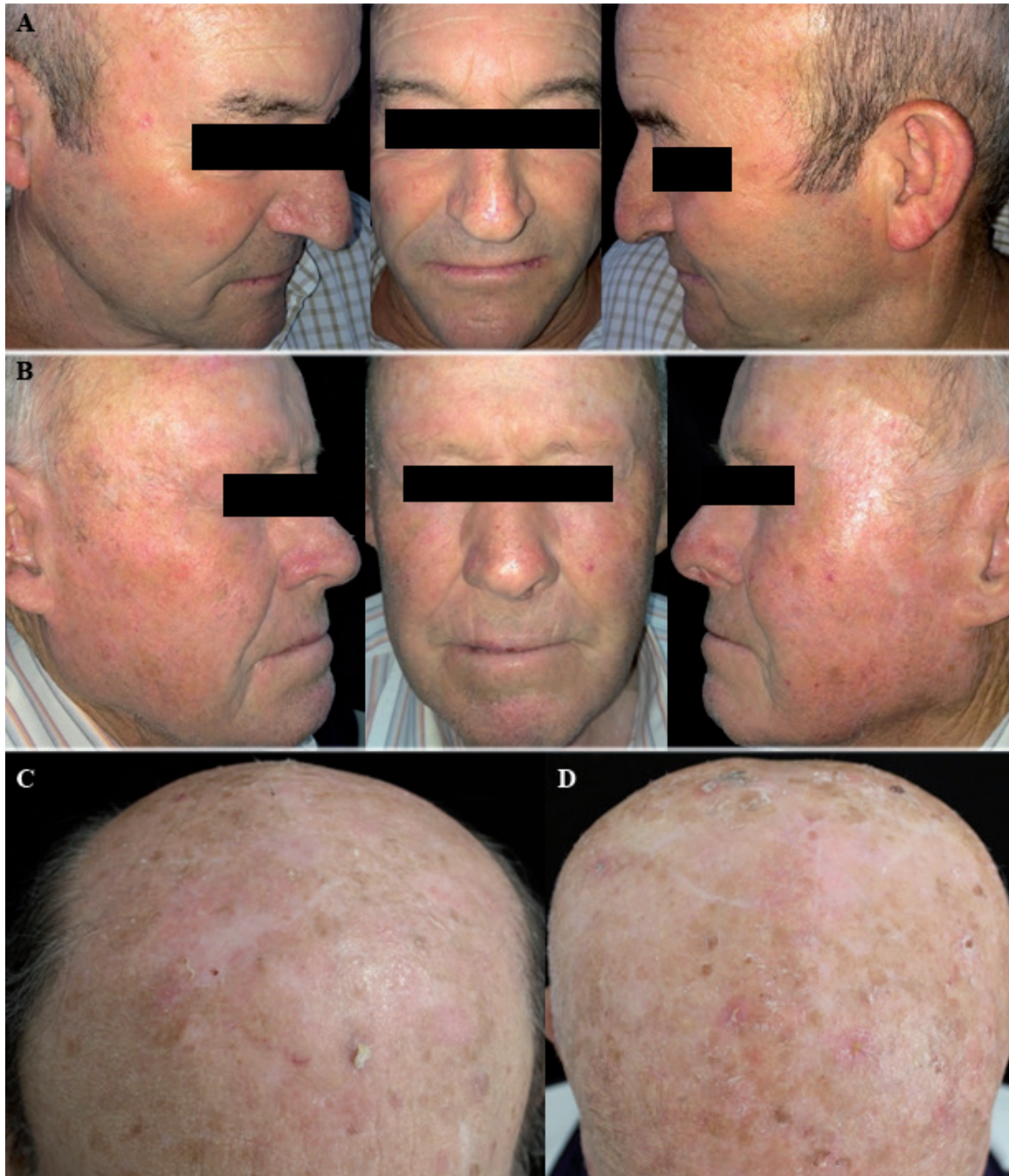


Fig. 1. Actinic keratosis (AK) grade. (A) Grade I: <10% area covered by AK; (B) Grade II: 10–25% area covered by AK; (C) Grade III: >25–50% area covered by AK; (D) Grade IV: >50% area covered by AK.

Table II. Agreement between the 6 investigators who developed and tested the Actinic Keratosis Field Assessment Scale (AK-FAS) and the 2 untrained investigators who validated the AK-FAS

	Investigators who developed the scale (n = 6)				Untrained investigators (n = 2)			
	Agreement %	Expected agreement %	κ	SE	Agreement %	Expected agreement %	κ	SE
Face+scalp								
AK grade	93.35	78.00	0.69	0.03	87.89	69.80	0.59	0.04
Hyperkeratosis	86.19	52.02	0.71	0.04	77.08	49.35	0.54	0.06
Sun damage	93.04	85.81	0.51	0.04	90.10	84.06	0.38	0.06
Face								
AK grade	94.19	82.96	0.65	0.04	87.88	75.83	0.49	0.05
Hyperkeratosis	85.46	56.47	0.66	0.05	74.24	49.54	0.48	0.08
Sun damage	90.66	81.55	0.49	0.04	87.12	78.93	0.38	0.07
Scalp								
AK grade	88.64	64.37	0.68	0.05	87.92	65.74	0.64	0.09
Hyperkeratosis	87.78	51.04	0.75	0.07	83.33	50.00	0.66	0.12
Sun damage	98.32	96.15	0.56	0.06	96.67	96.67	0.00	0.00

AK: actinic keratosis; SE: standard error.

obtained in the evaluation of the face and scalp separately (Table II).

Intra-rater reproducibility. Intra-rater reproducibility was good for all criteria (AK area, hyperkeratosis and sun damage). Corresponding κ values were in the substantial agreement range for all investigators for AK area, almost perfect or substantial agreement range for all but one of the investigators for hyperkeratosis and moderate agreement range for the majority of the investigators for sun damage.

Validation of the Actinic Keratosis Field Assessment Scale (AK-FAS) by untrained investigators

The κ values for the 2 untrained investigators not involved in the development of the scale were lower than, but in alignment with, those obtained during the original testing of the scale with κ scores of 0.59, 0.54 and 0.38, respectively, for AK area, hyperkeratosis and sun damage, indicating moderate agreement (good reproducibility) for AK area and hyperkeratosis, and fair agreement for sun damage (Table II). Similar results were obtained for the face and scalp analysed separately (Table II).

DISCUSSION

The results of this study demonstrate that the newly developed AK-FAS for grading AK severity is objective and easy to use. Reproducibility (both inter- and intra-rater) is good, particularly for 2 criteria (AK area and hyperkeratosis). To our knowledge, the AK-FAS is the only scale considering the extent of skin area affected by AK, rather than lesion counts, which may not describe the extent of the disease and are difficult to reproduce consistently. Considering the extent of the skin area affected by AK (both visible and subclinical lesions) will make the AK-FAS highly relevant for clinical practice.

Despite the relatively small number of investigators involved in the development, testing and validation of the AK-FAS, it was used in over 1,500 gradings (as each of the 8 investigators graded each photograph twice) and the reproducibility results were highly significant. Reproducibility was slightly lower when the analysis was carried out by only the 2 untrained investigators responsible for scale validation, who were not involved in the development of the scale. This is to be expected, as the 6 investigators who developed the scale had lengthy discussions on how to define and use the scale, including a pilot voting session where they discussed their choices of grading, hence calibrating their grading against each other. In contrast, the 2 untrained investigators validating the scale were only provided with a written description of the scale, and had no opportunity for calibrating against each other or with the other investigators.

Interestingly, an assessment of Psoriasis Area and Severity Index (PASI) scoring among patients and physicians with first exposure to PASI showed that use of a simple online training video improved scoring accuracy for both physicians and patients compared with scoring accuracy before training, using the scores of PASI-experienced physicians as the standard for comparison (20). This suggests that some simple training on AK-FAS use, although not essential, would benefit standardization.

Previously, the Olsen scale, which grades severity/thickness of individual AK lesions in isolation, has been the only existing clinical scale used to assess AK severity (9). Consequently, the Olsen scale combined with lesion counts, often within a relatively small area, has been employed in clinical trials of field therapies to assess extent of disease severity and treatment effectiveness (9, 21–23). However, individual lesion counts are associated with poor reproducibility, with different healthcare professionals, including those with extensive experience, likely to calculate different lesion counts when assessing the same patient (12–14). Moreover, reduction in size of lesions is not accounted for as an effect of a treatment and may result in a false-negative effect. Therefore, while assessment of disease severity based on the Olsen scale and lesion counts is practical, it is unreliable and inconsistent for routine application.

Current treatment algorithms and guidelines rely on the Olsen scale and/or lesion counts for assessing disease extent and providing treatment recommendations (4, 8, 24), and such guidelines are therefore also limited for clinical practice. In clinical practice, dermatologists need to assess the severity of AK in the entire area affected in order to make a fully informed decision on optimum disease management options. The AK-FAS reported here is the only scale to grade severity of AK taking into consideration the whole area affected by the disease (entire face or scalp).

A hyperkeratosis grading was included in the AK-FAS. Experts believe that thick AK lesions represent a more advanced disease stage than thin AKs and are therefore more important to treat (13, 25–29). However, recent studies testing a correlation between clinical thickness of AK lesions and dysplasia for the first time, suggest that this may not always be the case (15, 26). Regardless of whether or not hyperkeratosis is indicative of disease progression, most topical treatments for AK are not indicated for use on hyperkeratotic lesions. Therefore, a hyperkeratosis grading is relevant to inform the decision-making process (8).

Sun damage beyond visible AK lesions was included in the AK-FAS as decisions on patient management may be influenced by the severity of sun damage. However, the significance of sun damage is not fully known, as AK lesions can exist on skin with little sign of additional sun damage. Conversely, skin with severe sun damage (e.g. solar elastosis) can be clear of AK lesions. Interestingly, reproducibility for assessment of sun damage was lower than for AK area and hyperkeratosis, highlighting that a clear definition of sun damage in the context of AK is lacking, as is a clear understanding of its implications. Both of these areas would be of interest for future investigation.

The AK-FAS has been developed, tested and validated through the use of photographic scoring. A photographic scale allows the inclusion of patients and assessment by expert dermatologists encompassing several European countries, which would be extremely difficult to achieve in real-life patients. This ensures that the scale is relevant and applicable at a pan-European level and facilitates communication, dissemination and implementation of the AK-FAS. In addition, a photographic scale is very well suited for telemedicine and telediagnosis. This is a growing practice that increases patient access to specialists, reduces waiting times and facilitates communication among healthcare professionals; it is particularly well-suited for dermatology due to the visual nature of the discipline (30). It would be of interest, however, to extend testing and validation of the AK-FAS to patients in the clinic, as palpation of the skin is an important tool in the assessment of AK. Some AKs may only be detectable through palpation, which could lead to discrepancies between the photographic scoring and patient assessment in the clinic. Future research should test this AK-FAS tool in real patients in order to assess if there is a significant discrepancy compared with photographic assessment and to establish potential corrections to the photographic scale if this is the case.

In conclusion, the AK-FAS is an objective and easy to learn and implement assessment of AK that is reproducible and relevant to routine clinical practice, incorporating assessment of the entire field affected by AK rather than individual lesions. It is likely to lead to a more standardized approach than current assessment

scales when diagnosing AK and considering treatment options, which is crucial in AK given the chronicity of the condition. This will potentially increase the cost-effectiveness of AK disease management by maximizing the chances of selecting the most appropriate treatment from the outset, as well as providing an objective method to assess treatment response.

ACKNOWLEDGEMENTS

The authors acknowledge editorial assistance from Lucid Group, funded by LEO Pharma, for developing a first draft from an agreed outline, collating and incorporating comments from all authors during the reviewing process and copyediting the final draft for submission.

Funding sources: This study was funded by LEO Pharma.

Conflict of interest disclosures: All authors act as consultants to LEO Pharma. TD reports receiving lecture fees from Almirall, Biofrontera, Galderma, Janssen, LEO Pharma, Novartis and Riemser; he is a member of advisory boards for Almirall, Biofrontera, Galderma, Janssen, LEO Pharma and Novartis. GP reports receiving a research grant from LEO Pharma, and is a member of advisory boards for LEO Pharma, Roche and Galderma. KP is a member of advisory boards for Abbvie, LEO Pharma, Lilly, Galderma and Roche.

REFERENCES

1. Dreno B, Amici JM, Basset-Seguín N, Cribier B, Claudel JP, Richard MA, et al. Management of actinic keratosis: a practical report and treatment algorithm from AKTeam expert clinicians. *J Eur Acad Dermatol Venereol* 2014; 28: 1141–1149.
2. Chetty P, Choi F, Mitchell T. Primary care review of actinic keratosis and its therapeutic options: a global perspective. *Dermatol Ther* 2015; 5: 19–35.
3. Malvey J. A new vision of actinic keratosis beyond visible clinical lesions. *J Eur Acad Dermatol Venereol* 2015; 29 Suppl 1: 3–8.
4. Werner RN, Stockfleth E, Connolly SM, Correia O, Erdmann R, Foley P, et al. Evidence- and consensus-based (S3) Guidelines for the Treatment of Actinic Keratosis – International League of Dermatological Societies in cooperation with the European Dermatology Forum – short version. *J Eur Acad Dermatol Venereol* 2015; 29: 2069–2079.
5. Ulrich M, Reinhold U, Skov T, Elvang Sondergaard R, Guitera P. Histological examination confirms clinical clearance of actinic keratoses following treatment with ingenol mebutate 0.05% gel. *Br J Dermatol* 2017; 176: 71–80.
6. Berman B, Goldenberg G, Hanke CW, Tyring SK, Werschler WP, Knudsen KM, et al. Efficacy and safety of ingenol mebutate 0.015% gel after cryosurgery of actinic keratosis: 12-month results. *J Drugs Dermatol* 2014; 13: 741–747.
7. Hofbauer G, Anliker M, Boehncke WH, Brand C, Braun R, Gaide O, et al. Swiss clinical practice guidelines on field cancerization of the skin. *Swiss Med Wkly* 2014; 144:w14026.
8. Peris K, Calzavara-Pinton PG, Neri L, Girolomoni G, Malara G, Parodi A, et al. Italian expert consensus for the management of actinic keratosis in immunocompetent patients. *J Eur Acad Dermatol Venereol* 2016; 30: 1077–1084.
9. Olsen EA, Abernethy ML, Kulp-Shorten C, Callen JP, Glazer SD, Huntley A, et al. A double-blind, vehicle-controlled study evaluating masoprocol cream in the treatment of actinic keratoses on the head and neck. *J Am Acad Dermatol* 1991; 24: 738–743.
10. Roewert-Huber J, Stockfleth E, Kerl H. Pathology and pathobiology of actinic (solar) keratosis – an update. *Br J Dermatol* 2007; 157 Suppl 2: 18–20.

11. Rowert-Huber J, Patel MJ, Forschner T, Ulrich C, Eberle J, Kerl H, et al. Actinic keratosis is an early in situ squamous cell carcinoma: a proposal for reclassification. *Br J Dermatol* 2007;156 Suppl 3:8–12.
12. Lee KC, Lew R, Weinstock MA. Improvement in precision of counting actinic keratoses. *Br J Dermatol* 2014; 170: 188–191.
13. Epstein E. Quantifying actinic keratosis: assessing the evidence. *Am J Clin Dermatol* 2004; 5: 141–144.
14. Weinstock MA, Bingham SF, Cole GW, Eilers D, Naylor MF, Kalivas J, et al. Reliability of counting actinic keratoses before and after brief consensus discussion: the VA topical tretinoin chemoprevention (VATTC) trial. *Arch Dermatol* 2001; 137: 1055–1058.
15. Schmitz L, Kahl P, Majores M, Bierhoff E, Stockfleth E, Dirschka T. Actinic keratosis: correlation between clinical and histological classification systems. *J Eur Acad Dermatol Venereol* 2016; 30: 1303–1307.
16. Bower C, Keohane S, Kownacki S, Moncrieff G, Morton C, Peace J, et al, for the Primary Care Dermatology Society (PCDS). Actinic (Solar) Keratosis – Primary Care Treatment Pathway 2014. Available from: http://www.pcds.org.uk/ee/images/uploads/general/AK_guidelines_2014_final_aw2.pdf.
17. Cohen J. A coefficient of agreement for nominal scales. *Educational and Psychological Measurement*. *Educ Psychol Meas* 1960; 20: 37–46.
18. Landis JR, Koch GG. The measurement of observer agreement for categorical data. *Biometrics* 1977; 33: 159–174.
19. Fleiss JL. *Statistical methods for rates and proportions*. 1st edn. New York: John Wiley & Sons; 1981.
20. Armstrong AW, Parsi K, Schupp CW, Mease PJ, Duffin KC. Standardizing training for psoriasis measures: effectiveness of an online training video on Psoriasis Area and Severity Index assessment by physician and patient raters. *JAMA Dermatol* 2013; 149: 577–582.
21. Szeimies RM, Dirschka T, Prechtel A, Melzer A. Efficacy of low-dose 5-fluorouracil/salicylic acid in actinic keratoses in relation to treatment duration. *J Dtsch Dermatol Ges* 2015; 13: 430–438.
22. Lebwohl M, Swanson N, Anderson LL, Melgaard A, Xu Z, Berman B. Ingenol mebutate gel for actinic keratosis. *N Engl J Med* 2012; 366: 1010–1019.
23. Lebwohl M, Dinehart S, Whiting D, Lee PK, Tawfik N, Jorizzo J, et al. Imiquimod 5% cream for the treatment of actinic keratosis: results from two phase III, randomized, double-blind, parallel group, vehicle-controlled trials. *J Am Acad Dermatol* 2004; 50: 714–721.
24. Dirschka T, Gupta G, Micali G, Stockfleth E, Basset-Seguín N, Del Marmol V, et al. Real-world approach to actinic keratosis management: practical treatment algorithm for office-based dermatology. *J Dermatolog Treat* 2016 Nov 13. [Epub ahead of print].
25. Ratushny V, Gober MD, Hick R, Ridky TW, Seykora JT. From keratinocyte to cancer: the pathogenesis and modeling of cutaneous squamous cell carcinoma. *J Clin Invest* 2012; 122: 464–472.
26. Heerfordt IM, Nissen CV, Poulsen T, Philipsen PA, Wulf HC. Thickness of actinic keratosis does not predict dysplasia severity or P53 expression. *Sci Rep* 2016; 6: 33952.
27. Moy RL. Clinical presentation of actinic keratoses and squamous cell carcinoma. *J Am Acad Dermatol* 2000; 42: 8–10.
28. Guenther ST, Hurwitz RM, Buckel LJ, Gray HR. Cutaneous squamous cell carcinomas consistently show histologic evidence of in situ changes: a clinicopathologic correlation. *J Am Acad Dermatol* 1999; 41: 443–448.
29. de Berker D, McGregor JM, Hughes BR, British Association of Dermatologists Therapy Guidelines and Audit Subcommittee. Guidelines for the management of actinic keratoses. *Br J Dermatol* 2007; 156: 222–230.
30. Piccoli MF, Amorim BD, Wagner HM, Nunes DH. Teledermatology protocol for screening of skin cancer. *An Bras Dermatol* 2015; 90: 202–210.