

Multiple, Fine, Firm Keratotic Papules on the Palms: A Quiz

Aline SCHÖLLER and Cyrill GÉRAUD*

Department of Dermatology, Venereology and Allergy, University Medical Center and Medical Faculty Mannheim, Heidelberg University, Theodor-Kutzer-Ufer 1–3, DE-68135 Mannheim, Germany. *E-mail: cyrill.geraud@umm.de

A 79-year-old man presented for treatment of a biopsy-proven atypical fibroxanthoma of the scalp. In addition, he had a 34-year history of asymptomatic spiny small skin lesions on both palms. Apart from a slightly rough feeling on the palms he reported no associated symptoms and the family history was negative for similar palmar lesions. His past medical history included hypertension, hyperlipidaemia, coronary artery disease and restless legs syndrome. Besides the erythematous nodule on the scalp, numerous,

firm, yellowish, spiky, keratotic papules, 1–2 mm in height were found on both palms (**Fig. 1** A, B). The soles of his feet and the rest of the body were not affected by similar lesions. A punch biopsy was taken from the left hand (**Fig. 1** C, D). Histology revealed columnar hyperkeratosis with ortho- and parakeratosis with underlying hypogranulosis. Due to the fact that the lesions were asymptomatic the patient refused treatment.

What is your diagnosis? See next page for answer.

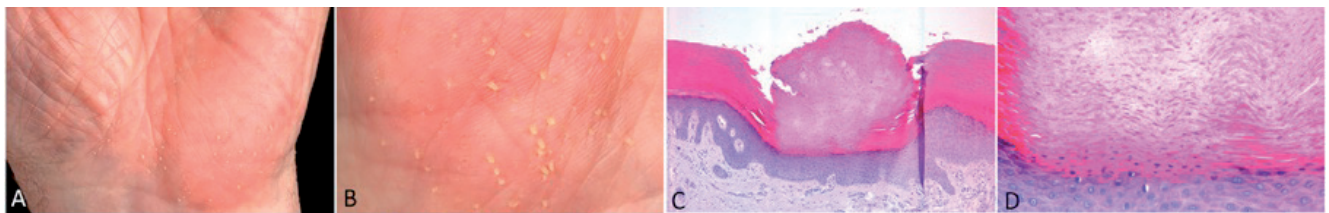


Fig. 1. Clinical and histopathological findings. (A, B) Multiple, fine, firm, yellowish keratotic papules on the left palm. (C, D) Histopathological examination revealed a well-defined column of hyperparakeratosis above a fine granular layer. No dyskeratosis or vacuolization of the underlying epidermal keratinocytes was seen. The surrounding epidermis appeared normal with an unremarkable corneal layer (C: H&E $\times 100$, D: $\times 400$).

ANSWERS TO QUIZ

Multiple, Fine, Firm Keratotic Papules on the Palms: A Commentary

Acta Derm Venereol 2017; 97: 993–994.

Diagnosis: Spiny keratoderma of the palms

Spiny keratoderma of the palms and soles (SKPS) is a rare skin disease that was first described by Brown (1) in 1971 as “punctate keratoderma”. Since then, several terms have been used to describe this dermatosis, such as punctate porokeratotic keratoderma, hyperkeratose palmo-plantaire filiforme and porokeratosis punctata palmaris et plantaris. Osman et al. first coined the designation “spiny keratoderma of the palms and soles” (6). More recently, this term has gained favour because it describes more accurately the clinical and pathological findings.

The aetiology of SKPS remains unclear. Two variants of SKPS can be distinguished; a hereditary and an acquired variant. The hereditary variant is inherited by an autosomal dominant trait and manifests typically between the ages of 12 and 50 years. No other systemic diseases or malignant conditions have been associated with SKPS (2).

The acquired form, which is the diagnosis in our patient, appears mostly after the age of 50 years. Associations with internal and cutaneous malignancy or systemic diseases have been reported in some acquired cases (2). For example, SKPS has been found associated with malignant melanoma (3), rectal carcinoma (4), breast cancer (5), type IV hyperlipoproteinaemia (6) and autosomal dominant polycystic kidney disease with liver cysts (7). In addition, there is an accumulation of SKPS cases observed in patients with a history of manual labour or medication with HMG-CoA reductase inhibitors (6). To our knowledge, the present case is the first report of SKPS associated with an atypical fibroxanthoma. Age-appropriate cancer screenings and regular physical examinations are recommended for early detection of any associated internal or cutaneous disease in patients with the acquired form of SKPS.

The clinical picture of SKPS is pathognomonic. Typically there are multiple, symmetrical, firm, keratotic papules 1–2 mm in height. The lesions can either be limited to the palms or affect the palms and soles. The majority of reported cases have had palmar involvement only. The disease is also called “music box spine dermatosis” due to the clinical appearance of the papules (8).

SKPS is probably under-reported and under-diagnosed because such patients do not seek medical advice since most cases cause minimal discomfort or are asymptomatic. In addition, unfamiliarity with the disease due to its rarity may prevent the proper diagnosis. In some cases clinical symptoms, such as pain, pruritus, a tingling sensation or rough feeling, are observed (6).

Diagnosis of SKPS can be confirmed by histopathology, showing a compact vertical column of parakeratosis above a fine granular layer. In contrast to the cornoid lamellae of porokeratosis, in SKPS dyskeratoses are usually absent below the granular layer. Examination using a Wood’s lamp shows white fluorescence that looks similar to stars under the moonlight (9).

Treatment of SPKS is difficult and not well established. Management involves treatment with 0.05% tretinoin (7), ammonium lactate 12% lotion (7), salicylic acid (6), 0.002% tacalcitol ointment (10) and topical 5-fluorouracil (6). Long-term therapy is needed to prevent relapse with all forms of treatment. Successful therapy has also been reported with the use of acitretin 25–30 mg daily (11). One case report even states that the patient remained clear of skin lesions for at least 18 months after cessation of acitretin (12). Other therapeutic approaches include mechanical debridement, such as dermabrasion or excision of a small number of lesions (6, 8). No spontaneous remissions have been reported.

REFERENCES

1. Brown FC. Punctate keratoderma. Arch Dermatol 1971; 104: 682–683.
2. Baratli J, Amann P, Megahed M. Spiny hyperkeratosis palmaris et plantaris. Hautarzt 2012; 63: 923–926.
3. Kaddu S, Soyer HP, Kerl H. Palmar filiform hyperkeratosis: a new paraneoplastic syndrome? J Am Acad Dermatol 1995; 33: 337–340.
4. Fegueux S, Bilet S, Crickx B, Perron J, Grossin M, Belaïch S. Hyperkeratose palmo-plantaire filiforme et cancer rectosigmoïdien. Ann Dermatol Venereol 1988; 115: 1145–1146.
5. Hillion B, Le Bozec P, Moulouquet-Michau I, Blanchet-Bardon C, Petit A, Stephan J, et al. Hyperkeratose palmo-plantaire filiforme et cancer du sein. Ann Dermatol Venereol 1990; 117: 834–836.
6. Horton SL, Hashimoto K, Toi Y, Miner JE, Mehregan D, Fligiell A, et al. Spiny keratoderma: a common under-reported dermatosis. J Dermatol 1998; 25: 353–361.
7. Anderson D, Cohen DE, Lee HS, Thellman C. Spiny keratoderma in association with autosomal dominant polycystic kidney disease with liver cysts. J Am Acad Dermatol 1996; 34: 935–936.
8. Torres G, Behshad R, Han A, Castrovinci AJ, Gilliam AC. “I forgot to shave my hands”: A case of spiny keratoderma. J Am Acad Dermatol 2008; 58: 344–348.
9. Erkek E, Atasoy P. Fluorescence of hereditary type II punctate porokeratotic keratoderma (spiny keratoderma) with a Wood’s light: stars under the moonlight. J Am Acad Dermatol 2007; 57: 63–64.
10. Yukawa M, Satoh T, Higuchi T, Yokozeki H. Spiny keratoderma of the palms successfully treated with topical tacalcitol. Acta Derm Venereol 2007; 87: 172–174.
11. Mehta RK, Mallett RB, Green C, Rytina E. Palmar filiform hyperkeratosis (FH) associated with underlying pathology? Clin Exp Dermatol 2002; 27: 216–219.
12. Scott-Lang VE, McKay DA. Spiny keratoderma successfully treated with acitretin. Clin Exp Dermatol 2013; 38: 91–92.