

Fungal Melanonychia: Ungual Phaeohyphomycosis caused by *Botryosphaeria dothidea*

Hiromitsu NOGUCHI^{1,2}, Masataro HIRUMA², Tadahiko MATSUMOTO², Rui KANO³, Masaru TANAKA⁴, Takashi YAGUCHI⁵, Kazuhiro SONODA⁶ and Hironobu IHN⁷

¹Noguchi Dermatology Clinic, 1834-1 Namazu, Kashima-machi, Kamimashiki-gun, Kumamoto 861-3101, ²Ochanomizu Institute for Medical Mycology and Allergology, Tokyo, ³Department of Pathobiology, Nihon University School of Veterinary Medicine, Kanagawa, ⁴Department of Dermatology, Tokyo Women's Medical University Medical Center East, Tokyo, ⁵Division of Bio-resources, Medical Mycology Research Center, Chiba University, Chiba, ⁶Division of Internal Medicine, Yatsuda Hospital, Kumamoto, and ⁷Department of Dermatology and Plastic Surgery, Faculty of Life Sciences, Kumamoto University, Kumamoto, Japan. E-mail: derma@nogcli.jp

Accepted Mar 15, 2017; Epub ahead of print Mar 15, 2017

The phaeoid fungus *Neoscytalidium dimidiatum* and a dermatophyte *Trichophyton rubrum* are the most frequently isolated agents causing fungal melanonychia, followed by the phaeoid fungi of the genera *Alternaria* and *Exophiala* (1, 2). Phaeohyphomycosis is an umbrella term describing infections in humans and other animals characterized primarily by the development of dark-coloured hyphae that are caused by phaeoid fungi. The term “phaeohyphomycosis” encompasses broad mycotic infections, regardless of the site of the lesion; the pattern of tissue response, granuloma, or abscess; or the taxonomy of the aetiological agents (3). We describe here a classic example of unguinal phaeohyphomycosis.

CASE REPORT

An 82-year-old retired Japanese farmer with chronic heart failure and hemiparesis noticed a black-pigmented area on his right thumbnail that had been present for 6 months. His internist (KS) considered the possibility of malignant melanoma. Upon presentation in February 2016, the nail was thickened and rough with a greyish-white surface, and black pigmentation was observed from its centre to the proximal side. Hutchinson's sign was not observed (Fig. 1a). The discoloured area accounted for 91% of the entire nail plate (Image J version 1.48; National Institutes of Health, Bethesda, MD, USA). Dermoscopy (Handyscope connected to an iPhone 6, FotoFinder, Bad Bimbach, Germany) revealed that the distal three-fifths of the nail plate showed a whitish scaly area with random reflection and intermingling irregular black dots, while the proximal one-fifth showed a normal nail plate. Between these

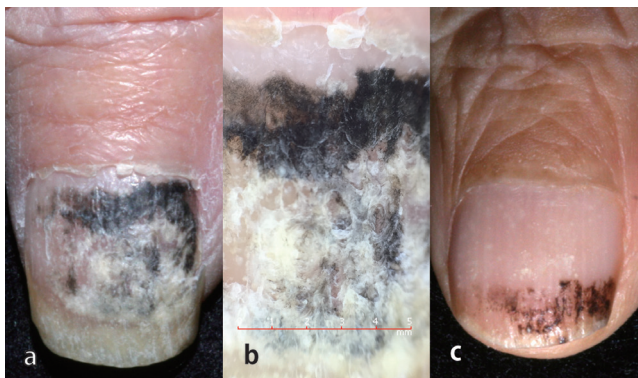


Fig. 1. Clinical characteristics of the thumb nail. (a) Clinical image at presentation. Melanonychia without Hutchinson's sign. (b) Dermoscopic image showing a black homogenous area and coarse granules proximally. (c) Findings after 4 months of topical application of 10% efinaconazole solution. The opacity ratio decreased from 91% to 32% during that time.

2 areas, a black homogenous area and a partially grey granular area were observed (Fig. 1b).

Direct microscopy revealed branching brown septate hyphae (Fig. 2a), and haematoxylin and eosin and periodic acid-Schiff staining revealed black septate hyphae in the nail plate. The thick cell wall appeared to be double contoured (Fig. 2b). Plate culture on potato dextrose agar after 7 days at 30°C showed a greyish-white woolly colony with coal-black pigmentation on the reverse (Fig. 2c, d). Slide culture showed pigmented broad and unpigmented narrow branching hyphae and intercalary and acropetal chlamydoconidia measuring up to 40 µm (Fig. 2e). The sequence of the internal transcribed spacer 1 region of the ribosomal RNA gene from the nail and isolate had 99% homology to the *Botryosphaeria dothidea* type strain CBS 115476 (accession: KF766151) (4). Based on the morphological characteristics and gene analysis results, we diagnosed the patient with unguinal phaeohyphomycosis due to *B. dothidea* (Moug. ex Fr.) Ces. & De Not. The minimum inhibitory concentrations for the isolate were as follows: amphotericin B, 0.25 µg/ml; efinaconazole (EFCZ), 1.0 µg/ml; fluconazole, > 64 µg/ml; 5-fluorocytosine, 2 µg/ml; itraconazole, > 16 µg/ml; micafungin, 0.25 µg/ml; miconazole, 0.25 µg/ml; terbinafine, 0.5 µg/ml; and voriconazole, 0.03 µg/ml. Nail opacity was reduced to 74% and 32% of the nail surface after 1 and 4 months, respectively, of topical application of 10% EFCZ solution (Fig. 1c). The discoloration disappeared with negative conversion of the fungi after 7 months. The patient showed no recurrence of fungal infection during a 3-month follow-up, as of December 2016.

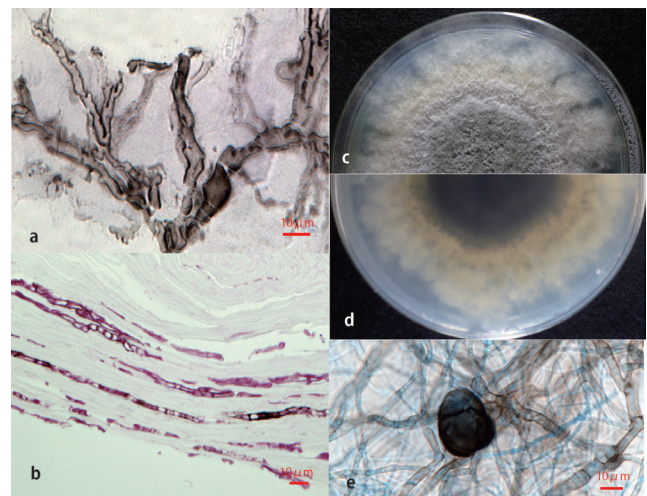


Fig. 2. Mycologic characteristics. (a) Direct microscopic examination revealed branching black hyphae (KOH preparation, original magnification ×400). (b) Septate black hyphae in the nail plate (periodic acid-Schiff staining ×400). (c, d) Plate culture showed a greyish-white woolly colony with a coal-black pigmentation on the reverse. (e) Slide culture showed pigmented broad and unpigmented narrow hyphae and chlamydoconidia. (Lactophenol Cotton Blue staining ×400).

DISCUSSION

Botryosphaeria dothidea was first described as *Sphaeria dothidea* Moug. in 1823. The type species of the genus (family Botryosphaeriaceae, order Botryosphaeriales, class Dothideomycetes, phylum Ascomycota) is *B. dothidea*. Fungi in the order Botryosphaeriales are the most widespread and important plant-pathogens associated with twig, branch, and stem cankers; tip and branch dieback; fruit rot; blue stain; and plant death (5). To date there have been no reports of *B. dothidea* infection in humans or lower animals, while *N. dimidiatum* is the most frequent non-dermatophyte and non-*Candida* pathogen causing onychomycosis in tropical and subtropical regions (6). A survey in Brazil showed that the typical symptom associated with onychomycosis caused by *N. dimidiatum* was a lateral-distal and lateral-subungual lesion in the big toenail, and melanonychia accounted for 66.6% (20/30) of all cases. It developed in 27.2% (3/11) of Caucasians and 89.4% (17/19) of non-Caucasian individuals (7). The sequence of the internal transcribed spacer 1 region of the ribosomal RNA gene from the isolate and the nail in our case had 95% homology with the *N. dimidiatum* type strain CBS 499.66 (accession: FM211432) (4). Our case occurred on the Kyushu island of Japan, which is located in the temperate region at 32° north latitude with a mean temperature of 17.2 ± 0.5°C. The annual mean temperature in the Northern hemisphere has increased by 0.85°C during the past 30 years (1983–2012) (8). The incidence of *B. dothidea* infections might therefore increase gradually even in temperate regions.

Although pigment cells exist in both the nailbed and the nail matrix, melanoma derived from the nailbed has an amelanotic tendency. It is important to differentiate melanonychia arising in the proximal part of the nail from malignant melanoma even if Hutchinson's sign is not noted (9). The characteristic dermoscopic images of fungal melanonychia are homogeneous pigmented coarse granular lesions with fine black granules of a diameter of 0.1 mm or less (9), which were useful for ruling out a diagnosis of malignant melanoma. The clinical appearances of longitudinal melanonychia were similar to those caused by *Phialophora* species (10) and were different from those caused by *T. rubrum* presenting bundle-forming longitudinal lines with a brownish or yellow element (11).

Because onychomycosis caused by *N. dimidiatum* is refractory and resistant to itraconazole and terbinafine (6), the conventional therapy was expected to be ineffective against *B. dothidea* infection. In this case, topical application of 10% EFCZ solution was effective. EFCZ is a novel triazole antifungal agent that has good human nail permeability and retention properties (12, 13). Because of its broad spectrum of antifungal activities (14), EFCZ is a promising option in the treatment of

non-dermatophyte onychomycosis including unguinal phaeoophomycosis (15).

ACKNOWLEDGEMENTS

This research was partially supported by the Research Program on Emerging and Re-emerging Infectious Diseases from the Japan Agency for Medical Research and Development, MAED.

The authors declare no conflicts of interest.

REFERENCES

1. Finch J, Arenas R, Baran R. Fungal melanonychia. *J Am Acad Dermatol* 2012; 66: 830–841.
2. Matsumoto T, Matsuda T, Padhye AA, Standard PG, Ajello L. Fungal melanonychia: unguinal phaeoophomycosis caused by *Wangiella dermatitidis*. *Clin Exp Dermatol* 1992; 17: 83–86.
3. Matsumoto T, Cooper CR, Szaniszló PJ. Chromoblastomycosis and Phaeoophomycosis. In: Guerrant RL, MD, Walker DH, Weller PF, editors. *Tropical infectious diseases*, 3rd edn. Edinburgh: Saunders Elsevier; 2011: p. 569–572.
4. Phillips AJ, Alves A, Abdollahzadeh J, Slippers B, Wingfield MJ, Groenewald JZ, Crous PW. The Botryosphaeriaceae: genera and species known from culture. *Stud Mycol* 2013; 76: 151–167.
5. Marsberg A, Kemler M, Jami F, Nagel JH, Postma-Smidt A, Naidoo S, et al. *Botryosphaeria dothidea*: A latent pathogen of global importance to woody plant health. *Mol Plant Pathol* 2016 Sep 28. [Epub ahead of print].
6. Hay RJ, Ashbee HR. Fungal infections. In: Griffiths C, Barker J, Bleiker T, Chalmers R, Creamer D, editors. *Rook's textbook of dermatology*, 9th edn. Oxford: John Wiley & Sons Ltd; 2016: p. 32. 1–96.
7. Cursi IB, Freitas LB, Neves Mde L, Silva IC. Onychomycosis due to *Scytalidium* spp.: a clinical and epidemiologic study at a University Hospital in Rio de Janeiro, Brazil. *An Bras Dermatol* 2011; 86: 689–693.
8. Intergovernmental Panel on Climate Change (IPCC). Summary for policymakers. In: Stocker TF, Qin D, Plattner G-K, Tignor M, Allen SK, Boschung J, et al., editors. *Climate change 2013: the physical science basis*. Cambridge and NY: Cambridge University Press; 2013: p 1–6.
9. Kilinc Karaarslan I, Acar A, Aytimur D, Akalin T, Ozdemir F. Dermoscopic features in fungal melanonychia. *Clin Exp Dermatol* 2015; 40: 271–278.
10. de Carvalho L, Mendonça I, de Oliveira JC, Val A, Hering B, Stallone C, Jimenez PA. [Melanonychia: Concerning a case of nail bed melanocyte mimicking a melanoma.] *Dermatol Online J* 2010; 16: 6 (in Portuguese).
11. Finch J, Arenas R, Baran R. Fungal melanonychia. *J Am Acad Dermatol* 2012; 66: 830–841.
12. Sugiura K, Sugimoto N, Hosaka S, Katafuchi-Nagashima M, Arakawa Y, Tatsumi Y, et al. The low keratin affinity of efinaconazole contributes to its nail penetration and fungicidal activity in topical onychomycosis treatment. *Antimicrob Agents Chemother* 2014; 58: 3837–3842.
13. Sakamoto M, Sugimoto N, Kawabata H, Yamakawa E, Kodera N, Pillai R, Tatsumi Y. Transungual delivery of efinaconazole: its deposition in the nail of onychomycosis patients and in vitro fungicidal activity in human nails. *J Drugs Dermatol* 2014; 13: 1388–1342.
14. Jo Siu WJ, Tatsumi Y, Senda H, Pillai R, Nakamura T, Sone D, Fothergill A. Comparison of in vitro antifungal activities of efinaconazole and currently available antifungal agents against a variety of pathogenic fungi associated with onychomycosis. *Antimicrob Agents Chemother* 2013; 57: 1610–1616.
15. Noguchi H, Hiruma M, Matsumoto T, Kano R, Ihn H. Unguinal aspergilliosis successfully treated with topical efinaconazole. *J Dermatol* 2016 Aug 11 [Epub ahead of print].