

Lupus Miliaris Disseminatus Faciei: Not Only a Facial Dermatosi

Marthe-Lisa SCHAARSCHMIDT¹, Michèle SCHLICH², Janina STAUB³, Astrid SCHMIEDER¹, Sergij GOERDT¹ and Wiebke K. PEITSCH^{4*}

¹Department of Dermatology, Venereology and Allergology, University Medical Center Mannheim, Heidelberg University, Mannheim, ²Dermatological Practice Dr. Krekel, Speyer, ³Department of Dermatology and Venereology, University Medical Center, Hamburg-Eppendorf, and ⁴Department of Dermatology and Phlebology, Vivantes Klinikum im Friedrichshain, Landsberger Allee 49, DE-10249 Berlin, Germany.

*E-mail: wiebke.ludwig-peitsch@vivantes.de

Accepted Jan 24, 2017; Epub ahead of print Jan 25, 2017

Lupus miliaris disseminatus faciei (LMDF), synonymously termed acne agminata (1), is an uncommon granulomatous inflammatory disease usually affecting the central face and the eyelids (1–3). Rare extrafacial manifestations have been reported (1, 3–7). We present here a case of LMDF with involvement of the face, scalp and axillae and provide a summary on the characteristics of the disease and treatment options.

CASE REPORT

A 28-year-old man presented with a 3-month history of asymptomatic papules, nodules and pustules, which had initially appeared on his eyelids and in the axillae and subsequently spread over his face. Treatment with different topical agents, including antibiotics, nystatin, aciclovir and glucocorticoids, as well as oral doxycycline and oral valaciclovir, had been ineffective. The patient had no systemic symptoms or concomitant diseases and did not take any medications. He did not have any history of acne or rosacea, and denied use of aluminium-containing antiperspirants. Clinical examination showed multiple distinct red-brown, sometimes yellowish, papules and nodules, sized 2–10 mm, on the scalp, forehead, glabella, upper and lower eyelids, cheeks and chin (Fig. 1a) as well as in both axillae (Fig. 1b) with a light brown-yellowish infiltrate on diascopy. Diffuse erythema and telangiectasia were absent. Histopathological examination revealed dermal epithelioid cell granulomas with central caseating necrosis (Fig. 1c, d). Microscopy for pathogens with periodic acid–Schiff (PAS), Grocott and Ziehl–Neelsen stains, as well as cultures for *Mycobacterium tuberculosis* and atypical mycobacteria were negative. A bacterial swab yielded

Pseudomonas aeruginosa. Laboratory examinations including serum levels of angiotensin-converting enzyme and tuberculosis test with interferon gamma release assay (QuantiFERON-TB test, QIAGEN, Hilden, Germany) were unremarkable. Based on clinical and histopathological findings a diagnosis of LMDF with axillary involvement was established. Compatible with the results of antimicrobial susceptibility testing, a treatment attempt was made with ciprofloxacin 500 mg twice daily for 2 weeks, but without success. Subsequently isotretinoin 30 mg/day (0.4 mg/kg) was initiated and continued for one year with regular laboratory monitoring. This resulted in clearing of the lesions on the face and scalp with some residual scars, but the axillary lesions remained.

DISCUSSION

LMDF usually affects young adults of both sexes, but it has also been reported in children (8) and elderly patients (9, 10). It typically presents with yellowish-brown dome-shaped papules and pustules localized in the central face, commonly involving the eyelids (1–3). Moreover, extrafacial lesions in the axillae, scalp, trunk, genitalia, neck, hands and legs have been described (1, 3, 4, 6, 7) or, rarely, as the only manifestation of LMDF (4, 5). To make allowance for lesions in non-facial sites Nemer & McGirt recently suggested renaming LMDF “lupus miliaris disseminatus” (6).

The papules have a yellowish-brown (“apple-jelly”) infiltrate on diascopy. On histopathological examination

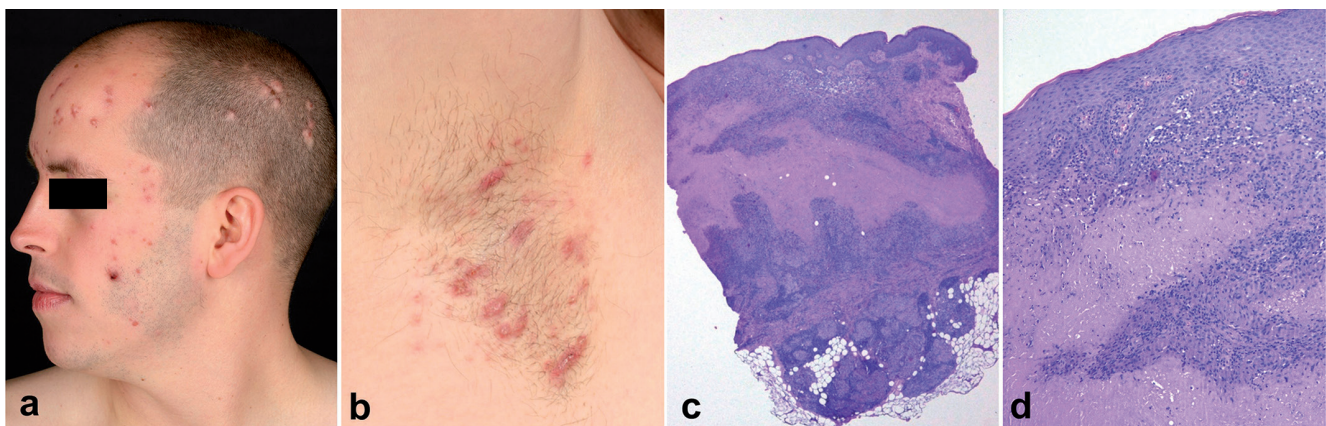


Fig. 1. Clinical and histopathological findings. (a, b) Multiple red-brown and yellowish papules and nodules in the face, on the scalp and in the axilla. (c, d) Haematoxylin-eosin stained skin biopsy specimen from the face showing dermal epithelioid cell granulomas with central areas of caseating necrosis. Magnification: (c, survey) $\times 20$ or (d, detail) $\times 100$. A biopsy from the axilla yielded identical findings. Written permission is given to publish these photographs.

they are characterized by a superficial granulomatous inflammation and perifollicular epithelioid cell granulomas with central necrosis, but findings are dependent on the stage of the disease (11). The aetiology and pathogenesis of LMDF remain unclear. It has been considered to be a form of cutaneous tuberculosis, tuberculoid or sarcoidosis, but work-ups for these diseases performed in several case series did not support any associations (9, 11, 12), and neither does our case. Furthermore, *Propionibacterium acnes* (13) and *Demodex folliculorum* were thought to play a role in the pathogenesis of LMDF, and it was speculated to be a variant of granulomatous rosacea (2, 14). Indeed, LMDF shares similarities with granulomatous rosacea, but it typically occurs at a younger age. Furthermore, it can be distinguished from granulomatous rosacea by lack of erythema and telangiectasia and by the presence of caseating necrosis within the granulomas (3). In order to clearly differentiate LMDF from other conditions Skowron et al. (9) suggested designating it “facial idiopathic granulomas with regressive evolution (FIGURE)”.

After a sudden onset and a chronic course over several months or years LMDF often heals spontaneously (7, 12). However, treatment is required to prevent scarring and to reduce the duration of this sometimes disfiguring disease (2). Standard treatment recommendations and controlled trials are lacking. Topical steroids are known to be ineffective. Several other approaches, including intralesional or systemic corticosteroids, topical tacrolimus, tetracyclines, metronidazole, erythromycin, dapsone, anti-tuberculous antibiotics, isotretinoin, chloroquine and clofazimine, have been attempted, with variable results (3, 4, 6–8, 10, 11). Combination regimens of oral antibiotics and topical tacrolimus were efficient in some cases (5, 8). In addition, there are reports of successful laser therapy of the lesions and scars with 1,565-nm non-ablative fractionated laser (15), 1,450-nm diode laser or carbon dioxide laser. The papules and pustules on the face and scalp of our patient resolved upon treatment with isotretinoin; however, clearance of the axillary lesions was not achieved. The patient did not desire further treatment and wanted to await the spontaneous course.

ACKNOWLEDGEMENT

The patient is acknowledged for permission to share his case and photographs.

Conflicts of interest. M-LS conducted clinical trials for Abbvie, Eli Lilly, Merck, Novartis, Boehringer Ingelheim and UCB Pharma, obtained honoraria from Janssen-Cilag, and received financial support for participation in conferences from Abbvie, ALK-Abello, Biogen Inc., Janssen-Cilag and MSD. MS received financial support for participation in a conference from Meda. JS has no conflicts of interest to declare. AS performed clinical trials for Abbvie, Boehringer Ingelheim, Celgene, MSD, Novartis, Eli Lilly and Pfizer, received honoraria from Janssen-Cilag and Novartis,

and support for participation in conferences from Abbvie, Celgene, Janssen-Cilag, Novartis and Pfizer. SG obtained honoraria as Editor-in-Chief of the Journal of the German Dermatological Society (JDDG) and support for conferences from Abbvie, ALK-Abello, Alma Lasers, ARC Lasers, Asclepion, BMS, Dermasence, Eli Lilly, GSK, Interlac, Janssen-Cilag, L’Oreal, La Roche Posay, LEO Pharma, Medac, Merck, MSD, Novartis, P&M Cosmetics, Pfizer, Roche and Stiefel. WKP served as investigator for Abbvie, Boehringer Ingelheim, Eli Lilly, Janssen-Cilag, Merck, Novartis, Pfizer and UCB Pharma, was member of an advisory board of Abbvie, Eli Lilly, LEO Pharma, MSD and Novartis, obtained honoraria from ALK-Abello, Abbvie, Janssen-Cilag, MSD, Novartis and Roche and received support for conferences from Abbvie, ALK-Abello, Alma Lasers, ARC Lasers, Asclepion, BMS, Celgene, Dermasence, Eli Lilly, GSK, Interlac, Janssen-Cilag, L’Oreal, La Roche Posay, LEO Pharma, Medac, Merck, MSD, Novartis, P&M Cosmetics, Pfizer, Roche and Stiefel. None of the conflicts of interest reported is relevant for the content of this manuscript.

REFERENCES

- Hillen U, Schröter S, Denisjuk N, Jansen T, Grabbe S. Axillary acne agminata (lupus miliaris disseminatus faciei with axillary involvement). *J Dtsch Dermatol Ges* 2006; 4: 858–860.
- Shitara A. Lupus miliaris disseminatus faciei. *Int J Dermatol* 1984; 23: 542–544.
- van de Scheur MR, van der Waal RI, Starink TM. Lupus miliaris disseminatus faciei: a distinctive rosacea-like syndrome and not a granulomatous form of rosacea. *Dermatology* 2003; 206: 120–123.
- Bedlow AJ, Otter M, Marsden RA. Axillary acne agminata (lupus miliaris disseminatus faciei). *Clin Exp Dermatol* 1998; 23: 125–128.
- Kim WB, Mistry N. Lupus miliaris disseminatus faciei with isolated axillary involvement. *J Cutan Med Surg* 2016; 20: 153–154.
- Nemer KM, McGirt LY. Extrafacial lupus miliaris disseminatus. *JAAD Case Rep* 2016; 2: 363–365.
- Al-Mutairi N. Nosology and therapeutic options for lupus miliaris disseminatus faciei. *J Dermatol* 2011; 38: 864–873.
- Misago N, Nakafusa J, Narisawa Y. Childhood granulomatous periorificial dermatitis: lupus miliaris disseminatus faciei in children? *J Eur Acad Dermatol Venereol* 2005; 19: 470–473.
- Skowron F, Causeret AS, Pabion C, Viallard AM, Balme B, Thomas L. F.I.G.U.R.E.: facial idiopathic granulomas with regressive evolution. is ‘lupus miliaris disseminatus faciei’ still an acceptable diagnosis in the third millennium? *Dermatology* 2000; 201: 287–289.
- Dekio S, Jidoi J, Imaoka C. Lupus miliaris disseminatus faciei – report of a case in an elderly woman. *Clin Exp Dermatol* 1991; 16: 295–296.
- Hodak E, Trattner A, Feuerman H, Feinmesser M, Tsvieli R, Mitrani-Rosenbaum S, David M. Lupus miliaris disseminatus faciei – the DNA of *Mycobacterium tuberculosis* is not detectable in active lesions by polymerase chain reaction. *Br J Dermatol* 1997; 137: 614–619.
- Nino M, Barberio E, Delfino M. Lupus miliaris disseminatus faciei and its debated link to tuberculosis. *J Eur Acad Dermatol Venereol* 2003; 17: 97.
- Nishimoto J, Amano M, Setoyama M. The detection of *Propionibacterium acnes* signatures in granulomas of lupus miliaris disseminatus faciei. *J Dermatol* 2015; 42: 418–421.
- Helm KF, Menz J, Gibson LE, Dicken CH. A clinical and histopathologic study of granulomatous rosacea. *J Am Acad Dermatol* 1991; 25: 1038–1043.
- Beleznay K, Friedmann DP, Liolios AM, Perry A, Goldman MP. Lupus miliaris disseminatus faciei treated with 1,565 nm nonablative fractionated laser resurfacing: a case report. *Lasers Surg Med* 2014; 46: 663–665.