

Ustekinumab as Effective Treatment for Refractory Amicrobial Pustulosis of the Folds Associated with Crohn's Disease

Reem AL-RADDADI¹, Camille FRANCES^{1,2}, Philippe MOGUELET³, Claude BACHMEYER⁴ and Sarah GUÉGAN^{1,2*}

¹Service de dermatologie-allergologie, ³Service d'anatomie pathologique and ⁴Service de médecine interne, Hôpital Tenon, AP-HP, 4, rue de la Chine, FR-75020 Paris, and ²Université Paris VI, Paris, France. *E-mail: sarah.guegan.bart@gmail.com

Accepted Oct 6, 2016; Epub ahead of print Oct 10, 2016

Amicrobial pustulosis of the folds (APF) is characterized by relapsing pustular lesions associated with erosive macerated areas and crusts, affecting the cutaneous folds, face and scalp (1). It is usually reported in females in the third decade, mainly in association with systemic and cutaneous lupus erythematosus and, rarely, with connective tissue disease, scleroderma, myasthenia gravis, Hashimoto's thyroiditis, idiopathic thrombocytopenia and coeliac disease (1–4).

APF belongs to the spectrum of neutrophilic dermatoses, diseases all characterized by similar pathological features, namely an intense inflammatory infiltrate composed primarily of neutrophils, in the absence of patent infection. In APF, intraepidermal subcorneal spongiform abscesses are associated with a neutrophilic dermal infiltrate. Diagnostic criteria were established by Marzano et al. in 2008 (Table S1¹) (2).

We report here a case of refractory APF, which preceded by 11 years the onset of lupus erythematosus tumidus (LET), and by 15 years the onset of Crohn's disease (CD). Both APF and CD were controlled by ustekinumab, a monoclonal antibody directed against the p40 subunit common to interleukin (IL)12/IL23.

from recent closed pustules were sterile. A diagnosis of APF was thus established.

Of note, 11 years after the onset of APF, the patient presented smooth erythematous infiltrated plaques affecting the face. Histology confirmed LET. Antinuclear antibodies (ANA) were positive, with a titre of 1:320 and a nuclear speckled pattern; search for other autoimmune antibodies (anti-dsDNA, anti-SS-A, anti-SS-B, anti-Sm, anti-RNP, ANCA) was negative. Hydroxychloroquine (200 mg twice daily) combined with a short course of topical corticosteroids was quickly effective in treating LET with no further relapse.

Initially, various courses of treatment failed to control APF: topical and systemic corticosteroids (up to 1.5 mg/kg/day), colchicine (2 mg/day), isotretinoin (40 mg/day), hydroxychloroquine, dapsone (100 mg/day), and zinc (30 mg/day). When necessary, bacterial superinfections were treated with empirical antibiotic therapy. The patient responded partially to a 4-year course of cyclosporine (5 mg/kg/day) with gradual tapering. After 4 years of this treatment, as no complete remission was seen, anakinra (100 mg daily subcutaneously) was introduced and continued for 2 years; a significant decrease in the episodes of flare-ups was noted.

Fifteen years after the onset of APF, the patient experienced persistent weight loss and abdominal pains. Upper and lower gastrointestinal endoscopy and biopsies revealed erosive pancolitis with epithelioid cell granuloma, a diagnostic characteristic of CD. In the months following CD diagnosis, several flares of APF occurred. Anakinra was stopped; ustekinumab was introduced at a dose of 90 mg subcutaneously every 8 weeks and has been on-going for

CASE REPORT

A 26-year-old woman was referred for evaluation of recurrent episodes of pustular skin lesions affecting predominantly her major body folds over the last 10 years. Upon examination, the patient was healthy, afebrile. Axillary, submammary and inguinal folds were involved with multiple symmetrically distributed erythematous pustules. The gluteal folds, perianal area and buttocks were mostly affected (Fig. 1a). Isolated pustules were observed on the arms, back, abdomen and thighs. Nikolsky's sign was negative. In the course of evolution, similar lesions involved the face and scalp, together with erosive and crusted lesions (Fig. 1b). Pustular lesions affecting the scalp eventually coalesced into large plaques with hair loss, quickly followed by regrowth. All of these lesions regressed following topical corticosteroid therapy, and relapsed after withdrawal of treatment. Histology of skin biopsy specimens revealed intraepidermal subcorneal spongiform abscesses as well as a dermal inflammatory infiltrate with predominant neutrophils (Fig. 1c). Direct immunofluorescence of lesional skin showed non-specific IgM deposits at the dermoepidermal junction. Microbiological cultures

¹<https://doi.org/10.2340/00015555-2544>

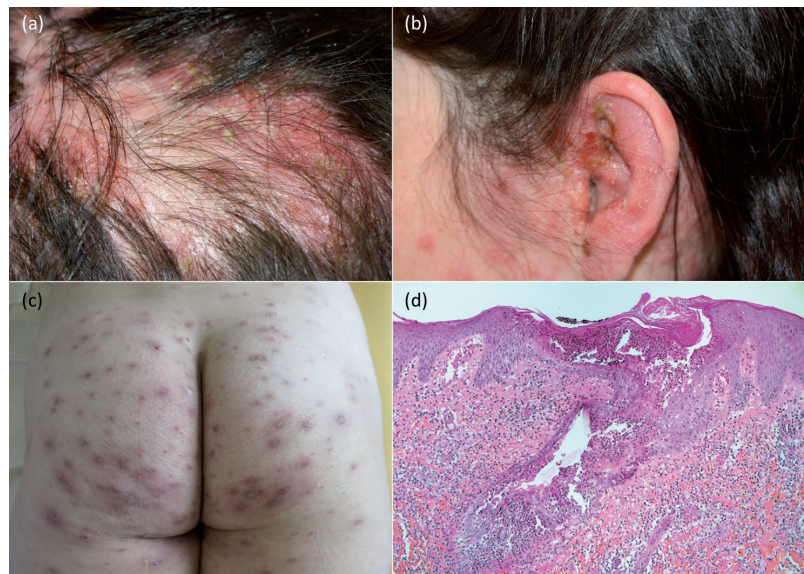


Fig. 1. A case of refractory amicrobial pustulosis of the folds. (a–c) Crusted erythematous pustular lesions of the scalp, ear and buttocks, respectively. (d) Haematoxylin-eosin staining showing spongiform subcorneal epidermal and follicular pustule with a mixed neutrophil and mononuclear infiltrate in the upper and middle dermis (original magnification $\times 200$).

the last 2 years. Ustekinumab was well tolerated with no adverse effects and CD symptoms subsided quickly. APF was controlled by the concomitant use of ustekinumab and cyclosporine within 3 months; 6 months after ustekinumab initiation, secondary adjunction of methotrexate (25 mg/week) allowed cyclosporine tapering. Hydroxychloroquine treatment was never discontinued, and prevented LET relapses.

DISCUSSION

In the case of our patient, obligate criteria for APF were fulfilled. Two minor criteria were also present: association with 2 autoimmune disorders, LET and CD, and positive ANA with a titre of 1:320. Differential diagnoses that could be considered were a pustular variant of disseminated pyoderma gangrenosum (PG) or the vesiculopustular eruption that may accompany inflammatory bowel diseases (IBD). However, the diffuse prolonged and recurrent evolution of the cutaneous symptoms and their preceding CD by 15 years were not in favour of the latter that is milder and not specifically localized in cutaneous folds or scalp. In the 15 years of evolution of skin manifestations, pustules never progressed clinically toward lesions of ulcerative PG, the most frequent form in patients with IBD (5).

APF has been reported in association with coeliac disease (1), but to our knowledge, this is the first case of APF associated with IBD. IBD may be associated with various neutrophilic dermatoses (ND) (6) such as PG, Sweet's syndrome, bowel-associated dermatosis-arthritis syndrome, pyostomatitis vegetans, and extracutaneous aseptic abscesses (7).

Immunomodulatory therapies are the mainstay of treatment of ND, corticosteroids and cyclosporine being the drugs most commonly used. These treatments have also been given in cases of APF (2). In our patient, cyclosporine incompletely prevented flares of the disease during 4 years.

Anti-IL-1 receptor antagonist anakinra is another alternative in cases of refractory ND, such as Sweet's syndrome (8, 9) and neutrophilic panniculitis (10). Amazan et al. (11) reported a dramatic response to anakinra with complete remission in a patient with APF, and indeed, expression of IL-1 β and its receptors I and II is increased in the skin of these patients (12). In our patient, anakinra partially stabilized APF during 2 years with reduction in flare numbers and intensity. It had to be discontinued following CD diagnosis and new flares of APF.

Case reports and placebo-controlled trials have also underlined the relevance of anti-tumour necrosis factor (TNF)- α therapy as a first-line treatment in the case of PG associated with IBD (13). However, TNF- α inhibitors were not considered as a first-line therapy in our patient because of LET. Ustekinumab is a human monoclonal antibody against IL-12 and 23, approved for the treatment of moderate to severe plaque psoriasis and psoriatic arthritis, and effective in inducing and maintaining remission in patients with CD (14). IL-23 plays a critical role

in driving inflammation associated with IL-17 production and especially neutrophil recruitment, and cases of patients with cortico-resistant PG successfully treated with ustekinumab have recently been reported (15, 16). Ustekinumab was used successfully in our patient in association with cyclosporine and, secondarily, methotrexate, which allowed cyclosporine tapering.

Conflicts of interest: SG was supported by Janssen for international and national conference attendance.

REFERENCES

1. Marzano AV, Capsoni F, Berti E, Gasparini G, Bottelli S, Caputo R. Amicrobial pustular dermatosis of cutaneous folds associated with autoimmune disorders: a new entity? *Dermatology* 1996; 193: 88–93.
2. Marzano AV, Ramoni S, Caputo R. Amicrobial pustulosis of the folds. Report of 6 cases and a literature review. *Dermatology* 2008; 216: 305–311.
3. Lagrange S, Chosidow O, Piette JC, Wechsler B, Godeau P, Frances C. A peculiar form of amicrobial pustulosis of the folds associated with systemic lupus erythematosus and other auto-immune diseases. *Lupus* 1997; 6: 514–520.
4. Stefanidou MP, Kanavaros PE, Stefanaki KS, Tosca AD. Amicrobial pustulosis of the folds. A cutaneous manifestation associated with connective tissue disease. *Dermatology* 1998; 197: 394–396.
5. Farhi D, Cosnes J, Zizi N, Chosidow O, Seksik P, Beaugerie L, et al. Significance of erythema nodosum and pyoderma gangrenosum in inflammatory bowel diseases: a cohort study of 2402 patients. *Medicine (Baltimore)* 2008; 87: 281–293.
6. Thrash B, Patel M, Shah KR, Boland CR, Menter A. Cutaneous manifestations of gastrointestinal disease: part II. *J Am Acad Dermatol* 2013; 68: 211.e1–33; quiz 244–246.
7. André MF, Piette JC, Kémény JL, Ninet J, Jégo P, Delèveaux I, et al. Aseptic abscesses: a study of 30 patients with or without inflammatory bowel disease and review of the literature. *Medicine (Baltimore)* 2007; 86: 145–161.
8. Kluger N, Gil-Bistes D, Guillot B, Bessis D. Efficacy of anti-interleukin-1 receptor antagonist anakinra (Kineret®) in a case of refractory Sweet's syndrome. *Dermatology* 2011; 222: 123–127.
9. Delluc A, Limal N, Puéchal X, Francès C, Piette JC, Cacoub P. Efficacy of anakinra, an IL1 receptor antagonist, in refractory Sweet syndrome. *Ann Rheum Dis* 2008; 67: 278–279.
10. Lipsker D, Perrigouard C, Foubert A, Cribier B. Anakinra for difficult-to-treat neutrophilic panniculitis: IL-1 blockade as a promising treatment option for neutrophil-mediated inflammatory skin disease. *Dermatology* 2010; 220: 264–267.
11. Amazan E, Ezzedine K, Mossalayi MD, Taieb A, Boniface K, Seneschal J. Expression of interleukin-1 alpha in amicrobial pustulosis of the skin folds with complete response to anakinra. *J Am Acad Dermatol* 2014; 71: e53–56.
12. Marzano AV, Tavecchio S, Berti E, Gelmetti C, Cugno M. Cytokine and chemokine profile in amicrobial pustulosis of the folds: evidence for autoinflammation. *Medicine (Baltimore)* 2015; 94: e2301.
13. Brooklyn TN, Dunnill MG, Shetty A, Bowden JJ, Williams JD, Griffiths CE, et al. Infliximab for the treatment of pyoderma gangrenosum: a randomised, double blind, placebo controlled trial. *Gut* 2006; 55: 505–509.
14. Sandborn WJ, Gasink C, Gao LL, Blank MA, Johans J, Guzzo C, et al. Ustekinumab induction and maintenance therapy in refractory Crohn's disease. *N Engl J Med* 2012; 367: 1519–1528.
15. Guenova E, Teske A, Fehrenbacher B, Hoerber S, Adamczyk A, Schaller M, et al. Interleukin 23 expression in pyoderma gangrenosum and targeted therapy with ustekinumab. *Arch Dermatol* 2011; 147: 1203–1205.
16. Goldminz AM, Botto NC, Gottlieb AB. Severely recalcitrant pyoderma gangrenosum successfully treated with ustekinumab. *J Am Acad Dermatol* 2012; 67: e237–238.