

Long-term Outcome of Low-concentration Hexyl-5-aminolaevulinate Daylight Photodynamic Therapy for Treatment of Actinic Keratoses

Noora NEITTAANMÄKI^{1,2}, Toni T. KARPPINEN³, Taneli T. TANI⁴, Erna SNELLMAN³ and Mari GRÖNROOS²

Departments of Dermatology and Allergology, ¹Helsinki University Central Hospital, FIN-00029 Helsinki and ²Päijät-Häme Social and Health Care Group, Lahti, ³Department of Dermatology, Tampere University and Tampere University Hospital, Tampere, and ⁴Department of Pathology, Päijät-Häme Social and Health Care Group, Lahti, Finland. E-mail: noora.neittaanmaki@fimnet.fi
Accepted Jun 1, 2016; Epub ahead of print Jun 15, 2016

Daylight photodynamic therapy (DL-PDT), using short-chained 5-aminolaevulinate (5-ALA) ester methylaminolaevulinate (MAL), is an effective and well-tolerated treatment for actinic keratoses (AK) (1). Recently, there has been interest in the novel long-chained 5-ALA ester hexylaminolaevulinate (HAL), which has better skin penetration and can thus be used at low concentrations (2–4). This could be of economic value and reduce side-effects (5). We have reported previously that very low concentrations of HAL can be used with daylight activation (6). The current paper reports the long-term 12-month outcome.

METHODS

The methods are described in detail elsewhere (6). Volunteer patients with symmetrical actinic damage in the head area were recruited and treated in June 2014. AKs were photographed, counted and marked on a plastic sheet, and 2 symmetrical equally graded (6) AKs, one on each treatment side, were biopsied bilaterally before treatment. A chemical sunscreen (P20[®], SPF 20 Riemann & Co. A/S, Hilleroed, Denmark) was applied for 15 min, and the treatment areas were subsequently curettaged. Patients were randomized to receive DL-PDT with 0.2% HAL (Hexvix[®] powder, Photocure ASA, Oslo, Norway in Unguentum M, Allmiral, Madrid, Spain) on one side of the face or scalp and 16% MAL (Metvix, Galderma, Paris, France) on the other, both applied as a 0.025 mm² thick layer (treatment area mm² * 0.25 mg/mm²). Illumination was performed for 2 h outdoors. Follow-up visits, including the mapping of the residual lesions and histological sampling, was conducted by the blinded investigator (MG). The histology (HE staining and p53 expression in average percentage of the 3 high power fields) of the samples was interpreted by a blinded pathologist (TTT). Wilcoxon signed-rank paired test was used for statistical analysis.

RESULTS

Of the 14 patients who completed the pilot trial, 13 were followed up for 12 months. One patient died before the 12-month follow-up due to reasons unrelated to the

study. No residual lesions were treated between the 3- and 12-month follow-ups. Both treatments were nearly painless (visual analogue scale (VAS) ≤ 1). HAL caused milder adverse reactions, as assessed at 1 week (6).

At 12 months HAL DL-PDT resulted in similar sustained lesion clearance compared with MAL (**Fig. 1** and **Table I**). The mean lesion clearance per patient was 67% with HAL and 66% with MAL ($p=1.00$). HAL was as effective as MAL in the treatment of grade I AKs, but a trend for lower clearance of grade II–III AKs was seen (**Fig. 2** and Table I). One patient was excluded from the histological analysis because one biopsied lesion clinically taken as an AK appeared histologically to be seborrhoeic dermatitis. Histological clearance was equal for both photosensitizers (Table I). At 12 months, 42% of the HAL-treated and 50% of the MAL-treated biopsied lesions were completely histologically cleared ($p=0.688$). Compared with baseline, the mean expression of p53 was reduced by 20% in the HAL group and by 51% in the MAL group ($p=0.123$).

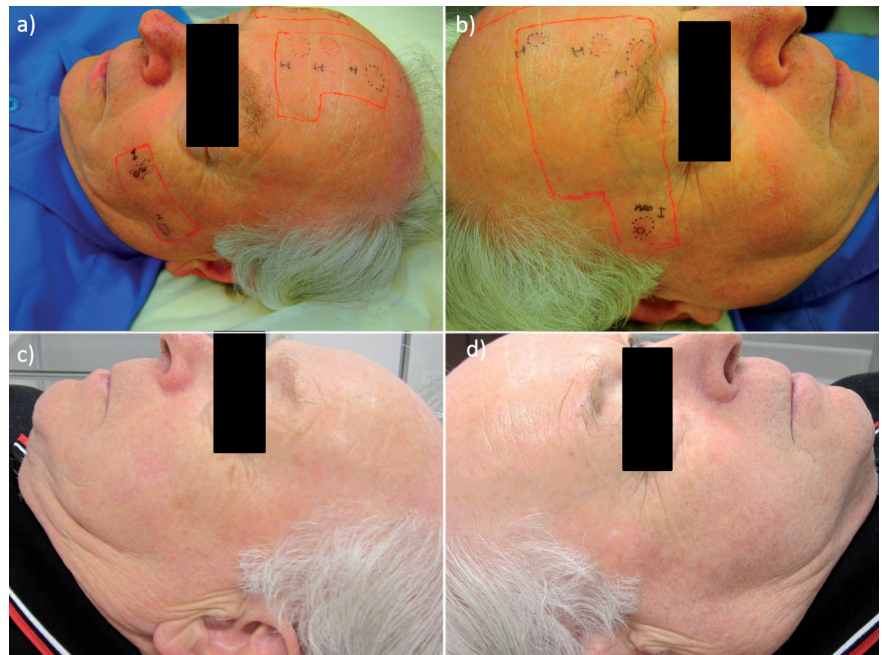


Fig. 1. Complete clearance of actinic keratoses after daylight photodynamic therapy with hexylaminolaevulinate (HAL) (left side, a and c) and with methylaminolaevulinate (MAL) (right side, b and d). (a) and (b) before treatment; (c) and (d) 12 months after treatment.

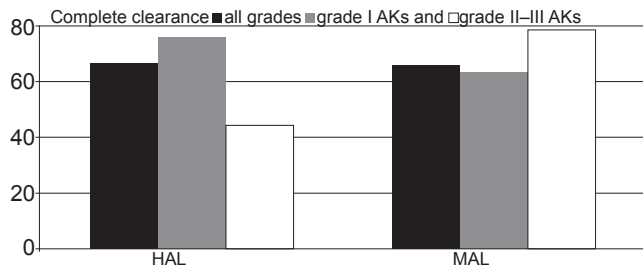


Fig. 2. Mean per patient (half-face) lesion clearance (%) at 12 months. HAL: hexylaminolaevulinate; MAL: methylaminolaevulinate; AK: actinic keratoses.

DISCUSSION

Previously, HAL has been studied at very low 0.1% concentrations for the prevention of cutaneous squamous carcinoma in mice (7). HAL-induced protoporphyrin IX (PpIX) fluorescence has been reported in several studies and it has been shown that HAL has great potential when used at low concentrations (8–11). We reported a 3-month mean per-patient lesion clearance of 73.4% with HAL and 77.8% with MAL (6), which is in concordance with previous DL-PDT studies (1). Long-term clearance is rarely reported in DL-PDT studies. Recently, 62% and 87% mean per-patient lesion clearance was reported for MAL and amino-5-laevulinate nanoemulsion (BF-200 ALA) (12). In our current study at 12 months the clearances were 67% for HAL and 66% for MAL, which supports the previous 12-month data with MAL. Our results show similar efficacies for HAL and MAL in the long-term follow-up.

A limitation of our pilot study was the small sample size. As lower clearance was seen with thicker grade II–III lesions, low-concentration HAL should only be used for thin AKs. The fact that p53 expression was less reduced in the HAL group may indicate poorer reversal in the carcinogenic process. However, over a long period, there was also sustained clearance of AKs in the HAL group.

Table I. Baseline characteristics, clinical and histological clearance rates at 12 months

	HAL	MAL	<i>p</i> -values
<i>Clinical</i>			
Baseline			
Total number of lesions	95	88	0.695
Grade I lesions	71	67	0.711
Grade II–III lesions	24	21	0.625
Lesions/patient, mean (range)	7.3 (3–14)	6.8 (3–10)	
12 months			
Complete response all (mean) % per patient	66.5	65.9	1.000
Grade I	76.2	63.1	0.285
Grade II–III	44.4	78.7	0.156
New lesions	3	1	0.625
<i>Histological</i>			
Baseline biopsied lesions			
Grade I	2	4	0.625
Grade II–III	10	8	0.625
p53, mean (%)	37.6	37.4	0.791
12 months			
Complete response, %	41.6	50	0.688
Mean reduction in p53 expression, %	20	51	0.123

HAL: hexylaminolaevulinate; MAL: methylaminolaevulinate.

Our results show that low concentrations of HAL can be used in the treatment of thin AKs and this clearance was maintained in a long-term follow-up. The use of HAL at very low doses could lead to significant reductions in treatment costs.

ACKNOWLEDGEMENTS

The study has been supported by the Foundation for Clinical Chemistry Research. NN has received travel grants from Biofrontera and Galderma and was speaker honoraria for Biofrontera and Desitin Pharma. The other authors declare no conflict of interest.

Registration no.: R14016M, Ethics Committee Tampere University District. Clinicaltrials.gov registration no.: NCT02149342.

REFERENCES

- Wiegell SR, Wulf HC, Szeimies RM, Basset-Seguin N, Bissonnette R, Gerritsen MJ, et al. Daylight photodynamic therapy for actinic keratosis: an international consensus: International Society for Photodynamic Therapy in Dermatology. *J Eur Acad Dermatol Venereol* 2012; 26: 673–679.
- Peng Q, Berg K, Moan J, Kongshaug M, Nesland JM. 5-Aminolevulinic acid-based photodynamic therapy: principles and experimental research. *Photochem Photobiol* 1997; 65: 235–251.
- De Rosa FS, Tedesco AC, Lopez RF, Pierre MB, Lange N, Marchetti JM, et al. In vitro skin permeation and retention of 5-aminolevulinic acid ester derivatives for photodynamic therapy. *J Control Release* 2003; 89: 261–269.
- Morrow DI, McCarron PA, Woolfson AD, Juzenas P, Juzeniene A, Iani V, et al. Hexyl aminolaevulinate is a more effective topical photosensitizer precursor than methyl aminolaevulinate and 5-aminolaevulinic acids when applied in equimolar doses. *J Pharm Sci* 2010; 99: 3486–3498.
- Neittaanmäki-Perttu N, Neittaanmäki E, Pölonen I, Snellman E, Grönroos M. Safety of novel amino-5-laevulinate photosensitizer precursors in photodynamic therapy for healthy human skin. *Acta Derm Venereol* 2016; 96: 108–110.
- Neittaanmäki-Perttu N, Grönroos M, Karppinen TT, Tani TT, Snellman E. Hexyl-5-aminolaevulinate 0.2% versus methyl-5-aminolaevulinate 16% daylight PDT for treatment of AKs: results of a randomized double-blinded pilot trial. *Br J Dermatol* 2016; 174: 427–429.
- Togsverd-Bo K, Lerche CM, Philipsen PA, Hædersdal M, Wulf HC. Artificial daylight photodynamic therapy with “non-inflammatory” doses of hexyl aminolaevulinate only marginally delays SCC development in UV-exposed hairless mice. *Photochem Photobiol Sci* 2013; 12: 2130–2136.
- Togsverd-Bo K, Lerche CM, Poulsen T, Wulf HC, Haedersdal M. Photodynamic therapy with topical methyl- and hexylaminolevulinic acid for prophylaxis and treatment of UV-induced SCC in hairless mice. *Exp Dermatol* 2010; 19: 166–172.
- Togsverd-Bo K, Idorn LW, Philipsen PA, Wulf HC, Hædersdal M. Protoporphyrin IX formation and photobleaching in different layers of normal human skin: methyl- and hexylaminolevulinic acid and different light sources. *Exp Dermatol* 2012; 21: 745–750.
- Dögnitz N, Salomon D, Zellweger M, Ballini JP, Gabrecht T, Lange N, et al. Comparison of ALA- and ALA hexyl-ester-induced PpIX depth distribution in human skin carcinoma. *J Photochem Photobiol B* 2008; 93: 140–148.
- Juzeniene A, Juzenas P, Ma LW, Iani V, Moan J. Topical application of 5-aminolevulinic acid, methyl 5-aminolaevulinate and hexyl 5-aminolaevulinate on normal human skin. *Br J Dermatol* 2006; 155: 791–799.
- Neittaanmäki-Perttu N, Grönroos M, Tani T, Snellman E. Long-term outcome of daylight photodynamic therapy with 5-aminolaevulinate nanoemulsion and methyl-5-aminolaevulinate for actinic keratoses. *Acta Derm Venereol* 2016; 96: 712–713.