

## Darier Disease Complicated by Terbinafine-resistant *Trichophyton rubrum*: A Case Report

Sanna S. WINGFIELD DIGBY<sup>1</sup>, Marianne HALD<sup>1</sup>, Maiken C. ARENDRUP<sup>2</sup>, Sofie V. HJORTH<sup>3</sup> and Kristian KOFOED<sup>1\*</sup>

<sup>1</sup>Department of Dermato-Allergology, Copenhagen University Hospital Gentofte, Kilegårdsvej 28, DK-2900 Hellerup, <sup>2</sup>EUCAST Development Laboratory for Fungi, Unit of Mycology, Department of Microbiology and Infection Control, State Serum Institute, Copenhagen, and <sup>3</sup>Department of Pathology, Herlev Hospital, Herlev, Denmark. \*E-mail: kristian.kofoed@regionh.dk  
Accepted May 10, 2016; Epub ahead of print May 12, 2016

*Trichophyton rubrum* (*T. rubrum*) is the most common cause of superficial dermatomycoses worldwide and is responsible for more than 70% of all dermatophyte infections (1). *T. rubrum* infections can be long-lasting, difficult to treat and commonly recur after cessation of antifungal therapy (2). Unsuccessful treatment may be due to re-infection and poor adherence. Recurrence is seldom thought to be associated with resistance to antifungal agents and only a few cases of *T. rubrum* resistance to terbinafine have been reported (3). We report here a case of a patient with severe worsening of Darier disease (DD) due to widespread cutaneous terbinafine-resistant *T. rubrum* infection.

### CASE REPORT

A 62-year-old man with DD was referred for evaluation due to a flare-up of his skin condition. The patient had experienced skin changes of fluctuating severity since the age of 12 years. His father was also known to have DD. Over the years he had consulted several dermatologists

and been prescribed various topical agents and systemic acitretin, with little or no effect. In addition, he underwent numerous topical and systemic treatments for flare-ups due to recurrent fungal, bacterial and viral skin infections.

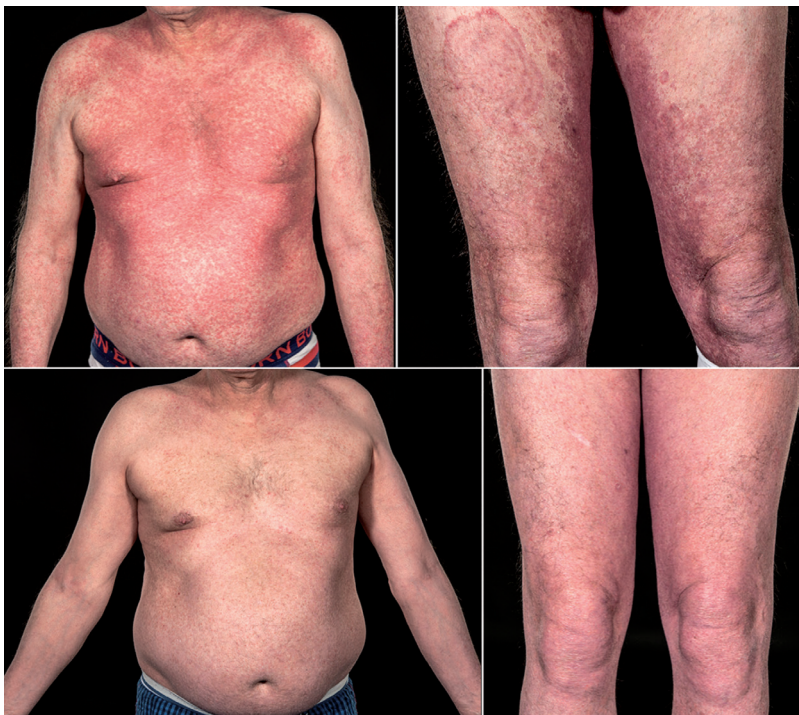
At initial presentation to our clinic, besides usual keratotic follicular papules, several well-defined erythematous annular scaly plaques were observed on the trunk and extremities (Fig. 1), indicating tinea corporis, although the patient had recently taken oral terbinafine for months.

Skin scraping was performed and direct microscopy revealed septate hyphae and arthroconidia. Culture on Sabouraud agar supplemented with cycloheximide, and direct PCR were positive for *T. rubrum*, as described previously (4). A skin biopsy, in addition to acantholysis typical of DD (Fig. 2a) showed fungal spores and hyphae within the stratum corneum (Fig. 2b). Over the course of the next 4 months treatment with topical antifungal, 2 × 30-day courses of oral terbinafine (250 mg daily) and various topical corticosteroids failed to improve the patient's skin condition.

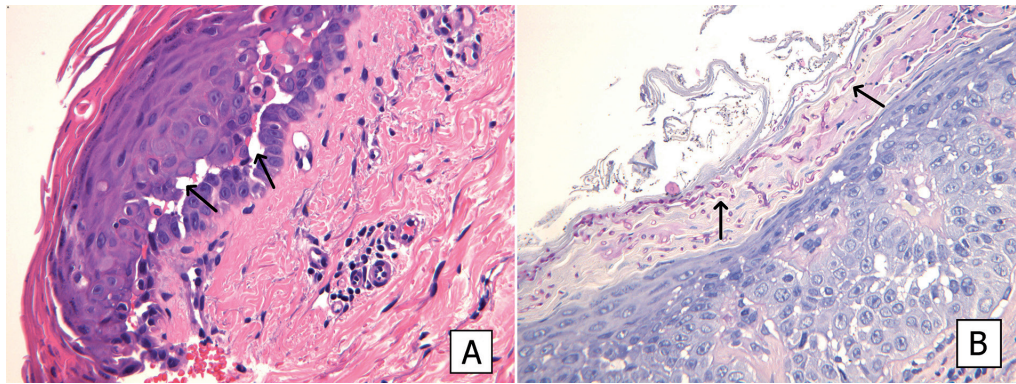
Due to the continued presentation of tinea corporis, fungal analyses were repeated and supplemented with antifungal susceptibility testing according to the European Committee on Antimicrobial Susceptibility Testing (EUCAST) microdilution reference method E.Def 9.3 with *C. krusei* ATCC6258 as control strain (5). This revealed the *T. rubrum* isolate to be resistant to terbinafine (minimum inhibitory concentration (MIC) >4 µg/ml), but susceptible to itraconazole (MIC 0.03 µg/ml). A randomly selected clinical *T. rubrum* isolate was found sensitive to both drugs (terbinafine MIC: 0.25 µg/ml, and itraconazole MIC ≤0.03 µg/ml). Two weeks after treatment with oral itraconazole (100 mg twice daily) the patient showed a dramatic improvement, the round skin lesions had cleared and his DD settled (see Fig. 1).

### DISCUSSION

DD is a rare genodermatosis characterized by persistent, greasy, hyperkeratotic



**Fig. 1. Clinical presentation.** At admission (top panel) and 2 weeks after itraconazole treatment (bottom panel).



**Fig. 2.** Cross-section of skin stained respectively with haematoxylin-eosin and periodic acid-Schiff. (A) acantholysis, and (B) presence of hyphae and spores between upper layer of basket-weave stratum corneum and lower layer of compact stratum corneum (sandwich sign).

papules in seborrhoeic areas of the face, scalp and chest. These papules may coalesce and form larger warty malodorous lesions, especially within skin folds. Pruritus and nail changes are also a common symptom. The onset of symptoms usually occurs in adolescence and may be exacerbated by heat, ultraviolet B (UVB) light and mechanical trauma. Flares of DD may also be brought on by secondary skin infections (6). Although there are only a few reports, it is generally thought that patients have a predisposition to secondary bacterial, viral and fungal infections, due to compromised skin integrity (7, 8).

The case reported here illustrates a patient with severe DD complicated by *T. rubrum* infection, refractory to treatment until the dermatophyte infection was cleared. Terbinafine is often the antimycotic agent of choice when treating dermatophytes (9). It is a synthetic allylamine derivative that inhibits squalene epoxidase, blocking the biosynthesis of ergosterol (an essential component of fungal cell membranes) and resulting in the accumulation of toxic levels of squalene (2, 3, 9).

Drug resistance in dermatophytes is rare and, to our knowledge, only one case of terbinafine-resistant *T. rubrum* has been published (9). In the literature the proposed mechanism of acquired resistance is modification of the target enzyme by gene mutation and an increase in drug efflux; less frequently, intrinsic characteristics of a *T. rubrum* strain may play a role (2, 3). In our case it was more likely acquired as a result of prolonged terbinafine therapy.

With an increasing incidence of dermatophytosis, it is important to consider antifungal drug resistance as a cause of treatment failure.

*The authors declare no conflicts of interest.*

## REFERENCES

1. Drakensjö IT, Chryssanthou E. Epidemiology of dermatophyte infections in Stockholm, Sweden: a retrospective study from 2005–2009. *Med Mycol* 2011; 49: 484–488.
2. Ghelardi E, Celandroni F, Gueye SA, Salvetti S, Senesi S, Bulgheroni A, et al. Potential of ergosterol synthesis inhibitors to cause resistance or cross-resistance in trichophyton rubrum. *Antimicrob Agents Chemother* 2014; 58: 2825–2829.
3. Mukherjee PK, Leidich SD, Isham N, Leitner I, Tyder NS, Ghannoum MA. Clinical Trichophyton rubrum strain exhibiting primary resistance to terbinafine. *Antimicrob Agents Chemother* 2003; 47: 82–86.
4. Brillowska-Dabrowska A, Nielsen SS, Nielsen HV, Arendrup MC. Optimised 5-hour multiplex PCR test for the detection of tinea unguium: performance in routine PCR laboratory. *Med Mycol* 2010; 48: 828–831.
5. Arendrup MC, Meletiadis J, Mouton JW, Guinea J, Cuenca-Estrella M, Lagrou K, et al. EUCAST Technical Note on Aspergillus and isavuconazole, Candida and itraconazole and updates for the method documents. *Clin Microbiol Infect* 2016; 22: 571.e1–4.
6. Engin B, Kutlubay Z, Erkan E, Tüzün Y. Darier disease: A fold (intertriginous) dermatosis. *Clin Dermatol* 2015; 33: 448–451.
7. Sehgal VN, Srivastava G. Darier's (Darier-White) disease/keratosis follicularis. *Int J Dermatol* 2005; 44: 184–192.
8. Nenoff P, Krüger C, Ginter-Hanselmayer G, Tietz H. Mycology – an update. Part 1: Dermatomycoses: causative agents, epidemiology and pathogenesis. *J Dtsch Dermatol Ges* 2014; 12: 188–209.
9. Gupta AK, Cooper EA. Update in antifungal therapy of dermatophytosis. *Mycopathologia* 2008; 166: 353–367.