

## REVIEW ARTICLE

# Cutaneous Porphyrias: Causes, Symptoms, Treatments and the Danish Incidence 1989–2013

Anne L. CHRISTIANSEN<sup>1,2</sup>, Lise AAGAARD<sup>3</sup>, Aleksander KRAG<sup>4</sup>, Lars M. RASMUSSEN<sup>1</sup> and Anette BYGUM<sup>5</sup>

<sup>1</sup>Department of Clinical Biochemistry and Pharmacology, Odense University Hospital, Odense, <sup>2</sup>Department of Clinical Immunology and Biochemistry, Lillebaelt Hospital, Vejle, <sup>3</sup>Department of Clinical Pharmacology, University of Southern Denmark, <sup>4</sup>Department of Gastroenterology, Odense University Hospital, and <sup>5</sup>Department of Dermatology and Allergy Centre, Odense University Hospital, Odense, Denmark

Porphyrias are rare diseases caused by altered haem synthesis leading to the accumulation of different haem intermediates. Neurovisceral attacks may occur in acute porphyrias, while photosensitivity is the presenting symptom in cutaneous porphyrias. We present here an overview of symptoms and a flowchart for the diagnosis of cutaneous porphyrias, with recommendations for monitoring and an update of treatment options. From the Danish Porphyria Register, we present the incidences and approximate prevalences of cutaneous porphyrias within the last 25 years. A total of 650 patients with porphyria cutanea tarda were identified, 73 with erythropoietic protoporphyria, 9 with variegate porphyria, 4 with hereditary coproporphyria and one with congenital erythropoietic porphyria. The total incidence of all porphyrias was ~0.52/100,000 per year. **Key words:** cutaneous porphyrias; orphan disease; Denmark.

Accepted Apr 27, 2016; Epub ahead of print May 3, 2016

Acta Derm Venereol 2016; 96: 868–872.

Anette Bygum, Department of Dermatology and Allergy Centre, Odense University Hospital, DK-5000 Odense C, Denmark. E-mail: anette.bygum@rsyd.dk

Porphyrias are diseases caused by reduced activity of an enzyme involved in haem biosynthesis (Fig. 1) resulting in accumulation of haem intermediates in the skin, liver and red blood cells (1). Clinically, porphyrias are divided into acute and cutaneous types. Patients with cutaneous porphyria are light sensitive due to the accumulation of phototoxic porphyrins in the skin, and they may develop acute and chronic skin damage following sun exposure. Porphyrins absorb light with an absorption maximum of 400–410 nm and excited porphyrins transfer energy into chemical reactions, resulting in cellular damage and inflammation (2). Patients with erythropoietic protoporphyria (EPP) develop acute painful reactions on light-exposed areas of the skin after short stays in the sun. Patients with porphyria cutanea tarda (PCT) have a more delayed response to light exposure and develop blisters and sores. Unlike PCT, patients with variegate porphyria (VP) and hereditary coproporphyria (HCP) can develop acute neurovisceral symptoms in addition to skin symptoms.

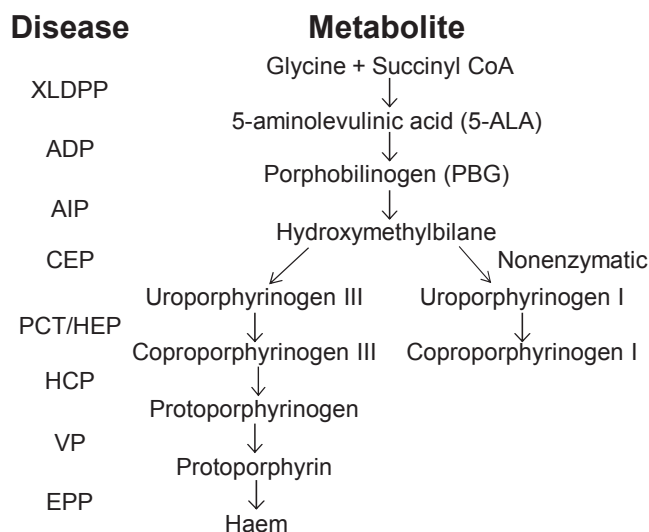


Fig. 1. Haem synthesis and porphyria diseases. Uroporphyrinogen I and coproporphyrinogen I isomers are created non-enzymatically and only uroporphyrinogen III and coproporphyrinogen III isomers can be metabolized into haem. ADP: ALA-dehydratase deficient porphyria; AIP: acute intermittent porphyria; CEP: congenital erythropoietic porphyria; EPP: erythropoietic protoporphyria; HCP: hereditary coproporphyria; HEP: hepatoerythropoietic porphyria; PCT: porphyria cutanea tarda; XLDPP: X-linked dominant protoporphyria; VP: variegate porphyria.

This article provides an overview of clinical symptoms, a diagnostic strategy and treatment options of cutaneous porphyrias, together with the Danish cases registered biochemically in the period 1989 to 2013<sup>1</sup>.

## ERYTHROPOIETIC PROTOPORPHYRIA

EPP is a disease of the bone marrow causing skin symptoms that may be complicated by hepatic invol-

<sup>1</sup>In 1990 a national porphyria centre was established at Odense University Hospital, where biochemical and molecular genetic diagnostics are now centralized (3). As a unique feature, Denmark has a porphyria register, originally founded in 1955 by physician Torben K. With, together with his wife, affiliated to the Central Laboratory and Blood Bank, Svendborg Hospital. They created a Danish porphyria register containing 349 patients with porphyria and 1,600 of the patients' relatives (4). Subsequently, physician Axel Brock continued the registration of patients with porphyria at the Department of Clinical Biochemistry, Viborg Hospital, until 2013 when the registration was passed on to the porphyria laboratory at Odense University Hospital.

vement. EPP is caused by mutations in the gene *FECH* encoding the enzyme ferrochelatase (Fig. 1). The disease has a complex inheritance and often patients have a combination of 1 *FECH* mutation (inactive allele) in combination with a low activity allele (5). In a few families, patients are homozygous or compound heterozygous for *FECH* mutations, and these patients appear to have an increased risk of severe liver disease (6). The prevalence of EPP has been calculated in a number of European countries, and ranged from 1.5 (Poland) to 27.7 (Norway) per million inhabitants (7). EPP is the most prevalent porphyria in children, and patients have a lifelong acute reaction to light. We identified a total of 73 patients with EPP in the period 1989 to 2013, which gives a prevalence of ~13 per million inhabitants. A Danish study with clinical data from 29 patients has been published earlier (8).

Protoporphyrin is lipophilic and accumulates in the endothelium of blood vessels in the skin's dermis. It is excreted in the bile and can cause liver diseases, such as cirrhosis and gallstones. In rare cases intrahepatic cholestasis and terminal liver failure can occur. Patients with EPP can develop microcytic, hypochromic anaemia; however, iron supplements should be prescribed with caution and only in cases with proven iron deficiency, because iron can exacerbate symptoms (9).

Patients with EPP develop acute burning sensations in the skin, oedema, erythema and, sometimes, purpura after sun exposure (Fig. 2A). The skin reaction can occur within minutes to a few hours, and can persist for several days. Eczematous and waxy skin can develop on the nose and knuckles ("old knuckles") (Fig. 2B) as well as smaller scars and pseudohagades around the mouth (10). In children, EPP should be suspected if the child is crying or complaining about pain in the skin during or after sun exposure. The diagnostic latency can be long; in some cases up to 40 years after the first symptom (11, 12). The diagnosis of EPP is based on clinical symptoms and detection of elevated protoporphyrin in erythrocytes (Fig. 3) (13). Genetic investigation should be carried out if the disease is biochemically verified.

As patients with EPP often experience pain immediately after sun exposure, they instinctively protect themselves against the sun. Unintended phototoxic

skin reactions may be alleviated with cold compresses, topical application of corticosteroids and, possibly, antihistamines. EPP has traditionally been treated with high-dose  $\beta$ -carotene, which colours the skin yellow by carotene pigment and acts as an antioxidant. This treatment is not effective for all patients, however, but can be tried (14). A Danish study investigated the efficacy of p.o. zinc 200 mg 3 times a day, based on the hypothesis that zinc may reduce iron absorption from the gut. This treatment reduced light-sensitivity and pain in the skin in 71% of patients, based on self-reported end-points and historical data (15). Afamelanotide, a melanocyte-stimulating hormone for subcutaneous administration, has been approved by the European Medicines Agency with orphan drug status in October 2014. Afamelanotide increases the production of the photo-protective pigment eumelanin, which absorbs and scatters light without causing cellular damage (16). However, the drug is not yet approved or marketed in Denmark. Phototherapy treatment can be used with narrow-band ultraviolet B (UVB) (TL01). Porphyrins excitation maximum is 400–410 nm, while narrow-band UVB (TL 01) has a wavelength of 311–313 nm. The exact mechanism is not known, but is thought to include thickening of the stratum corneum and epidermis, induction of melanin and suppression of the immune system (17). Cholestyramine or activated charcoal may be used if there is sign of serious liver involvement (5, 6). Ultimately, liver transplant can be life-saving and bone marrow transplantation can be carried out in order to prevent recurrence of liver disease (18).

Patients should be cautious with alcohol intake and are advised to avoid hepatotoxic medications. Some recommend vaccination against hepatitis A and B (19, 20). Patients with EPP should be monitored, with parameters reflecting liver function, haematology, iron status, vitamin D and erythrocyte protoporphyrin, every 6–12 months. Ultrasound of the liver and further hepatological assessments can be performed as needed.

#### X-LINKED DOMINANT PROTOPORPHYRIA

This is a new porphyria variant clinically resembling EPP. No Danish cases of this subtype of porphyria have

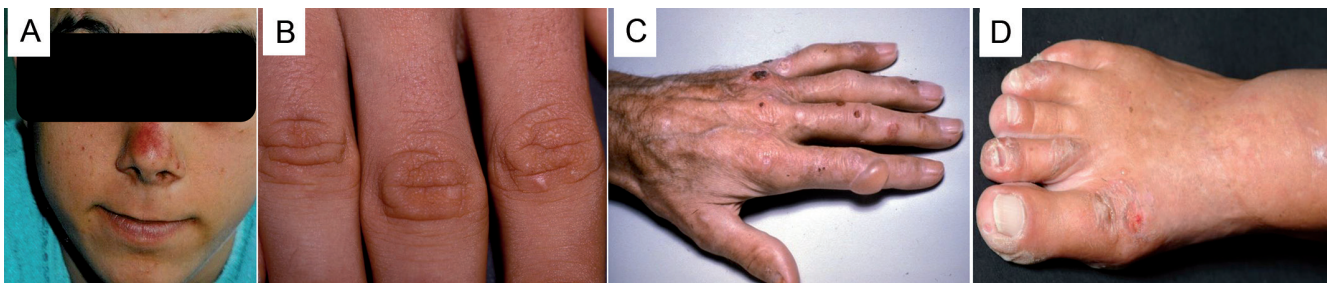


Fig. 2. Patient with erythropoietic protoporphyria and acute phototoxic reaction on the nose (A), lichenified skin on the dorsum of fingers (B). Bullae, erosions and crusted lesions on (C) the hand and (D) the foot in patients with porphyria cutanea tarda.

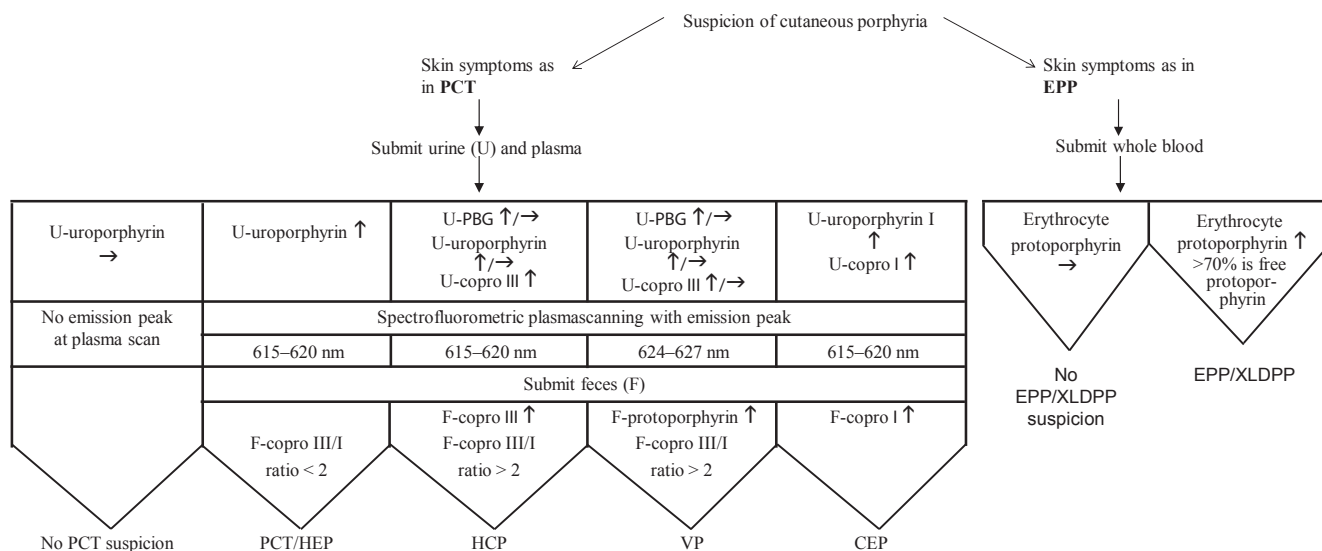


Fig. 3. Flowchart for diagnosing cutaneous porphyria with biochemical characteristics. Urine, plasma, faeces and/or whole blood is forwarded to the Department of Clinical Biochemistry and Pharmacology, Odense University Hospital. ↑: increased; →: normal. CEP: congenital erythropoietic porphyria; EPP: erythropoietic protoporphyria; HEP: hepatoerythropoietic porphyria; HCP: hereditary coproporphyria; Copro: coproporphyrin; PBG: porphobilinogen; PCT: porphyria cutanea tarda; VP: variegate porphyria; XLDPP: X-linked dominant protoporphyria.

been reported until now. Patients have elevated erythrocyte protoporphyrin but not decreased activity of *FECH*. There is, however, a gain of function mutation in *ALAS2*. Diagnosis and treatment principles are as in EPP (6).

## PORPHYRIA CUTANEA TARDA

PCT is a hepatocutaneous porphyria caused by reduced activity of uroporphyrinogen decarboxylase (*UROD*) (see Fig. 1). PCT is found in a sporadic form (sPCT) with no detectable mutation and an inherited form, familial PCT (fPCT) with mutation in the gene *UROD*. The disease fPCT is inherited in an autosomal dominant way with reduced penetrance (21, 22). The prevalence of symptomatic PCT varies geographically, with a prevalence in Sweden and Norway of 1 per 10,000 (23, 24). We identified 650 patients with PCT in the period 1989 to 2013, which corresponds to ~1 per 10,000 inhabitants.

Patients with PCT typically become symptomatic around the age of 40–50 years, but the familial form may occur earlier. Patients develop blisters, erosions and ulcers on light-exposed areas of the skin (see Fig. 2C and D) making the face, back of the hands, forearms and feet particularly vulnerable. The skin heals slowly, leaving scars and milia. The symptoms are most common in summer and autumn months. Hyperpigmentation and hypertrichosis may occur. A distinctive, and often early, symptom is vulnerable skin.

Risk factors for developing PCT are hepatitis C infection, HIV infection, alcohol intake, and oestrogen-containing medicines. These risk factors often occur in combination (25). Patients often have some degree of iron overload and the incidence of mutations in the hemochromatosis-related genes is increased compared

with the background population (26). Several studies have shown increased incidences of diabetes, liver cirrhosis and hepatocellular carcinoma (20, 21, 27).

The diagnosis of PCT is made on clinical features combined with measurement of porphyrins in the urine, faeces and plasma (see Fig. 3) (13). In the active disease state, one can see red fluorescence of urine and fluid from blisters by illumination with long-wave UV light (21). VP and HCP may have similar pattern excretion in urine, and therefore these conditions must be excluded by measuring porphyrins in plasma and excretion pattern in faeces (Fig. 3) (13). fPCT can be investigated by genetic testing (21).

Patients with PCT should avoid excessive alcohol intake, oestrogen use and unnecessary iron treatment. Sun exposure is primarily limited by protective clothing, cessation of sunbathing and tanning use, and the use of sun-blockers. In addition, phlebotomy and/or low-dose hydroxychloroquine can be used. Low-dose hydroxychloroquine probably works by increasing the excretion of water-soluble porphyrins (21, 28, 29). Phlebotomies deplete the liver iron content and reduce porphyrins in plasma and urine. Treatment can be effective in patients with and without iron overload. Clinical remission is typically achieved after 5–7 phlebotomies of 350–500 ml. Phlebotomies are particularly well chosen in patients with haemochromatosis. If the above treatments are contraindicated, iron-chelating compounds may be used. Treatment of PCT probably reduces the risk for developing HCC.

In the active treatment periods, porphyrin concentrations should be monitored in urine or plasma every third month and, after that, once yearly until complete remission.



## PSEUDOPORPHYRIA AND PORPHYRIA CUTANEA TARDA IN DIALYSIS PATIENTS

Patients with pseudoporphyria have skin manifestations that clinically and histologically imitate PCT. These patients, however, have normal haem metabolism and are not included in the porphyria register. The condition may occur in patients treated with various phototoxic drugs, especially in patients with chronic renal failure receiving high-dose diuretics. Dialysis patients may have elevated concentration of porphyrins in plasma due to insufficient dialysis and can be distinguished from patients with PCT by the quantity of porphyrins in plasma (30).

The treatment of PCT in dialysis patients is a challenge, since dialysis patients often have anaemia, which contraindicates phlebotomy. Anti-malarial treatment is ineffective, since mobilized porphyrins cannot be eliminated by standard haemodialysis or peritoneal dialysis. Instead high-flux dialysis or treatment with erythropoietin  $\pm$  low-volume phlebotomy may be attempted (31–33).

## VARIEGATE PORPHYRIA AND HEREDITARY COPROPORPHYRIA

VP and HCP occur due to mutations in the genes coding for the protoporphyrinogen oxidase (PPOX) and coproporphyrinogen oxidase (CPOX), respectively. Both diseases are inherited in an autosomal dominant manner with incomplete penetrance. VP is rare, with a prevalence in Europe ranging from 0.4 (Poland) to 10.4 (Switzerland) per million inhabitants (7). In South Africa, VP is much more frequent (34). HCP occur with a prevalence of approximately 1/100,000 (35). Since 1989 we have registered 9 patients with VP and 4 with HCP in Denmark.

Patients with HCP and VP may have PCT-like skin lesions or acute episodic neurovisceral attacks or both. Symptoms of acute neurovisceral attacks, which can be life-threatening (36), are abdominal pain, vomiting, constipation, hypertension, tachycardia, fever, muscle weakness, fatigue, paresis, sensory disturbances, seizures, mental instability or hallucinations (3, 34).

## RARE RECESSIVE PORPHYRIAS

Congenital erythropoietic porphyria (CEP), Günther's disease, is a recessive disease presenting in early childhood with red-coloured urine in diapers (37). Only one patient has been diagnosed in Denmark hitherto. These patients are very sensitive to light and develop blisters and scarring after exposure to sunlight. Deformity of the nose, ears and the distal parts of fingers and toes may occur. Hyperpigmentation, hypertrichosis, scarring alopecia and scleromalacia can also be seen.

Teeth and bones are reddish-brown due to deposition of porphyrins. Hepatoerythropoietic porphyria (HEP) is caused by homozygous or compound heterozygous mutations in *UROD*. There are no patients with HEP registered in Denmark. The symptoms are as in patients with CEP.

At the National Board of Health and European Commission level there is increased focus on rare diseases, and collaboration with patient organizations is highlighted in the national strategy for rare diseases in Denmark. In Scandinavia, the patients with porphyria are organized in the following patient associations: with Porfyriforeningen in Denmark ([www.porfyriforeningen.dk](http://www.porfyriforeningen.dk)), Riksföreningen mot porfyrisjukdomar ([www.porfyri.se](http://www.porfyri.se)) in Sweden and Norsk Porfyriforening ([www.porfyri.no](http://www.porfyri.no)) in Norway.

Although the porphyrias are all caused by decreased activity of an enzyme in haem biosynthesis, there are differences in clinical and biochemical appearance and treatment possibilities. EPP should be suspected when a child or adult patient has painful and immediate skin reactions to the sun; while PCT is characterized by delayed skin reactions to sun mostly in adults. When using the diagnostic flow diagram given in this article the patients can be given a correct diagnoses and guidance on precautions and medical therapy.

## REFERENCES

1. Brock A, Rasmussen LM, Hertz JM. Strategies for diagnosis and biochemical control of porphyrias. *Ugeskr Laeger* 2014; 176(8A): PiiV06130413.
2. Poh-Fitzpatrick MB. Porphyrias: photosensitivity and phototherapy. *Methods Enzymol* 2000; 319: 485–493.
3. Petersen NE, Brock A. Acute porphyria. *Ugeskr Laeger* 2000; 162: 1525–1527.
4. With TK. The different types of porphyria in Denmark and the importance of family studies. *Int J Biochem* 1980; 12: 887–889.
5. Lecha M, Puy H, Deybach JC. Erythropoietic protoporphyria. *Orphanet J Rare Dis* 2009; 4: 19.
6. Puy H, Gouya L, Deybach JC. Porphyrias. *Lancet* 2010; 375: 924–937.
7. Elder G, Harper P, Badminton M, Sandberg S, Deybach JC. The incidence of inherited porphyrias in Europe. *J Inher Metab Dis* 2013; 36: 849–857.
8. Schmidt H, Snitker G, Thomsen K, Lintrup J. Erythropoietic protoporphyria. A clinical study based on 29 cases in 14 families. *Arch Dermatol* 1974; 110: 58–64.
9. Milligan A, Graham-Brown RA, Sarkany I, Baker H. Erythropoietic protoporphyria exacerbated by oral iron therapy. *Br J Dermatol* 1988; 119: 63–66.
10. Dam C, Bathum L, Sommerlund M, Bygum A. [Erythropoietic protoporphyria. A rare inherited metabolic disorder with skin symptoms]. *Ugeskr Laeger* 2008; 170: 352 (in Danish).
11. Wahlin S, Floderus Y, Ros AM, Broomé U, Harper P. The difficult clinical diagnosis of erythropoietic protoporphyria. *Physiol Res* 2006; 55 Suppl 2: S155–157.
12. Christiansen AL, Brusgaard K, Hertz JM, Bygum A. [A patient diagnosed herself with erythropoietic protoporphyria

- after googling photosensitivity]. *Ugeskr Laeger* 2015; 177: PiiV01150015 (in Danish).
13. EPNET (European Porphyria Network). Available from: <http://www.porphyrria-europe.com/02-for-healthcare/labodiagnosis.asp>.
  14. Minder EI, Schneider-Yin X, Steurer J, Bachmann LM. A systematic review of treatment options for dermal photosensitivity in erythropoietic protoporphyria. *Cell Mol Bio (Noisy-le-Grand)* 2009; 55: 84–97.
  15. Petersen AB, Philipsen PA, Wulf HC. Zinc sulphate: a new concept of treatment of erythropoietic protoporphyria. *Br J Dermatol* 2012; 166: 1129–1131.
  16. Langendonk JG, Balwani M, Anderson KE, Bonkovsky HL, Anstey AV, Bissell DM, et al. Afamelanotide for Erythropoietic Protoporphyria. *N Engl J Med* 2015; 373: 48–59.
  17. Warren LJ, George S. Erythropoietic protoporphyria treated with narrow-band (TL-01) UVB phototherapy. *Australas J Dermatol* 1998; 39: 179–182.
  18. Singal AK, Parker C, Bowden C, Thapar M, Liu L, McGuire BM. Liver transplantation in the management of porphyria. *Hepatology* 2014; 60: 1082–1089.
  19. Anstey AV, Hift RJ. Liver disease in erythropoietic protoporphyria: insights and implications for management. *Postgrad Med J* 2007; 83: 739–748.
  20. Horner ME, Alikhan A, Tintle S, Tortorelli S, Davis DM, Hand JL. Cutaneous porphyrias part I: epidemiology, pathogenesis, presentation, diagnosis, and histopathology. *Int J Dermatol* 2013; 52: 1464–1480.
  21. Bygum A, Brandrup F, Christiansen L, Petersen NE. [Porphyria cutanea tarda]. *Ugeskr Laeger* 2000; 162: 2020–2024 (in Danish).
  22. Badminton MN, Elder GH. Molecular mechanisms of dominant expression in porphyria. *J Inherit Metab Dis* 2005; 28: 277–286.
  23. Rossmann-Ringdahl I, Olsson R. Porphyria cutanea tarda in a Swedish population: risk factors and complications. *Acta Derm Venereol* 2005; 85: 337–341.
  24. Mykletun M, Aarsand AK, Stoele E, Villanger JH, Tollanes MC, Baravelli C et al. Porfyrisykdommer i Norge. *Tidsskr Nor Legeforen* 2014; 134: 831–835.
  25. Jalil S, Grady JJ, Lee C, Anderson KE. Associations among behavior-related susceptibility factors in porphyria cutanea tarda. *Clin Gastroenterol Hepatol* 2010; 8: 297–302.
  26. Bygum A, Christiansen L, Petersen NE, Hørdér M, Thomsen K, Brandrup F. Familial and sporadic porphyria cutanea tarda: clinical, biochemical and genetic features with emphasis on iron status. *Acta Derm Venereol* 2003; 83: 115–120.
  27. Fracanzani AL, Taioli E, Sampietro M, Fatta E, Bertelli C, Fiorelli G, et al. Liver cancer risk is increased in patients with porphyria cutanea tarda in comparison to matched control patients with chronic liver disease. *J Hepatol* 2001; 35: 498–503.
  28. Tintle S, Alikhan A, Horner ME, Hands JL, Davis DM. Cutaneous porphyrias part II: treatment strategies. *Int J Dermatol* 2014; 53: 3–24.
  29. Singal AK, Kormos-Hallberg C, Lee C, Sadagoparamunjam VM, Grady JJ, Freeman DH Jr, et al. Low-dose hydroxychloroquine is as effective as phlebotomy in treatment of patients with porphyria cutanea tarda. *Clin Gastroenterol Hepatol* 2012; 10: 1402–1409.
  30. Hindmarsh JT, Oliveras L, Greenway DC. Plasma porphyrins in the porphyrias. *Clin Chem* 1999; 45: 1070–1076.
  31. Anderson KE, Goeger DE, Carson RW, Lee SM, Stead RB. Erythropoietin for the treatment of porphyria cutanea tarda in a patient on long-term hemodialysis. *N Engl J Med* 1990; 322: 315–317.
  32. Peces R, Enriquez de Salamanca R, Fontanellas A, Sánchez A, de la Torre M, Caparros G, et al. Successful treatment of haemodialysis-related porphyria cutanea tarda with erythropoietin. *Nephrol Dial Transplant* 1994; 9: 433–435.
  33. Carson RW, Dunnigan EJ, DuBose TD Jr., Goeger DE, Anderson KE. Removal of plasma porphyrins with high-flux hemodialysis in porphyria cutanea tarda associated with end-stage renal disease. *J Am Soc Nephrol* 1992; 2: 1445–1450.
  34. Frank J, Christiano AM. Variegated porphyria: past, present and future. *Skin Pharmacol Appl Skin Physiol* 1998; 11: 310–320.
  35. Martásek P. Hereditary coproporphyria. *Semin Liver Dis* 1998; 18: 25–32.
  36. Stein P, Badminton MN, Barth JH, Rees DC, Sarkany R, Stewart MF, et al. Acute intermittent porphyria: fatal complications of treatment. *Clin Med* 2012; 12: 293–294.
  37. Schulenburg-Brand D, Katugampola R, Anstey AV, Badminton MN. The cutaneous porphyrias. *Dermatol Clin* 2014; 32: 369–384.