

## SHORT COMMUNICATION

Aquagenic Palmoplantar Keratoderma as a *CFTR*-related Disorder

Christelle Cabrol<sup>1</sup>, Thierry Bienvenu<sup>2</sup>, Lyse Ruaud<sup>1</sup>, Emmanuelle Girodon<sup>2</sup>, Gérald Noacco<sup>3</sup>, Marine Delobeau<sup>4</sup>, Ferial Fanian<sup>4</sup>, Bénédicte Richaud-Thiriez<sup>5</sup>, Lionel Van Maldergem<sup>1</sup> and François Aubin<sup>4\*</sup>

<sup>1</sup>Human Genetic Center, University Hospital, Besançon, <sup>2</sup>Laboratory of Biochemistry and Molecular Genetics, GH Paris Centre, Site Cochin, AP-HP, University Paris-Descartes, Paris, <sup>3</sup>Dermatology, Private Practice, Joncherey, <sup>4</sup>Department of Dermatology, University Hospital, University of Franche Comté, EA3181, FR-25030 Besançon, and <sup>5</sup>Department of Pneumology, Cystic Fibrosis Reference Center, University Hospital, Besançon, France. \*E-mail: francois.aubin@univ-fcomte.fr Accepted Mar 24, 2016; Epub ahead of print Mar 29, 2016

Cystic fibrosis (CF) has been regarded for decades as a life-threatening, autosomal recessive disorder. Improved knowledge of its clinical spectrum and of handling and therapy for CF have increased the emphasis on mild phenotypes. Aquagenic palmoplantar keratoderma (APK) was first described in 1974 by Elliot in patients with CF (1). APK, also known as aquagenic wrinkling of the palms, transient reactive papulotranslucent acrokeratoderma, aquagenic syringal keratoderma or transient aquagenic hyperwrinkling, is a transient dermatosis characterized by translucent or whitish papules on the palms and/or soles developing after brief exposure to water. Several studies have found a high prevalence of APK among CF patients, ranging from 40% to 84% (2, 3), suggesting that APK is associated with *CFTR* (cystic fibrosis transmembrane conductance regulator) dysfunction. We report here an isolated case of APK associated with a compound heterozygosity for 2 rare *CFTR* gene mutations.

## CASE REPORT

A 27-year-old Caucasian woman with no history of digestive symptoms was referred to the dermatology clinics for swelling and discoloration of the palms after bathing or swimming since one year. Her symptoms were spontaneously regressive a few hours after exposure. She had a personal history of pneumonia at the age of 3 years and underwent tonsillectomy at 18 years for relapsing angina. On clinical examination, rapid development of a papillomatous appearance of the palms in their medial portion, together with oedema of the stratum corneum, was observed after a 3-min exposure to water (Fig. 1). A diagnosis of APK was made. A sweat test for chloride concentration was positive on the right arm (64 mmol/l, normal value <60 mmol/l), while concentration was normal (51 mmol/l; intermediate range 40–60 mmol/l) on the left arm. Her growth parameters were normal (160 cm; 50 kg) with no chest deformity. Bilateral 5<sup>th</sup> toes clinodactyly corresponding radiologically to brachymesophalangy was noted. Her sinus X-ray was normal (absence of nasal polyposis), as were chest X-rays and a computed tomography (CT) scan. Although she also reported effort dyspnoea and tachycardia, cardiopulmonary examination and respiratory function were normal. Deficiency of vitamins A, D and K were present and required substitution. A panel search for 32 common mutations of the *CFTR* gene (Abbott, Rungis, France) was negative. Full *CFTR* gene sequencing was performed, leading to identification of compound heterozygosity for a missense *CFTR* mutation (CF-RD mutation; c.2855T>C, M952T) already reported in congenital bilateral absence of the vas deferens (CBAVD), and a severe classical CF mutation, namely c.2620-674\_3367+198del19855

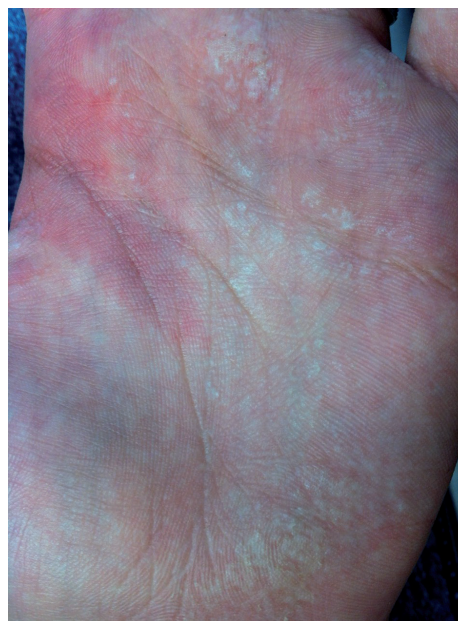

Fig. 1. Aspect of the medio-palmar area after a 3-min exposure to water.

(del14b-17b). Each *CFTR* mutation was found in a healthy parent (Fig. 2). Based on these results, clinical signs and symptoms were reassigned to a *CFTR*-related disorder (CFTR-RD). Botulinum toxin injection in her hands resulted in a marked improvement in her APK at 12 months of follow-up.

## DISCUSSION

CF is usually diagnosed at an early age, and more than 75% of patients with CF are diagnosed by age 2 years. Non-classic CF in children and young adults provides a greater challenge. We describe here such a patient with APK due to a compound heterozygosity for 2 rare mutations of the *CFTR* gene. Currently, more than 2,000 *CFTR* mutations have been identified. They are classified based on their potential consequences on *CFTR* function or depending on clinical consequences (4). A CFTR-RD is defined as a clinical entity associated with *CFTR* dysfunction that does not fulfil the diagnostic criteria for CF (5). Three main clinical entities illustrate these phenotypes: CBAVD with *CFTR* dysfunction, acute recurrent or chronic pancreatitis with *CFTR* dysfunction and disseminated bronchiectasis with *CFTR* dysfunction. In our patient,

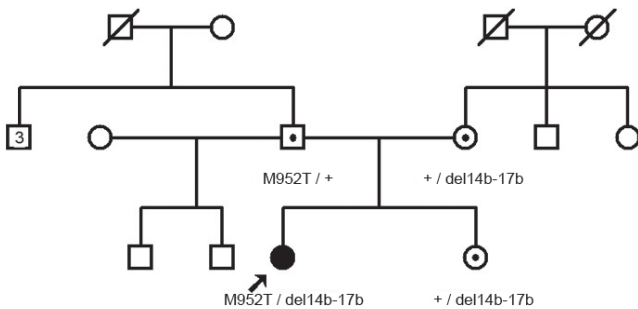


Fig. 2. Biparental inheritance of cystic fibrosis transmembrane conductance regulator (CFTR) mutations.

the c.2620-674\_3367+198del9855 (del14b-17b) mutation is considered as a classical CF mutation, while c.2855T>C (M952T) is considered as a CFTR-RD mutation. It has been previously identified in an infertile patient with CBAVD and in a neonate carrying the CF c.1521\_1523del (F508del) mutation on the other chromosome and having an intermediate sweat test (6). The positive chloride sweat test, which is still the gold standard for confirming a CF diagnosis, allowed us to assign our patient into the CFTR-RD group.

Papers aimed at clarifying the relationship between APK and *CFTR* dysfunction fall into 2 categories: those evaluating the importance of APK as a CF manifestation in systematically recording its presence or absence in a CF population (2, 3) and those screening *CFTR* mutations in a population of patients with APK. To our knowledge, only 13 APK patients with *CFTR* gene mutations have been reported (7–10). One study indicated a full *CFTR* sequencing (7), while 2 reported screening for a set of common mutations (9, 10), meaning that rare *CFTR* mutations may have been missed, as would have been the case in our patient when stopping our investigation at the level of panel screening.

Besides its association with CF, APK has also been described as an acquired condition related to the intake of aspirin and COX-2 inhibitors or in association with hyperhidrosis (11, 12). Although the pathophysiology of APK is poorly understood, there is evidence suggesting an increase in stratum corneum water-binding capacity, as a result of an increased electrolyte concentration in sweat, as observed in CF, in hyperhidrosis or in case of COX-2 inhibitors toxicity (12, 13). Chinazzo et al. (13) showed that salt concentrations were significantly higher in CF patients with APK. In addition, treatment of a CF patient with ivacaftor, a pharmacological potentiator of *CFTR* function, inhibited the occurrence of APK, while the sweat chloride concentration decreased considerably (14). However, Berk et al. (15) did not find such a correlation between sweat chloride concentrations measured at the time of diagnosis and APK severity in patients with CF.

In conclusion, we propose including sporadic isolated APK in the clinical spectrum of *CFTR* gene mutations,

as a *CFTR*-related disorder, also in more dubious cases (16). Furthermore, screening *CFTR* gene for rare mutations should be recommended in patients with isolated APK to adjust genetic counselling, as well as management and prevention of complications.

## REFERENCES

- Elliott RB. Letter: Wrinkling of skin in cystic fibrosis. *Lancet* 1974; 2: 108.
- Tolland JP, Boyle J, Hall V, McKenna KE, Elborn JS. Aquagenic wrinkling of the palms in an adult cystic fibrosis population. *Dermatology* 2010; 221: 326–330.
- Arkin LM, Flory JH, Shin DB, Gelfand JM, Treat JR, Allen J, et al. High prevalence of aquagenic wrinkling of the palms in patients with cystic fibrosis and association with measurable increases in transepidermal water loss. *Pediatr Dermatol* 2012; 29: 560–566.
- Castellani C, Cuppens H, Macek M Jr, Cassiman JJ, Kerem E, Durie P, et al. Consensus on the use and interpretation of cystic fibrosis mutation analysis in clinical practice. *J Cyst Fibros* 2008; 7: 179–196.
- Cystic Fibrosis Mutation Database. Available from: <http://www.genet.sickkids.on.ca/app>.
- Bombieri C, Claustres M, De Boeck K, Derichs N, Dodge J, Girodon E, et al. Recommendations for the classification of diseases as *CFTR*-related disorders. *J Cyst Fibros* 2011; 10 Suppl 2: S86–102.
- Stewart LC, Doe SJ, Bourke SJ, Leech S. Aquagenic palmar wrinkling as a presenting feature of cystic fibrosis gene dysfunction. *Clin Exp Dermatol* 2009; 34: e647–e649.
- Rongioletti F, Tomasini C, Crovato F, Marchesi L. Aquagenic (pseudo) keratoderma: a clinical series with new pathological insights. *Br J Dermatol* 2012; 167: 575–582.
- Baquerizo K, Amini S, Keri JE, Badiavas EV, Elgart GW. Atypical form of transient reactive papulotranslucent acrokeratoderma in a cystic fibrosis carrier: transient reactive papulotranslucent acrokeratoderma. *J Cutan Pathol* 2013; 40: 413–418.
- Vale R, Adam DN. Idiopathic aquagenic wrinkling of the palms in sisters. *J Dermatol* 2012; 39: 471–472.
- Khoo PT, Duncan KO, Kwan A, Hoyme HE, Bruckner AL. Unilateral aquagenic wrinkling of the palms associated with aspirin intake. *Arch Dermatol* 2006; 142: 1661–1662.
- Carder KR, Weston WL. Rofecoxib-induced instant aquagenic wrinkling of the palms. *Pediatric Dermatology* 2002; 19: 353–355.
- Chinazzo C, De Alessandri A, Menoni S, Romanisio G, Rebora A, Rongioletti F. Aquagenic wrinkling of the palms and cystic fibrosis: an Italian study with controls and genotype-phenotype correlations. *Dermatology* 2014; 228: 60–65.
- Grasemann H, Ratjen F, Solomon M. Aquagenic wrinkling of the palms in a patient with cystic fibrosis. *N Engl J Med* 2013; 369: 2362–2363.
- Berk DR, Ciliberto HM, Sweet SC, Ferkol TW, Bayliss SJ. Aquagenic wrinkling of the palms in cystic fibrosis: comparison with controls and genotype-phenotype correlations. *Arch Dermatol* 2009; 145: 1296–1299.
- Marinello E, Dan G, Linder DM, Belloni Fortina A, Peserico A, Piaserico S. Symmetrical, hypopigmented, papules and plaques on the palms induced by contact with water: a quiz. *Acta Derm Venereol* 2016; 96: 575–576.