

INVESTIGATIVE REPORT

Clinical and Immunological Studies of 332 Japanese Patients Tentatively Diagnosed as Anti-BP180-type Mucous Membrane Pemphigoid: A Novel BP180 C-terminal Domain Enzyme-linked Immunosorbent Assay

Atsushi YASUKOCHI[#], Kwesi TEYE, Norito ISHII and Takashi HASHIMOTO

Department of Dermatology, Kurume University School of Medicine, and Kurume University Institute of Cutaneous Cell Biology, Fukuoka, Japan

[#]Present address: Section of Oral and Maxillofacial Oncology, Division of Maxillofacial Diagnostic and Surgical Sciences, Faculty of Dental Science, Kyushu University, Fukuoka, Japan

Diagnosis of anti-BP180-type mucous membrane pemphigoid (BP180-MMP) is frustrated by the difficulty of detecting BP180 reactivity. A total of 721 patients with suspected MMP, selected from a cohort of 4,698 patients with autoimmune bullous disease (AIBD), were included in this study. Of these, 332 patients were tentatively diagnosed as BP180-MMP if they showed IgG/IgA reactivity with the epidermal side of 1M NaCl-split-skin and/or positive reactivity with BP180 in at least one of our antigen detection methods. Clinically, a predominance of female patients was found. Oral mucosal and cutaneous lesions were found in 85.5% and 41.0% of patients, respectively, and frequent treatments were systemic steroids, tetracycline/minocycline and diaminodiphenyl sulfone. Various immunological methods, including a newly developed BP180 C-terminal domain enzyme-linked immunosorbent assay (ELISA), revealed frequent reactivity with BP180 C-terminal and NC16a domains. Some patients reacted with BP180 and other antigens, indicating that BP180-MMP tends to concur with other AIBDs. This large study of patients with suspected BP180-MMP indicates the difficulty of diagnosis of BP180-MMP and the diagnostic usefulness of BP180 C-terminal domain ELISA. Key words: autoantibody; BP180; enzyme-linked immunosorbent assay; mucous membrane pemphigoid; recombinant protein.

Accepted Mar 10, 2016; Epub ahead of print mar 17, 2016

Acta Derm Venereol 2016; 96: 762–767.

Takashi Hashimoto, Department of Dermatology, Kurume University School of Medicine, and Kurume University Institute of Cutaneous Cell Biology, 67 Asahimachi, Kurume, Fukuoka 830-0011, Japan. E-mail: hashimot@med.kurume-u.ac.jp

As one of the centres for diagnosis of autoimmune bullous diseases (AIBDs) in Japan, we have collected sera, skin samples and data from more than 5,000 difficult cases of AIBD over the last 19 years (1). In this large cohort, many patients are suspected to have mucous membrane pemphigoid (MMP).

BP180 is a hemidesmosomal transmembrane protein located in the epidermal basement membrane zone (BMZ) (Fig. S1¹) (2, 3). BP180 NC16a domain (BP180-NC16a) and BP180 C-terminal domain (BP180-C) are considered major antigenic domains in bullous pemphigoid (BP) and anti-BP180-type MMP (BP180-MMP), respectively (2, 3).

Clinically, MMP manifests as erosive and blistering lesions, occurring preferentially on various mucous membranes, particularly the oral and ocular mucosae, and, histopathologically, subepithelial and subepidermal blistering (4–7). Immunological findings are variable and therefore MMP is thought to be heterogeneous.

MMP is divided into 2 major types (4–7), BP180-MMP (3) and anti-laminin-332-type MMP (LM332-MMP) (8, 9). In addition, oral MMP and ocular MMP show lesions predominantly on oral and ocular mucosae, respectively (10, 11). Patients with ocular mucosal lesions alone are diagnosed as having pure ocular MMP (11).

In this study of 721 suspected cases of MMP from the AIBD cohort from Kurume University, 332 patients were diagnosed as having BP180-MMP according to our criteria. The patients were clinically and immunologically characterized and an enzyme-linked immunosorbent assay (ELISA) for BP180-C recombinant protein (RP) was performed.

MATERIALS AND METHODS

All studies were performed according to the guidelines of the medical ethics committee of Kurume University School of Medicine and the principles of the Declaration of Helsinki. All participants provided informed consent.

Patient sera and normal sera

In this study, out of more than 5,000 patients whose sera and data were sent to us from other institutes for diagnostic studies over a period of approximately 18 years between May 2008 and December 2015, 4,698 patients were selected for whom adequate clinical information was available from consultation letters. These

¹<http://www.medicaljournals.se/acta/content/?doi=10.2340/00015555-2407>

4,698 patients were screened to select BP180-MMP sera. Forty-four normal sera were used as negative controls, as well as disease control sera from patients with various AIBDs, including bullous pemphigoid (BP), LM332-MMP, epidermolysis bullosa acquisita (EBA), pemphigus vulgaris, pemphigus foliaceus and paraneoplastic pemphigus. All sera were stored at -80°C for long-term and at 4°C with 0.1% sodium azide as preservative during experiments.

Immunofluorescence studies

Direct immunofluorescence (IF) for IgG, IgA, IgM and complement C3 was performed on skin biopsy samples using the standard method. Direct IF was performed at Kurume University for only a proportion of the patients, in whom skin biopsy samples were sent from other institutes.

Indirect IF studies of normal human skin and 1M NaCl-split-human skin (ss-IIF) for both IgG and IgA antibodies were performed as described previously (12).

Immunoblotting and ELISA studies

IgG and IgA immunoblotting (IB) analyses of normal human epidermal extract (12, 13), BP180-NC16a RP (2), BP180-C RP (3), and concentrated culture supernatant of HaCaT cells (14, 15) were performed as described previously. IgG IB analyses of normal human dermal extract (16) and purified human LM332 (17) were also performed.

IgG and IgA ELISA of BP180-NC16a RP and BP230 RPs were performed using commercially available kits (MESA-CUP, MBL, Nagoya, Japan). Cut-off values were index 15.0 for BP180 ELISA and index 9.0 for BP230 ELISA for IgG antibodies, while optical density (OD) 0.15 was set as cut-off value for IgA antibodies. IgG ELISA for desmoglein 1 (Dsg1) and Dsg3 (MESACUP, MBL) were also performed (cut-off values <index 12). OD at 490 nm was measured by ELISA reader (Nalge Nunc International Co., New York, NY, USA).

Production of BP180-C RP

Expression vector and RP for the C-terminal 305 amino acids (1193-1497aa) of human BP180 was prepared as described previously (Fig. S1¹) (3), with several modifications. Briefly, the 915-bp cDNA fragment was amplified by PCR, and cloned into pGEX-4T1 vector. RP fused with glutathione-S-transferase was produced in BL21 by induction with 0.5 mM isopropyl-beta-d-thiogalactopyranoside. Because the RP was insoluble in standard buffer for column purification, the bacterial pellet was solubilized in 8 M urea in PBS and separated by sodium dodecyl sulphate polyacrylamide gel electrophoresis (SDS-PAGE). RP was purified from gel by electrophoretic elution.

Novel ELISA of BP180-C RP

To develop the BP180-C RP ELISA, Maxisorp strip plates (Nunc A/S, Roskilde, Denmark) were coated with 100 μl 2.0 $\mu\text{g}/\text{ml}$ purified BP180-C RP in Tris-buffered saline (TBS) at 4°C overnight. The plates were then blocked with 320 μl blocking buffer (10% adult bovine serum, 5% sucrose and 0.05% sodium azide in TBS) for 3 h, dried up, and kept at -30°C for less than 3 months. For the experiments, sera 1:100 diluted in 100 μl sample buffer (0.01% Tween 20 and 2% adult bovine serum in TBS) were applied to the plates and incubated at room temperature (RT) for 1 h. After washing with T-TBS (TBS containing 0.05% Tween 20), the plates were incubated with horseradish peroxidase (HRP)-conjugated-anti-human antibodies to human IgG (1:8,000) or IgA (1:4,000) (MBL) for 1 h. After washing again, 100 μl 3,3',5,5'-tetramethylbenzidine solution (Moss Inc., MD, USA) was incubated at RT for 30 min, and then 100 μl 0.5 M HCl was added to stop the reaction. OD was measured at 490 nm, as above.

Tentative criteria for diagnosis of BP180-MMP

Diagnosis of BP180-MMP is difficult, mainly because there are no satisfactory diagnostic criteria for BP180-MMP due to the low frequency of detection of autoantibodies and autoantigens (i.e. BP180) and the heterogeneity of MMP. This study used tentative diagnostic criteria for BP180-MMP (see algorithm in Fig. S2¹).

First, cases with the term MMP in the final diagnoses were selected from our AIBD cohort. Then, from the results of ss-IIF, the cases were divided into ss-IIF-epi(+) group, which showed IgG and/or IgA positive reactivity with epidermal side, and ss-IIF-epi(-) group, which showed no positive reactivity or reacted only with the dermal side. From ss-IIF-epi(+) cases, we excluded non-Japanese cases, those without sufficient information about mucosal involvement, and those with predominantly cutaneous lesions. The remaining cases were diagnosed as BP180-MMP.

From the ss-IIF-epi(-) cases, we excluded non-Japanese cases, those with inadequate information about mucosal involvements, those with skin dominant lesions, and those with no positive reactivity with BP180-related proteins (i.e. positive reactivity with intact BP180 in normal human epidermal extract, the 120 kDa LAD-1 in concentrated culture supernatant of HaCaT cells, BP180-NC16a RP or BP180-C RP). Thus, the remaining cases, which reacted with at least one of the above BP180-related antigens in IB and/or ELISA were also diagnosed with BP180-MMP. Finally, we combined BP180-MMP cases from both ss-IIF-epi(+) and ss-IIF-epi(-) groups.

Statistical analysis

Quantitative data are presented as mean \pm standard deviation (SD). The statistical significance of differences was assessed by Wilcoxon test. $p < 0.05$ was considered statistically significant.

RESULTS

Patients

Using our tentative diagnostic criteria for BP180-MMP, 721 cases were selected from the 4,698 patients in our AIBD cohort that included the term MMP in the final diagnoses (Fig. S2¹). The 721 cases were then divided into 403 ss-IIF-epi(+) cases and 318 ss-IIF-epi(-) cases (Fig. S2¹). For the 721 cases, all available sera were examined at least once using the novel ELISA of BP180-C RP.

From the 403 ss-IIF-epi(+) cases, 146 cases were excluded, and a final diagnosis of BP180-MMP was made for 257 cases. Twelve cases had only ocular mucosal lesions, and were diagnosed as pure ocular MMP. From the 318 ss-IIF-epi(-) cases, we excluded 243 cases, and made a diagnosis of BP180-MMP in 75 cases. Four cases had only ocular mucosal lesions. Combining the 257 cases from the ss-IIF-epi(+) group and 75 cases from the ss-IIF-epi(-) group, 332 cases were finally diagnosed as BP180-MMP.

The 332 BP180-MMP cases were then assessed for various clinical and immunological findings, as described below. In addition, from the 257 cases of the ss-IIF-epi(+) group, 252 cases with sufficient sera were examined convincingly 2 or 3 times by repeated BP180-C ELISA.

Various immunological studies, mainly IB of purified human LM332, confirmed that 151 ss-IIF-epi(-) cases with exclusive reactivity with dermal side were sole LM332-MMP.

Clinical data in 332 cases of BP180-MMP

Patient background and underlying diseases. Because of the large cohort size and long surveillance time for the 332 patients with BP180-MMP, most clinical and immunological results were not obtained for all patients. Therefore, only those cases for which data were available for each parameter were analysed in the following sections.

Among 332 cases of BP180-MMP, information about gender was available in 308 cases (Fig. S3a,c¹). The male/female ratio was 120:188, indicating female prevalence. Mean age at onset of disease was 66.06 years for a total of 288 cases (66.23 years for 115 males, and 65.83 years for 173 females) (Fig. S3c¹). There was a peak of disease onset at 60–80 years (Fig. S3b¹).

The cases of BP180-MMP had a variety of underlying diseases (Table SI¹). Although various malignant tumours were found in 21 cases, there was no significant tendency in any of the underlying diseases.

Clinical features, treatments and prognoses. The presence and location of mucocutaneous lesions for 332 cases of BP180-MMP were then assessed (Table SII¹). All patients had mucosal lesions on various mucosae, while skin lesions were reported in 132 patients. Oral and ocular mucosal lesions were found in 284 and 97 patients, respectively, while other mucosae were involved less frequently.

Exclusive oral mucosal involvement was found in 106 cases, 32 of which showed lesions in single sites in oral mucosae. The gingivae were most frequently involved, followed by buccal mucosa and palate.

Ocular mucosal lesions were found in 97 cases, 16 of which showed only ocular lesions and were considered to have pure ocular MMP. Pharyngeal, laryngeal and genital mucosae were also involved, while nasal and oesophageal mucosal lesions were found less frequently. Skin lesions were mainly seen on the trunk and/or extremities.

Information about treatments was available for 184 patients from consultation letters regarding our serological studies (Table SIII¹). Topical steroids were given in 39 cases, 14 of which were treated as monotherapy. Systemic steroids were used in 97 cases, 60 of which were treated as monotherapy. A variety of other therapies, including combinations of tetracycline (minocycline) and nicotinamide, macrolides, diaminodiphenyl sulfone (DDS), immunosuppressive agents and others, were also performed. Steroid pulse therapy, intravenous immunoglobulins and plasmapheresis were used less frequently.

Only a few consulting letters contained sufficient information about response to treatments and prognoses, thus we could not study these aspects.

Immunological findings

Direct IF. Data were summarized only for immunoglobulins and C3 (Table SIV¹). A total of 108 (81.8%) of 132

cases showed IgG deposition to BMZ, 47 (66.2%) of 71 cases showed IgA deposition to BMZ, 14 (35%) of 40 cases showed IgM deposition to BMZ, and 110 (86.6%) of 127 cases showed C3 deposition to BMZ, indicating that C3 was deposited most prevalently. Deposition to epithelial and epidermal cell surfaces was rarely detected.

Indirect IF (Table SV¹). In indirect IF of normal human skin, 132 (41.4%) of 319 patients showed IgG anti-BMZ antibodies at titres from 10 to over 160, while 26 (9.1%) of 285 patients showed IgA anti-BMZ antibodies at titres from 10 to over 160 (Table SV¹). Antibodies to keratinocyte cell surfaces were rarely detected.

In ss-IIF, 207 (65.3%) and 62 (19.6%) of 317 patients showed IgG reactivity with epidermal and dermal sides, respectively, at titres from 10 to over 40, while 151 (53.5%) and 4 (1.4%) of 282 patients showed IgA reactivity with epidermal and dermal sides, respectively, at titres from 10 to over 40 (Table SV¹).

IB of substrates other than BP180 RPs for 332 cases of BP180-MMP. For most of the 332 cases of BP180-MMP, various IB and ELISA studies were performed at the time the sera were received.

In our IB studies of substrates other than BP180 RPs, IgG IB of normal human epidermal extract detected BP180 and BP230 in 45 and 38 cases, respectively, with rare reactivity with envoplakin, periplakin, Dsg1 and Dsg3 (data not shown). IB of concentrated culture supernatant of HaCaT cells showed positive reactivity with the 120 kDa LAD-1 in 37 cases for IgG antibodies and 19 cases for IgA antibodies. IgG IB of normal human dermal extract rarely detected type VII collagen or laminin-gamma-1 (p200).

Novel ELISA of BP180-C RP and results for various AIBD sera

For the novel ELISA of BP180-C RP, we first set cut-off values of mean +3 SD of the OD of 44 normal human sera for both IgG antibodies (0.269) and IgA antibodies (0.135) (Fig. 1a).

To define BP180-MMP cases more strictly, 252 sera from ss-IIF-epi(+) cases were examined 2 or 3 times by repeated BP180-C ELISA, which showed positive reactivity in 100 (39.7%) cases and 60 (23.8%) cases for IgG and IgA antibodies, respectively (Fig. 1).

Other AIBDs were then examined, including 89 BP sera, 80 LM332-MMP sera and 22 sera each of EBA, pemphigus vulgaris, pemphigus foliaceus and paraneoplastic pemphigus (Fig. 2). For IgG antibodies, although positive rates were lower than for BP180-MMP, a significant number of BP sera showed positive reactivity with BP180-C. In contrast, positive rates in LM332-MMP, EBA, pemphigus vulgaris, pemphigus foliaceus, and paraneoplastic pemphigus were significantly lower than that in BP180-MMP ($p < 0.05$). For

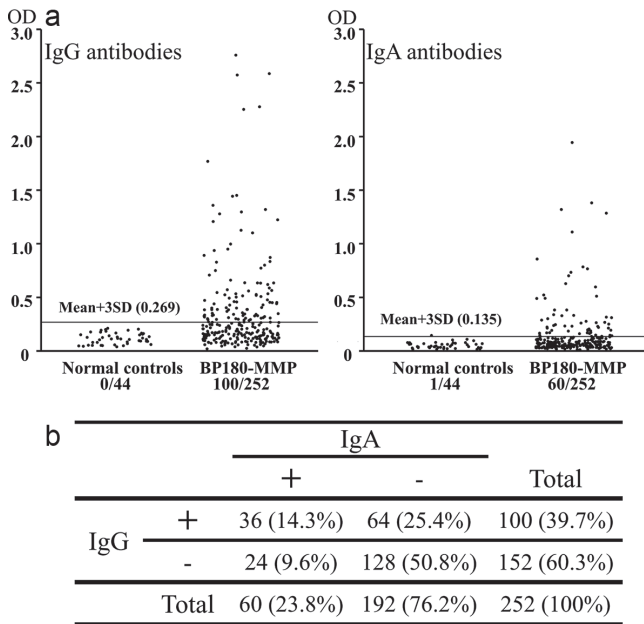


Fig. 1. Results of enzyme-linked immunosorbent assay (ELISA) of BP180-C recombinant protein (BP180-C RP) for 44 normal controls and 252 BP180-mucous membrane pemphigoid (BP180-MMP) sera. (a) Immunoglobulin (Ig)G and IgA antibodies. (b) Summary of all results for both IgG and IgA antibodies. OD: optical density; SD; standard deviation.

IgA antibodies, various AIBD sera showed positive reactivity only sporadically.

IB and ELISA studies of BP180 RPs for all cases of BP180-MMP (Table SVI¹). In IB and ELISA studies of BP180-NC16a and BP180-C RPs for IgG and IgA antibodies, approximately 43% of 332 cases of BP180-MMP reacted with BP180-C in both IB and ELISA, while approximately 27% of cases reacted with BP180-NC16a. Thus, approximately half of cases showed positive reactivity with BP180-C and/or BP180-NC16a

RPs. For IgA antibodies, BP180-C ELISA showed positive results in 27% cases, while other IB and ELISA studies were much less sensitive.

Confirmatory BP180-C ELISA and IB and ELISA of various substrates for 252 ssIIF-epi(+) BP180-MMP sera, as well as BP and LM332-MMP sera. To obtain convincing results, BP180-C ELISA was repeatedly performed for all the 252 BP180-MMP sera, whereas other studies were not performed in all cases (Table I).

In BP180-C ELISA, 100 (39.7%) and 60 (23.8%) of 252 BP180-MMP sera showed positive reactivity for IgG and IgA antibodies, respectively, while 38.7% and 5.5% of BP180-MMP sera showed positive reactivity for IgG and IgA antibodies, respectively, in BP180-C IB (Table I). Significant numbers of BP sera also showed positive reactivity in BP180-C IB for IgG antibodies and BP180-C ELISA for both IgG and IgA antibodies, whereas LM332-MMP sera reacted with BP180-C less frequently.

Approximately 30% of 252 BP180-MMP sera showed IgG, but not IgA, reactivity with BP180-NC16a RP in both IB and ELISA, although these rates were much lower than those in BP. LM332-MMP did not react with BP180-NC16a RP.

BP180-MMP sera also showed positive reactivity in BP230 ELISA, although the frequency was much less than for BP. Interestingly, approximately 30% of BP180-MMP sera, but not BP sera, showed positive reactivity in IB of purified human LM332 for both IgG and IgA antibodies.

Final serological diagnoses for all 332 cases of BP180-MMP. Final serological diagnoses were made for all cases of BP180-MMP, according to the positive reactivity in various antigen detection studies (Table SVII¹). In addition to BP180-MMP-related positive reactions,

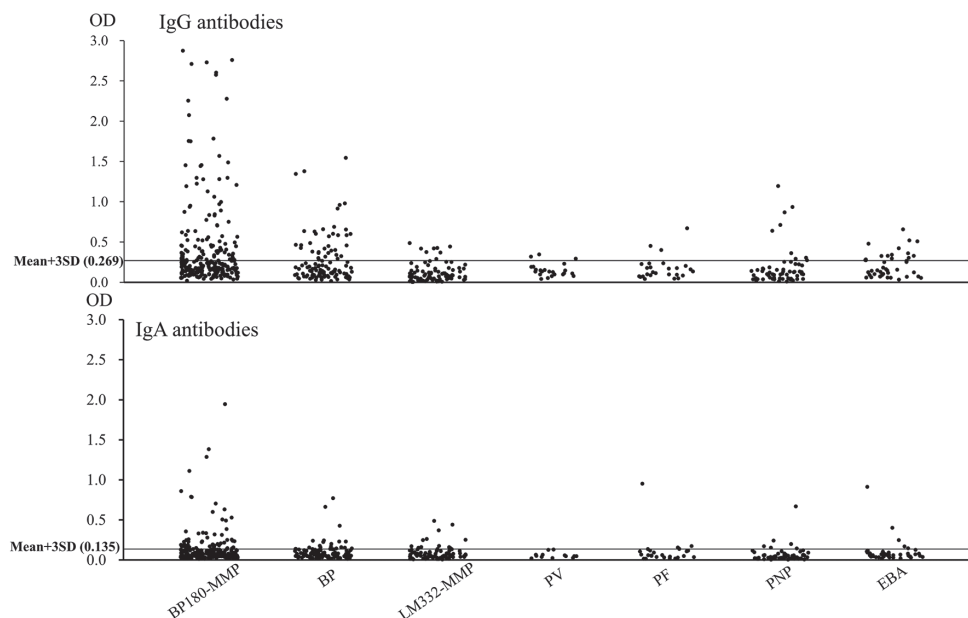


Fig. 2. Results of enzyme-linked immunosorbent assay (ELISA) of BP180-C recombinant protein (BP180-C RP) for disease control sera of various autoimmune bullous diseases (AIBDs), as well as BP180-mucous membrane pemphigoid (MMP) sera. PV: pemphigus vulgaris; PF: pemphigus foliaceus; PNP: paraneoplastic pemphigus; OD: optical density; SD; standard deviation; BP: bullous pemphigoid; EBA: epidermolysis bullosa acquisita.

Table I. Results of repeated enzyme-linked immunosorbent assay (ELISA) of BP180-C and immunoblotting (IB) and ELISA of various substrates in 252 ss-IIF-epi(+) BP180-MMP, BP and LM332-MMP cases

Methods	Substrates	ss-IIF-epi(+)		BP		LM332-MMP	
		BP180-MMP					
IB	BP180-C (IgG)	82/212	38.7%	13/75	17.3%	4/47	8.5%
	BP180-C (IgA)	9/165	5.5%	0/17	0.0%	0/28	0.0%
	BP180-NC16a (IgG)	71/246	28.9%	62/87	71.3%	1/56	1.8%
	BP180-NC16a (IgA)	4/181	2.2%	2/19	10.5%	0/26	0.0%
	LM332 (IgG)	58/187	31.0%	4/54	7.4%	75/75	100.0%
ELISA	LM332 (IgA)	6/18	33.3%	0/2	0.0%	3/8	37.5%
	BP180-C (IgG)	100/252	39.7%	26/89	29.2%	8/80	10.0%
	BP180-C (IgA)	60/252	23.8%	16/89	18.0%	13/80	16.3%
	BP180-NC16a (IgG)	69/224	30.8%	74/89	83.1%	1/63	1.6%
	BP180-NC16a (IgA)	0/7	0.0%	0/2	0.0%	0/3	0.0%
	BP230 (IgG)	13/198	6.6%	51/88	58.0%	2/55	3.6%
	BP230 (IgA)	1/6	16.7%	1/2	50.0%	0/3	0.0%

IIF: indirect immunofluorescence; BP: bullous pemphigoid; MMP: mucous membrane pemphigoid.

some sera showed positive reactions to various AIBD antigens, particularly with LM332, suggesting that BP180-MMP may have a tendency to concur with other AIBDs, particularly LM332-MMP.

DISCUSSION

By screening 4,698 cases of AIBD using the algorithm of our tentative diagnostic criteria, we made a diagnosis of BP180-MMP in 332 cases. The tentative criteria included patients who showed IgG/IgA reactivity with the epidermal side of NaCl-split-skin, but not with BP180 in biochemical studies. Therefore, such patients might react with other antigens, such as integrin alpha-6 and beta-4. Detection of these antigens is difficult, and the majority of patients with MMP are known to react with BP180. Therefore, in this study, we tentatively diagnosed the patients who met our criteria as BP180-MMP, and further characterized these patients. In this process, we also found 151 cases that were convincingly diagnosed as sole LM332-MMP.

Assessment of clinical findings revealed a female prevalence and a peak of disease onset at 60–80 years. Various internal malignancies were found in 21 cases of BP180-MMP. However, taking into account the high age of our BP180-MMP patients, this rate was not considered to suggest a significant relationship between BP180-MMP and internal malignancy, although previous studies revealed a strong association of LM332-MMP with internal malignancy (18).

Concerning clinical manifestations, oral mucosae, particularly gingivae, were most frequently involved, followed by ocular lesions. Cutaneous lesions were seen in 132 cases. These findings were compatible with those of previous reports (1–4). As therapeutic options, topical and systemic steroids were used most frequently, and tetracycline, minocycline and DDS were also used

in milder cases, meeting the recommendations of 2 consensus meetings (4, 5).

Concerning immunological studies, direct IF detected deposits of IgG, IgA and C3 in 81.8%, 66.2% and 86.6% of BP180-MMP cases, respectively, indicating that direct IF is still the most sensitive test for BP180-MMP. Both indirect IF of normal human skin and ss-IIF also detected IgG and IgA anti-BMZ antibodies in BP180-MMP, with higher frequencies for IgG antibodies. For both IgG and IgA antibodies, ss-IIF was much more sensitive than IF of normal human skin, suggesting superiority of ss-IIF for diagnosis of BP180-MMP.

In IB of substrates other than BP180 RPs, approximately 20% of BP180-MMP sera reacted with intact BP180 and/or LAD-1, which were useful to make a diagnosis of BP180-MMP (19). In addition, these tests showed that some BP180-MMP sera also reacted with BP230 and autoantigens of paraneoplastic pemphigus, EBA and anti-LM-gamma-1 (p200) pemphigoid.

In IB and ELISA studies of BP180 RPs, nearly 30% of BP180-MMP sera reacted with BP180-NC16a in both studies. This finding indicates that these tests for BP180-NC16a are also useful for the diagnosis of BP180-MMP in cases with mucosal dominant lesions, as suggested previously (6). However, the significance of anti-BP180-NC16a antibodies in BP180-MMP is currently unknown, because previous studies suggested that anti-BP180-C antibodies are pathogenic antibodies in BP180-MMP. We did not find any significant clinical difference between BP180-C-positive and BP180-NC16a-positive BP180-MMP.

Furthermore, to facilitate the diagnosis of BP180-MMP, we developed a novel ELISA of BP180-C RP. This BP180-C ELISA frequently showed positive reactivity for both IgG and IgA antibodies in BP180-MMP. The positive rates in BP180-C ELISA, particularly for IgA antibodies, were higher than those in BP180-C IB reported in previous studies (3, 6, 7).

A significant number of cases of BP also showed positive reactivity in BP180-C ELISA. In contrast, normal sera and disease control sera of other AIBDs rarely showed positive results. Therefore, the BP180-C ELISA was considered to be a very sensitive and specific method, not only in BP180-MMP, but also in BP.

As mentioned above, our biological and molecular biological tests showed that the sera of some patients with BP180-MMP, which were diagnosed using tentative diagnostic criteria, reacted with various AIBD autoantigens, in addition to BP180-related proteins. These findings may indicate that BP180-MMP tends to concur with other AIBDs. In particular, IgG and/or

IgA antibodies against various subunits of LM332 were detected in 54 of 332 cases of BP180-MMP. Thus, the 2 major types of MMP may concur by unknown mechanisms. However, it is also possible to speculate that development of autoantibodies to LM332 in BP180-MMP was a non-pathogenic epiphenomenon, presumably via epitope spreading from BP180-C to LM332, because BP180-C binds to LM332 in epidermal BMZ (20).

Conversely, approximately 10% of 47 control sole LM332-MMP sera showed positive IgG and/or IgA reactivity in BP180-C ELISA. This reactivity may also be caused via epitope spreading phenomenon from LM332 to BP180-C.

In conclusion, this large systemic study of BP180-MMP clinically revealed a female predominance, preferential involvement of oral mucosae and effectiveness of tetracycline/minocycline and DDS. Immunological studies showed the diagnostic usefulness of our novel BP180-C ELISA, while the concurrent detection of non-BP180 antigens emphasized the difficulty of diagnosing BP180-MMP.

ACKNOWLEDGEMENTS

The authors would like to thank Ms Tomoko Tashima for secretarial work and Dr Zhuxiang Nie for his critical reading of the manuscript. The authors also thank the patients for their participation. This study was supported by Grants-in-Aid for Scientific Research and Strategic Research Basis Formation Supporting Project from the Ministry of Education, Culture, Sports, Science and Technology of Japan, and by Health and Labour Sciences Research Grants and the grants for Research on Measures for Intractable Diseases from the Ministry of Health, Labour and Welfare of Japan. The study was also supported by grants from the Uehara Memorial Foundation, the Nakatomi Foundation, the Japan Lydia O'Leary Memorial Foundation, and the Japanese Dermatological Association (Shiseido Award).

The authors declare no conflicts of interest.

REFERENCES

1. Hashimoto T, Ishii N, Ohata C, Furumura M. Pathogenesis of epidermolysis bullosa acquisita, an autoimmune subepidermal bullous disease. *J Pathol* 2012; 228: 1–7.
2. Matsumura K, Amagai M, Nishikawa T, Hashimoto T. The majority of bullous pemphigoid and herpes gestationis serum samples react with the NC16a domain of the 180-kDa bullous pemphigoid antigen. *Arch Dermatol Res* 1996; 288: 507–509.
3. Nie Z, Hashimoto T. IgA antibodies of cicatricial pemphigoid sera specifically react with C-terminus of BP180. *J Invest Dermatol* 1999; 112: 254–255.
4. Chan LS, Ahmed AR, Anhalt GJ, Bernauer W, Cooper KD, Elder MJ, et al. The first international consensus on mucous membrane pemphigoid: definition, diagnostic criteria, pathogenic factors, medical treatment, and prognostic indicators. *Arch Dermatol* 2002; 138: 370–379.
5. Murrell DF, Marinovic B, Caux F, Prost C, Ahmed R, Wozniak K, et al. Definitions and outcome measures for mucous membrane pemphigoid: recommendations of an international panel of experts. *J Am Acad Dermatol* 2015; 72: 168–174.
6. Hayakawa T, Furumura M, Fukano H, Li X, Ishii N, Hamada T, et al. Diagnosis of oral mucous membrane pemphigoid by means of combined serologic testing. *Oral Surg Oral Med Oral Pathol Oral Radiol* 2014; 117: 483–496.
7. Fukuda A, Himejima A, Tsuruta D, Koga H, Ohyama B, Morita S, et al. Four cases of mucous membrane pemphigoid with clinical features of oral lichen planus. *Int J Dermatol* 2015 Sep 4. [Epub ahead of print].
8. Domloge-Hultsch N, Gammon WR, Briggaman RA, Gil SG, Carter WG, Yancey KB. Epiligrin, the major human keratinocyte integrin ligand, is a target in both an acquired autoimmune and an inherited subepidermal blistering skin disease. *J Clin Invest* 1992; 90: 1628–1633.
9. Lazarova Z, Yee C, Darling T, Briggaman RA, Yancey KB. Passive transfer of anti-laminin 5 antibodies induces subepidermal blisters in neonatal mice. *J Clin Invest* 1996; 98: 1509–1518.
10. Miyamoto S, Chikazu D, Yasuda T, Enomoto A, Oh-i T, Hirako Y, et al. A case of oral mucous membrane pemphigoid with IgG antibodies to integrin alpha6beta4. *Br J Dermatol* 2014; 171: 1555–1557.
11. Solano-Lopez G, Concha-Garzon MJ, Sanchez-Perez J, Hirako Y, Li X, Ishii N, et al. Pure ocular mucous membrane pemphigoid reactive with both beta4 integrin and the BP180 C-terminal domain. *Br J Dermatol* 2015; 172: 542–544.
12. Sugi T, Hashimoto T, Hibi T, Nishikawa T. Production of human monoclonal anti-basement membrane zone (BMZ) antibodies from a patient with bullous pemphigoid (BP) by Epstein-Barr virus transformation. Analyses of the heterogeneity of anti-BMZ antibodies in BP sera using them. *J Clin Invest* 1989; 84: 1050–1055.
13. Hashimoto T, Ogawa MM, Konohana A, Nishikawa T. Detection of pemphigus vulgaris and pemphigus foliaceus antigens by immunoblot analysis using different antigen sources. *J Invest Dermatol* 1990; 94: 327–331.
14. Ishii N, Ohyama B, Yamaguchi Z, Hashimoto T. IgA autoantibodies against the NC16a domain of BP180 but not 120-kDa LAD-1 detected in a patient with linear IgA disease. *Br J Dermatol* 2008; 158: 1151–1153.
15. Csorba K, Schmidt S, Florea F, Ishii N, Hashimoto T, Hertl M, et al. Development of an ELISA for sensitive and specific detection of IgA autoantibodies against BP180 in pemphigoid diseases. *Orphanet J Rare Dis* 2011; 6: 31.
16. Ishii N, Yoshida M, Hisamatsu Y, Ishida-Yamamoto A, Nakane H, Iizuka H, et al. Epidermolysis bullosa acquisita sera react with distinct epitopes on the NC1 and NC2 domains of type VII collagen: study using immunoblotting of domain-specific recombinant proteins and postembedding immunoelectron microscopy. *Br J Dermatol* 2004; 150: 843–851.
17. Hisamatsu Y, Nishiyama T, Amano S, Matsui C, Ghohestani R, Hashimoto T. Usefulness of immunoblotting using purified laminin 5 in the diagnosis of anti-laminin 5 cicatricial pemphigoid. *J Dermatol Sci* 2003; 33: 113–119.
18. Demitsu T, Yoneda K, Iida E, Sasaki K, Umemoto N, Kakurai M, et al. A case of mucous membrane pemphigoid with IgG antibodies against all the alpha3, beta3 and gamma2 subunits of laminin-332 and BP180 C-terminal domain, associated with pancreatic cancer. *Clin Exp Dermatol* 2009; 34: e992–e994.
19. Hirakawa Y, Oiso N, Ishii N, Koga H, Tatebayashi M, Uchida S, et al. Mucous membrane pemphigoid with IgG autoantibodies to the 120-kDa ectodomain of type XVII collagen (BP180/linear IgA dermatosis antigen) in a patient with idiopathic thrombocytopenic purpura. *Acta Derm Venereol* 2015; 95: 493–494.
20. Sugawara K, Tsuruta D, Kobayashi H, Ikeda K, Hopkinson SB, Jones JC, et al. Spatial and temporal control of laminin-332 (5) and -511 (10) expression during induction of anagen hair growth. *J Histochem Cytochem* 2007; 55: 43–55.