

SHORT COMMUNICATION

A 45-year-old Woman with Ehlers-Danlos Syndrome Caused by Dermatan 4-*O*-sulfotransferase-1 Deficiency: Implications for Early Ageing

Michihiro Kono^{1*}, Yoshie Hasegawa-Murakami¹, Kazumitsu Sugiura¹, Masashi Ono², Kazuhiro Toriyama², Noriko Miyake³, Atsushi Hatamochi⁴, Yuzuru Kamei², Tomoki Kosho^{5*} and Masashi Akiyama¹

Departments of ¹Dermatology and ²Plastic and Reconstructive Surgery, Nagoya University Graduate School of Medicine, 65 Tsurumai-cho, Showa-ku, Nagoya, 466-8550, ³Department of Human Genetics, Yokohama City University Graduate School of Medicine, Yokohama, ⁴Department of Dermatology, Dokkyo Medical University, School of Medicine, Mibu, and ⁵Department of Medical Genetics, Shinshu University School of Medicine, Matsumoto, Japan.

*E-mails: miro@med.nagoya-u.ac.jp; ktomoki@shinshu-u.ac.jp

Accepted Feb 29, 2016; Epub ahead of print Mar 1, 2016

Ehlers-Danlos syndrome (EDS) is a heterogeneous group of connective tissue disorders characterized by joint and skin laxity and tissue fragility (1). Dermatan 4-*O*-sulfotransferase-1 (D4ST1) deficiency, a recently delineated form of EDS caused by bi-allelic loss-of-function mutations in the carbohydrate sulfotransferase 14 gene (*CHST14*), is clinically characterized by multiple congenital malformations (craniofacial abnormalities, multiple congenital contractures, congenital heart/eye/gastrointestinal defects) and progressive fragility-related manifestations (skin hyperextensibility and fragility, large subcutaneous haematomas, recurrent dislocations, progressive skeletal deformities) (2). Biochemical and pathological investigations on patients' skin specimens suggest multisystem fragility caused by impaired assembly of collagen fibrils resulting from dermatan sulphate (DS) depletion in the decorin glycosaminoglycan (GAG) side chain (2). The disorder is currently called "EDS musculocontractural type 1" (MIM#601776) or "D4ST1-deficient EDS" (2). We report here a 45-year-old Japanese woman with the disorder.

CASE REPORT

At birth, the patient had talipes equinovarus, resulting in progressive foot deformities and difficulty walking. She had hyperextensible, easily bruisable, fragile skin. Thus, she was suspected of having general EDS. She presented congenital optic nerve atrophy of the right eye, leading to blindness. Hearing impairment was noted. After arthrodesis for bilateral talipes equinovarus at age 5 years, she was able to walk independently. At age 17, she had a right hip dislocation. At age 18, hair loss occurred on the frontal region. At age 24, she developed bacterial endocarditis, resulting in mitral valve insufficiency, and underwent mitral valvuloplasty. At age 30, she had colon diverticulitis. At age 36, she had retinal detachment, glaucoma and cataract of the left eye. At age 41, she had a left hip joint dislocation, during the reposition of which a large subcutaneous haematoma developed along the left lower leg, resulting in skin necrosis. It was then that she was referred to our department of the hospital for further examination.

At initial examination we diagnosed the patient as having general EDS because of skin hyperextensibility and joint hypermobility. Hydronephrosis and nephrolithiasis, detected at age 40 years, were followed by pyelonephritis at age 44 years. When last seen by us at age 45 years, her height was 147 cm (−2.0 standard deviation (SD)) and her weight was 38 kg (−2.3 SD). She had characteristic facial features, including an asymmetrical shaped face, hypertelorism, short and downslanting palpebral

fissures, strabismus, a short nose with hypoplastic columella and a long philtrum with a thin upper lip vermilion; she looked old for her age, with sparse hair on the forehead (Fig. 1a). She had tapering fingers and wrinkled palmar creases (Fig. 1b, c). Her skin was hyperextensible and redundant and her small joints were hypermobile (Fig. 1e, f). Her left lower leg was covered with hypertrophic scars resulting from skin grafts (Fig. 1f). She was unable to walk independently because of progressive foot deformities (Fig. 1f) and she used a walker or wheelchair for mobility. Personal photographs illustrate the patient's physical development over 0–26 years of age (Fig. S1 g–l).

Microscopic investigations of a skin biopsy specimen from the medial side of the arm were performed. Light microscopy revealed the following: fine collagen fibres were predominant in the reticular to the papillary dermis, normally thick collagen bundles were markedly reduced in the reticular dermis (Fig. S2a¹) and elastic fibres were relatively increased in the dermis (Fig. S2b¹). Electron microscopy revealed insufficiently assembled collagen fibrils (Fig. S2d¹).

Direct sequencing of *CHST14* on genomic DNA extracted from her peripheral blood leukocytes revealed 2 compound heterozygous mutations that had both been reported in Japanese patients with EDS caused by D4ST1 deficiency (2): c.626T>C and c.842C>T (p.(Phe209Ser)) and (p.(Pro281Leu)) (Fig. S2e, f¹). Both mutations of p.F209S and p.P281L were deduced to be probably damaging by PolyPhen-2 and deleterious by SIFT. The diagnosis was confirmed as EDS caused by D4ST1 deficiency.

DISCUSSION

The clinical features and course of this patient, especially the characteristic craniofacial and cutaneous appearance that suggested early ageing, as well as the progressive skeletal, vascular, ocular, and visceral complications, raise the possibility of a relationship between DS depletion and early ageing. Of the 39 patients with the disorder described to date, including the recent series by Janecke et al. (3) and the present patient, 6 were reported to be older than 30 years at their latest publication (3–5). Four of the 5 whose facial photographs were available showed "aged looking" craniofacial and cutaneous appearances, such as sparse hair and progressively wrinkled palmar creases. Three were unable to walk independently due to foot deformities or recurrent large subcutaneous haematomas. Three had gastrointestinal diverticulitis associated with perforation

¹<http://www.medicaljournals.se/acta/content/?doi=10.2340/00015555-2390>

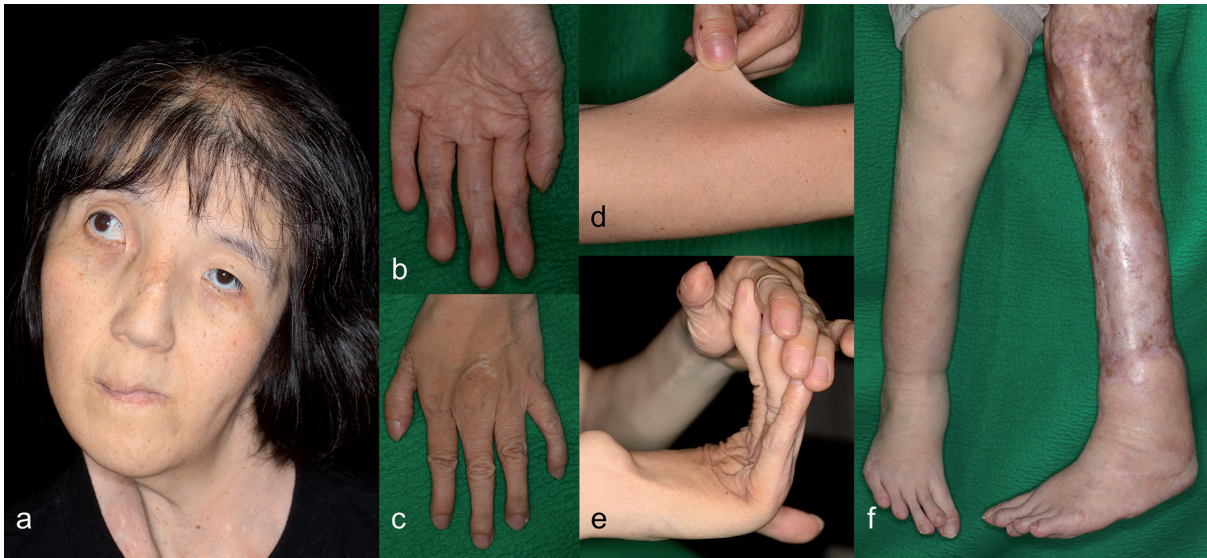


Fig. 1. Clinical photographs at age 45 years. (a) Facial features include an asymmetrical shaped face, hypertelorism, short and downslanting palpebral fissures, strabismus, a short nose with hypoplastic columella and a long philtrum with a thin upper lip vermilion. (b) Wrinkled palmar creases on the left hand. (c) Tapering fingers of the left hand, with clinodactyly. (d) Skin hyperextensibility on the forearm. (e) Joint hypermobility of the fingers. (f) Bilateral foot deformities and scar formation after skin necrosis on the left lower leg. Written permission was obtained from the patient to publish these photographs.

in 2 of the 3, and 2 had (haemo)pneumothorax. Three developed retinal detachment and 1 severe glaucoma, resulting in blindness in 2 of them. One died at age 59 years from intracranial haemorrhage after a fall (5).

Ageing is a natural, continuous process associated with progressive structural, functional, and metabolic changes in various tissues and systems. Parts integral to this process have been shown to be structural and functional alterations in extracellular matrix components, including GAGs (6). Linear age-related declines in plasma DS, chondroitin sulphate (CS), and heparan sulphate/heparin were demonstrated in healthy individuals (7). Furthermore, the progeroid form of EDS was found to be caused by loss-of-function mutations in *B4GALT7* or *B3GALT6*, both encoding galactosyltransferases that form a tetrasaccharide linker region indispensable to the initiation of CS/DS biosynthesis (8–10).

In conclusion, we have described an additional middle-aged patient with EDS caused by D4ST1 deficiency, whose “aged looking” craniofacial and cutaneous appearance and progressive multisystem complications suggest that DS depletion could be involved in early ageing.

ACKNOWLEDGEMENTS

Funding sources: Practical Research Project for Rare/Intractable Diseases, Japan Agency for Medical Research and Development (AMED) (#105) (KT). Grant-in-Aid for Scientific Research (C) from the Ministry of Education, Culture, Sports, Science and Technology of Japan (#25460405) (KT).

REFERENCES

1. Beighton P, De Paepe A, Steinmann B, Tsipouras P, Wenstrup RJ. Ehlers-Danlos syndromes: revised nosology, Villefranche, 1997. Ehlers-Danlos National Foundation (USA) and Ehlers-Danlos Support Group (UK). *Am J Med Genet* 1998; 77: 31–37.
2. Kosho T. CHST14/D4ST1 deficiency: A new form of Ehlers-Danlos syndrome. *Pediatr Int* 2016; 58: 88–99.
3. Janecke AR, Li B, Boehm M, Krabichler B, Rohrbach M, Muller T, et al. The phenotype of the musculocontractural type of Ehlers-Danlos syndrome due to CHST14 mutations. *Am J Med Genet A* 2016; 170A: 103–115.
4. Kosho T, Miyake N, Hatamochi A, Takahashi J, Kato H, Miyahara T, et al. A new Ehlers-Danlos syndrome with craniofacial characteristics, multiple congenital contractures, progressive joint and skin laxity, and multisystem fragility-related manifestations. *Am J Med Genet A* 2010; 152A: 1333–1346.
5. Syx D, Van Damme T, Symoens S, Maiburg MC, van de Laar I, Morton J, et al. Genetic heterogeneity and clinical variability in musculocontractural Ehlers-Danlos syndrome caused by impaired dermatan sulfate biosynthesis. *Hum Mutat* 2015; 36: 535–547.
6. Bailey AJ. Molecular mechanisms of ageing in connective tissues. *Mech Ageing Dev* 2001; 122: 735–755.
7. Komosinska-Vassev K, Olczyk P, Winsz-Szczotka K, Klimek K, Olczyk K. Plasma biomarkers of oxidative and AGE-mediated damage of proteins and glycosaminoglycans during healthy ageing: a possible association with ECM metabolism. *Mech Ageing Dev* 2012; 133: 538–548.
8. Kresse H, Rosthoj S, Quentin E, Hollmann J, Glossl J, Okada S, et al. Glycosaminoglycan-free small proteoglycan core protein is secreted by fibroblasts from a patient with a syndrome resembling progeroid. *Am J Hum Genet* 1987; 41: 436–453.
9. Malfait F, Kariminejad A, Van Damme T, Gauche C, Syx D, Merhi-Soussi F, et al. Defective initiation of glycosaminoglycan synthesis due to B3GALT6 mutations causes a pleiotropic Ehlers-Danlos-syndrome-like connective tissue disorder. *Am J Hum Genet* 2013; 92: 935–945.
10. Nakajima M, Mizumoto S, Miyake N, Kogawa R, Iida A, Ito H, et al. Mutations in B3GALT6, which encodes a glycosaminoglycan linker region enzyme, cause a spectrum of skeletal and connective tissue disorders. *Am J Hum Genet* 2013; 92: 927–934.