

SHORT COMMUNICATION

Epididymitis with Epididymal Cyst Indicating Immunoglobulin A Vasculitis in an Adult

Ai Nanbu¹, Kazumitsu Sugiura^{1*}, Naoto Sassa² and Masashi Akiyama¹Departments of ¹Dermatology and ²Urology, Nagoya University Graduate School of Medicine, 65 Tsurumai-cho, Showa-ku, Nagoya 466-8550, Japan.

*E-mail: kazusugi@med.nagoya-u.ac.jp

Accepted Feb 24, 2016; Epub ahead of print Feb 26, 2016

Immunoglobulin A (IgA) vasculitis, also known as anaphylactoid purpura or Henoch–Schönlein purpura, is a type of systemic non-thrombocytopenic vasculitis. Patients with IgA vasculitis often have arthritis with involvement of the gastrointestinal tract and kidney (1). Genitourinary involvement in IgA vasculitis is fairly common in children, but is rarely seen in adults. We report here a case of IgA vasculitis accompanied by epididymitis with epididymal cysts.

malignancy on contrast-enhanced CT. Ultrasonography and colour Doppler imaging of the scrotal sac also showed bilateral enlargement of the epididymis, and epididymal cyst, with normal blood flow to the testis. Subsequently, an epididymal cyst appeared on the cranial side of the right testis (Fig. 1E). A diagnosis of IgA vasculitis was made in accordance with the 2012 revised Chappell Hill classification (2). We considered that the epididymitis with the epididymal cysts in the present case was an inflammatory reaction associated with IgA vasculitis, because the epididymis symptom was synchronous with other systemic symptoms and did not respond to antibiotic treat-

CASE REPORT

A 35-year-old man was referred to our hospital with swelling and pain of both feet. The dorsa of his right foot had swelled suddenly with acute pain and flare 14 days before his visit. Since then he had also experienced bilateral scrotal pain. One day later, similar swelling and flare appeared on his left foot. He then visited a hospital and was treated with intravenous and oral antibiotics. However, the bilateral swelling of the feet, ankles, and lower legs worsened. Thus, he was referred and admitted to our hospital. Physical examination showed palpable purpura on both legs, and swelling, erythema, and warmth on both ankles (Fig. 1A). He also had painful bilateral swelling of the scrotum. He reported that the purpura on both legs had appeared before he felt scrotal pain. Moreover, he had no abdominal symptoms. Histopathology of a punch biopsy specimen from the thigh revealed capillaries and venules of the dermis affected by leukocytoclastic vasculitis (Fig. 1B). Direct immunofluorescence staining showed small amounts of IgA and C3 deposits on the wall of the small vessels (Fig. 1C). Laboratory investigations revealed a white blood cell count of 21,000/ μ l, absolute neutrophil count of 17,000/ μ l, haemoglobin level of 11.3 g/dl, and platelet count of 533,000/ μ l. C-reactive protein increased to 23.5 mg/dl and serum IgA level to 424 mg/dl. Serum electrolytes, serum anti-streptolysin O, serum creatinine, and blood coagulation tests showed normal results. Haemolytic *Streptococcus* detection through a throat culture and blood cultures was negative. Rheumatoid factor, antinuclear antibody, antineutrophil cytoplasmic antibodies p-ANCA and c-ANCA, and hepatitis B and C serology were also negative. Urinalysis showed low-grade proteinuria. Microscopic haematuria was not detected. We performed contrast-enhanced computed tomography (CT) to detect systemic complications and involvement of other organs. Contrast-enhanced CT images revealed bilateral enlargement of the epididymis and an epididymal cyst on the cranial side of the left testis with swelling of the para-aortic lymph nodes (Fig. 1D). There were no nodules to indicate suspected internal

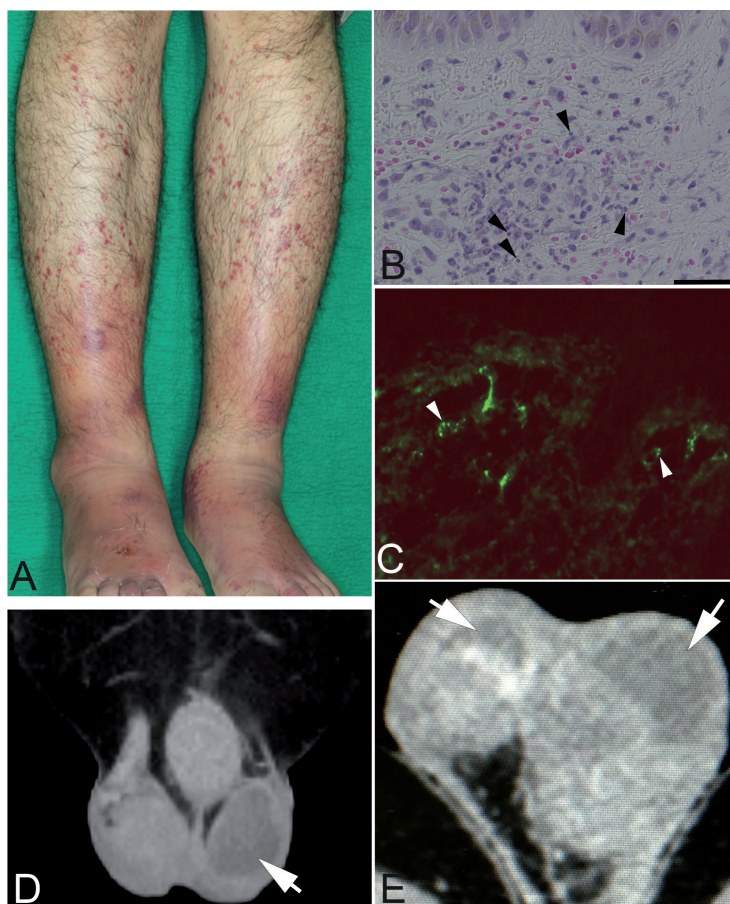


Fig. 1. Clinical features, pathological findings of the purpura, and contrast-enhanced computed tomography image of the epididymis of the patient. (A) Purpura was seen on both legs. Swelling was observed on both ankles. (B) Leukocytoclastic vasculitis (arrow heads) was observed in the superficial dermis in the skin biopsy samples from the purpura on the left thigh (haematoxylin & eosin staining, bar: 40 μ m). (C) Small amounts of IgA deposits (arrow heads) were observed on the wall of the small vessels by direct immunofluorescence staining, original magnification \times 400. (D) An epididymal cyst (arrow) was observed in the left epididymis. (E) Subsequently, another epididymal cyst (arrow) was observed in the right epididymis.

ments. Initially we only observed the patient, who was treated conservatively, with bed rest and non-steroid anti-inflammatory drugs for arthritis. The laboratory abnormalities, bilateral ankle joint arthritis, and scrotal pain improved gradually, and proteinuria disappeared in one week. The purpura resolved in 2 weeks. However, the swelling and scrotal cyst did not improve significantly, and C-reactive protein values did not decrease to within the normal range. Twenty-four days after the onset of the purpura, we started oral prednisolone (20 mg/day). Within about 2 weeks, the patient's joint pain and scrotal swelling disappeared. The patient did not show relapse of purpura after he stopped taking prednisolone. To date, we have followed the patient for one year, but he has not shown any evidence to suggest internal malignancies.

DISCUSSION

Allen et al. first reported a case of IgA vasculitis in a boy with testicular and scrotal haemorrhage in 1960 (1). Since then, many paediatric cases with scrotal involvement have been reported, and the reported incidence of scrotal manifestation with IgA vasculitis ranges from 2% to 38% (3). However, genital involvement is unusual in adults and, to our knowledge, only 4 cases have been reported to date (4–7). It is not known why genital involvement is uncommon in adults with IgA vasculitis. We summarized the clinical features of the previously reported adult cases with genitourinary organ involvement, including the present case, in Table S1¹. Scrotal symptoms sometimes preceded other manifestations of IgA vasculitis. In some paediatric cases, genitourinary abnormalities improved only with conservative treatment, while systemic steroid treatment was successfully administered in all adult cases with genitourinary involvement, except in one case (Case 1 in Table S1¹). In the present case, we also used oral prednisone and achieved immediate improvement.

Epididymitis is also a commonly recognized presentation of polyarteritis nodosa (PAN). Testicular involve-

ment is one of the American College of Rheumatology diagnostic criteria for PAN (8). In our case, remarkable elevation of C-reactive protein and leukocytosis indicated a strong systemic inflammatory reaction. Moreover, the present patient also had moderate arthritis, scrotal pain, and extensive purpura. Initially, we included PAN in the differential diagnosis, although the diagnosis of IgA vasculitis was finally established on the basis of serological and histopathological findings.

In conclusion, the present case suggests that genitourinary involvement, including epididymitis and epididymal cyst, should always be considered as important extracutaneous symptoms of IgA vasculitis, even in adult cases.

REFERENCES

1. Allen DM, Diamond LK, Howell DA. Anaphylactoid purpura in children (Schonlein-Henoch syndrome): review with a follow-up of the renal complications. *AMA J Dis Child* 1960; 99: 833–854.
2. Jennette JC, Falk RJ, Bacon PA, Basu N, Cid MC, Ferrario F, et al. 2012 revised International Chapel Hill Consensus Conference Nomenclature of Vasculitides. *Arthritis Rheum* 2013; 65: 1–11.
3. Clark WR, Kramer SA. Henoch-Schonlein purpura and the acute scrotum. *J Pediatr Surg* 1986; 21: 991–992.
4. Sakanoue M, Higashi Y, Kawai K, Sugita S, Kanekura T. Henoch-Schonlein purpura with epididymitis in an adult. *J Dermatol* 2011; 38: 620–622.
5. Weimer CE, Jr., Sahn EE. Follicular accentuation of leukocytoclastic vasculitis in an HIV-seropositive man. Report of a case and review of the literature. *J Am Acad Dermatol* 1991; 24: 898–902.
6. Aaron S, Al-Watban L, Manca D. Scrotal involvement in an adult with Henoch-Schonlein purpura. *Clin Rheumatol* 2013; 32: S93–95.
7. Bachmeyer C, Bourgou Z, Benjoar M, Langman B, Hannonna A, Guillevin L. Spermatic pedicle inflammation as the initial sign of Henoch-Schonlein purpura. *J Rheumatol* 2012; 39: 2041–2042.
8. Lightfoot RW, Jr., Michel BA, Bloch DA, Hunder GG, Zvaifler NJ, McShane DJ, et al. The American College of Rheumatology 1990 criteria for the classification of polyarteritis nodosa. *Arthritis Rheum* 1990; 33: 1088–1093.

¹<https://doi.org/10.2340/00015555-2382>