

SHORT COMMUNICATION

Acute Generalized Exanthematous Pustulosis Secondary to Acyclovir Confirmed by Positive Patch Testing

Minna E. Kubin, Päivi Jackson and Riitta Riekkö

Department of Dermatology, Oulu University Hospital and University of Oulu, Kajaanintie 50, FIN-90029 Oulu, Finland. E-mail: minna.kubin@ppshp.fi
Accepted Feb 1, 2016; Epub ahead of print Feb 2, 2016

Acute generalized exanthematous pustulosis (AGEP) is a severe, almost exclusively drug-induced reaction pattern mediated by T cells. It presents with oedematous erythema, followed by dozens of small non-follicular sterile pustules with widespread distribution. Skin symptoms typically appear after 1–5 days of treatment and are almost always accompanied by fever and leukocytosis. The clinical course is characterized by acute onset and spontaneous resolution over a period of 15 days. The use of antibacterial drugs, i.e. aminopenicillins, is mainly associated with AGEP (1–3).

CASE REPORT

A 44-year-old woman was referred to our clinic due to eczema herpeticum. She had a history of atopic dermatitis and herpes labialis, but was otherwise healthy and was not on any ongoing medication. She had developed symptoms of labial herpes and started topical therapy for 5 days with acyclovir (Zovirax®), but the skin symptoms of labial herpes spread wider on the face and per oral acyclovir (200 mg 5 times a day for 5 days) was initiated. After one day's treatment, she developed erythema with small pustules symmetrically on the trunk and proximal aspects of both upper and lower limbs (Fig. 1a). She was hospitalized for possible herpes infection and clinical suspicion of AGEP and topical and symptomatic therapies (steroid cream, per oral cephalexin), were started. The skin symptoms were accompanied by leukocytosis and low-grade fever. A

4-mm punch biopsy was taken from her upper left arm, revealing histological features symptomatic of AGEP and confirming the clinical diagnosis (Fig. 2).

Patch tests were later carried out with the standard series, cosmetic series, acyclovir at concentrations up to 10% pet. and famciclovir, following the guidelines of the European Society of Contact Dermatitis (4). Strong positive reactions (++) to fragrance mix 1 and acyclovir at concentrations of 1%, 5% and 10% pet. were observed (Fig. 1b). There was no reaction to famciclovir, and prick test for famciclovir was negative.

Acyclovir was tested on 15 controls with negative results. The patient was diagnosed as having had AGEP secondary to acyclovir use. The AGEP validation score of the EuroSCAR (European Study of Severe Cutaneous Adverse Reactions) study group (1) was 8 and diagnosis of AGEP was considered definite.

DISCUSSION

Systemic acyclovir is considered to be an effective and safe drug; severe cutaneous adverse events remain anecdotal (5–7). To the best of our knowledge, only one case of AGEP related to acyclovir has been reported previously (6). According to the literature (7, 8), cross-reactions with famciclovir and valaciclovir are possible. This could be due to the close structural similarity of these drugs.

AGEP has previously been associated with viral infections, but as the EuroSCAR study revealed, in-

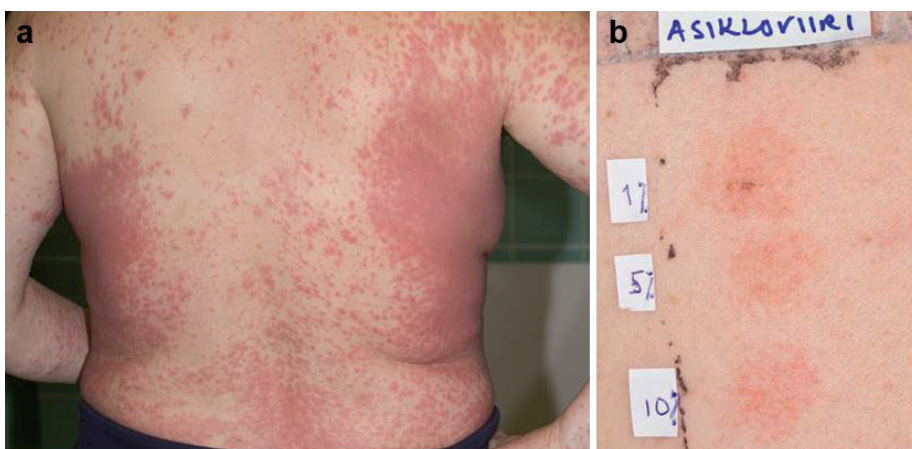

Fig. 1. (a) Symmetrically distributed small pustules on an erythematous base were observed. (b) Positive patch testing with acyclovir (asikloviiri) showing small localized pustules at concentrations 1%, 5% and 10% pet.

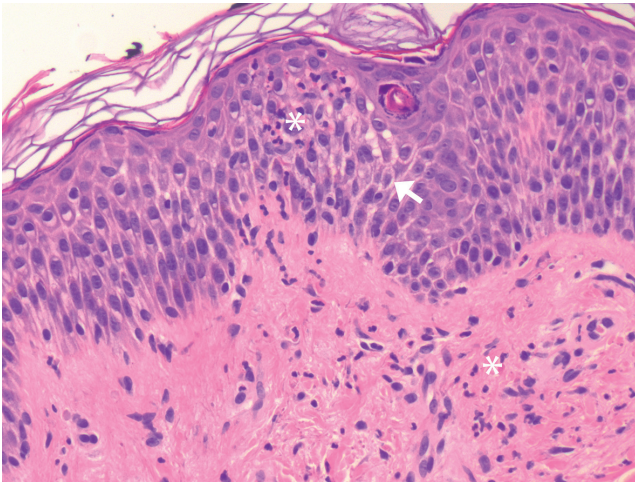


Fig. 2. Skin biopsy showing both intraepidermal and dermal neutrophils (asterisks) and spongiosis (arrow). Since biopsy was taken from an early lesion, intraepidermal pustule was not yet fully formed ($\times 20$).

fections, although serving as possible triggers, play no prominent role (9). Eczema herpeticum remained a differential diagnosis in the case reported, primarily because anamnesis revealed a prior attack of eczema herpeticum some years previously; however, it was excluded by negative swab sample culturing.

In conclusion, we report here a patient with AGEP secondary to acyclovir therapy confirmed by positive patch testing. The patient was instructed to avoid acyclovir and valacyclovir. Famciclovir was tested with negative results, but this cannot entirely rule out possible clinical cross-reactions. Foscarnet and cidofovir have been recommended in the literature as an optional treatment. However, these medications are available only in intravenous form and their price is considerably higher than acyclovir tablets. Adverse drug reaction should be

kept in mind as a rare, but possible, event when using acyclovir preparations, which are otherwise very safe.

ACKNOWLEDGEMENTS

The authors are grateful for the technical assistance of Ms Nina Kokkonen and Mr Juha Väyrynen.

The authors declare no conflicts of interest.

REFERENCES

1. Fernando SL. Acute generalised exanthematous pustulosis. *Australas J Dermatol* 2012; 53: 87–92.
2. Halevy S. Acute generalized exanthematous pustulosis. *Curr Opin Allergy Clin Immunol* 2009; 9: 322–328.
3. Szatkowski J, Schwartz RA. Acute generalized exanthematous pustulosis (AGEP): a review and update. *J Am Acad Dermatol* 2015; 73: 843–848.
4. Barbaud A, Gonçalo M, Bruynzeel D, Bircher A; European Society of Contact Dermatitis. Guidelines for performing skin tests with drugs in the investigation of cutaneous adverse drug reactions. *Contact Dermatitis* 2001; 45: 321–328.
5. Robinson GE, Weber J, Griffiths C, Underhill GS, Jeffries DJ, Goldmeir D. Cutaneous adverse reactions to acyclovir: case reports. *Genitourin Med* 1985; 61: 62–63.
6. Serra D, Ramos L, Brinca A, Gonçalo M. Acute generalized exanthematous pustulosis associated with acyclovir, confirmed by patch testing. *Dermatitis* 2012; 23: 99–100.
7. Vernassiere C, Barbaud A, Trechot PH, Weber-Muller F, Schmutz JL. Systemic acyclovir reaction subsequent to acyclovir contact allergy: which systemic antiviral drug should then be used? *Contact Dermatitis* 2003; 49: 155–157.
8. Lammintausta K, Mäkela L, Kalimo K. Rapid systemic valaciclovir reaction subsequent to aciclovir contact allergy. *Contact Dermatitis* 2001; 45: 181.
9. Sidoroff A, Dunant A, Viboud C, Halevy S, Bavinck JN, Naldi L, et al. Risk factors for acute generalized exanthematous pustulosis (AGEP) – results of a multinational case-control study (EuroSCAR). *Br J Dermatol* 2007; 157: 989–996.