

SHORT COMMUNICATION

Long-term Follow-up of Longitudinal Melanonychia in Children and Adolescents Using an Objective Discrimination Index

Hiroshi Koga^{1#}, Shunji Yoshikawa^{2#}, Tetsuhiro Shinohara², Frédérique-Anne Le Gal³, Begonia Cortés³, Toshiaki Saida¹ and Takayuki Sota²¹Department of Dermatology, Shinshu University School of Medicine, Asahi, Matsumoto, Nagano 390-8621, ²Department of Electrical Engineering and Bioscience, Waseda University, Shinjuku, Tokyo, Japan, and ³Service de Dermatologie, Hôpitaux Universitaires de Genève, Geneva, Switzerland. E-mail: koga@shinshu-u.ac.jp[#]These authors contributed equally to this work.

Accepted Jan 21, 2016; Epub ahead of print Jan 25, 2016

Nail apparatus melanoma is extremely rare in children, regardless of race (1–5). Almost all cases of longitudinal melanonychia (LM) seen in children are benign, with the majority being due to melanocytic naevi affecting the nail matrix or nail bed. However, LM lesions in children are often broad and irregular (1–5), mimicking the appearance of nail apparatus melanoma *in situ* in adults on both naked-eye and dermoscopic examination (6–8). The lack of criteria for differentiating between benign LM and nail apparatus melanoma *in situ* presents a serious diagnostic dilemma (5). Long-term follow-up of children with LM is necessary to accumulate data on how LM lesions change over time and to obtain better insight into this problem.

Our group has previously proposed an objective discrimination index (DI) for evaluating colour variegation in dermoscopic JPEG images of the nail plate (9). In Japanese adult patients, the index worked well for differentiation of nail apparatus melanoma *in situ* from benign LM, such as melanocytic naevi and reactive nail pigmentation. With a threshold value set at 0.0928, our DI was able to diagnose nail apparatus melanoma *in situ* with 100% sensitivity and 92% specificity (9). This index is also useful in monitoring changes in suspicious LM over time (unpublished data).

In this study we applied our previously proposed DI to dermoscopic images of LM lesions in 15 children and adolescents. In 12 of these cases, long-term changes in DI were also evaluated after a range of 27 to 103 months.

MATERIALS AND METHODS (see Appendix S1¹)

RESULTS

Table S1¹ shows the DI of the LM lesion in each of the 15 patients at the first visit to our clinic. In 9 of 15 patients, the DI exceeded the threshold value (0.0928) used to differentiate nail apparatus melanoma *in situ* from benign LM in adults (9).

Fig. 1 shows changes in DI over time in the 12 followed-up cases (cases 1–11 and 14), with the red

broken horizontal line indicating the threshold value mentioned above. For the 10 children younger than 14 years at the first visit (cases 1–9 and 14), the index tended to drop towards or below the threshold value as they grew older, although it increased transiently in a few cases. However, in the 2 adolescents (cases 10 and 11), the index remained above the threshold value over most or all of the observation period. Fig. S1¹ shows changes in LM lesions over time using dermoscopic images and DI values from cases 4, 6, 10 and 14. In cases 4 and 6, the LM lesion at first visit was broad and irregular, dermoscopically mimicking the appearance of nail apparatus melanoma *in situ* in adults.

DISCUSSION

Various criteria and algorithms for dermoscopically differentiating between nail apparatus melanoma and benign LM have been proposed based on differences in LM lesion coloration and morphology (6–8, 10, 11). We previously reviewed the key dermoscopic points of differences between early nail apparatus melanoma and benign LM, noting that evaluation of morphology and coloration is essentially subjective and sometimes very difficult (4). To overcome these problems, we

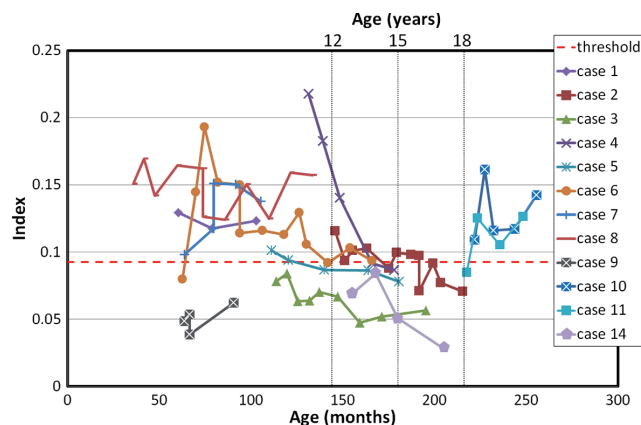


Fig. 1. Changes in the discrimination index of colour variegation in dermoscopic images of longitudinal melanonychia during the observation period. The horizontal red broken line indicates the threshold value of the discrimination index (0.0928) for adult Japanese.

¹<https://doi.org/10.2340/00015555-2349>

recommend periodic dermoscopic follow-up (4) and use of our recently proposed objective DI representing colour variegation in dermoscopic JPEG images of LM lesions (9).

In Japanese children, nail apparatus naevi often appear as variegated brown LM on dermoscopy, mimicking the dermoscopic features of nail apparatus melanoma in adults (4). Importantly, although such lesions initially show a rapid increase in width and colour variegation, the pigmentation stabilizes after a variable period and typically regresses partially or completely by adolescence (1, 4). This behaviour supports the adoption of a “wait and see” policy for irregular, broad LM lesions in children.

According to Iorizzo et al. (3), the “wait and see” approach is best when the clinical and dermoscopic features of the LM lesion indicate a low risk of melanoma; i.e. a narrow pigmented band, regular dermoscopic features, and no apparent changes over time. Conversely, Tosti et al. (5), suggested that the “wait and see” policy is inappropriate in children with particularly suspicious LM.

To our knowledge, only one case of LM in a 13-year-old Japanese child has ever been definitively diagnosed as a malignant melanoma (MM) (12), which had developed at the age of 6 years. Excisional biopsy was performed and the lesion was histopathologically diagnosed as most likely being a Spitz naevus. Two years later, however, the patient developed metastasis of MM.

The nail plates are not normally pigmented, irrespective of race, but inactive melanocytes have been detected in the epithelium of the nail matrix (13). LM is mainly due to melanin pigment produced by activated or proliferating melanocytes in the matrix. Melanoma cells are often characterized by a higher-than-normal ratio of pheomelanin to eumelanin (14, 15). Thus, in adults with nail apparatus melanoma *in situ*, the nail plate displays a reddish-brown colour and highly variegated LM. At least in Japanese patients, the DI is significantly higher in nail apparatus melanoma *in situ* than in benign LM, such as melanocytic naevi of the nail apparatus (9). Notably, however, the DI may be low in some advanced nail apparatus melanomas (unpublished data). This is because particular cell clones with high proliferative potential may dominate the lesion, resulting in relatively uniform LM.

In this study, the DI of LM lesions tended to decrease over time in children younger than 14 years at their first visit to our clinic. This observation is consistent with previous studies (1, 4), supporting the accuracy of the DI as a reflection of changes over time in LM lesions in children.

In cases 10 and 11 (both 18 years old at first visit), the DI reached levels high enough to suggest melanoma *in situ* in adults and maintained such levels until the end of the observation period. Careful follow-up should be conducted in such cases.

In case 14, involving a Caucasian child, the LM lesion was narrow, but the parallel lines were somewhat irre-

gular at the first and second visits (Fig. S1d¹). However, the colours of the LM lesion faded out gradually up to the fourth visit, supporting the diagnosis of a melanocytic naevus of the nail apparatus.

In conclusion, DI is useful for objectively evaluating changes in colour variegation over time in LM lesions. The “wait and see” policy seems appropriate for LM in children < 14 years. But, when LM appears in the late teens more intense follow-up observation is required. Clearly, the validity of this must be evaluated in studies with larger sample sizes.

REFERENCES

1. Kikuchi I, Inoue S, Sakaguchi E, Ono T. Regressing nevoid nail melanosis in childhood. *Dermatology* 1993; 186: 88–93.
2. Goettmann-Bonvallet S, André J, Belaïch S. Longitudinal melanonychia in children: a clinical and histopathologic study of 40 cases. *J Am Acad Dermatol* 1999; 41: 17–22.
3. Iorizzo, M, Tosti A, Di Chiacchio N, Hirata SH, Misciali C, Michalany N, et al. Nail melanoma in children: differential diagnosis and management. *Dermatol Surg* 2008; 34: 974–978.
4. Koga H, Saida T, Uhara H. Key point in dermoscopic differentiation between early nail apparatus melanoma and benign longitudinal melanonychia. *J Dermatol* 2011; 38: 45–52.
5. Tosti A, Piraccini BM, Cagalli A, Haneke E. In situ melanoma of the nail unit in children: Report of two cases in fair-skinned Caucasian children. *Pediatr Dermatol* 2012; 29: 79–83.
6. Ronger S, Touzet S, Ligeron C, Balme B, Viallard AM, Barrut D, et al. Dermoscopic examination of nail pigmentation. *Arch Dermatol* 2002; 138: 1327–1333.
7. Tosti A. Dermoscopy allows better management of nail pigmentation. *Arch Dermatol* 2002; 138: 1369–1370.
8. Braun RP, Baran R, Le Gal FA, Dalle S, Ronger S, Pandolfi R, et al. Diagnosis and management of nail pigmentations. *J Am Acad Dermatol* 2007; 56: 835–847.
9. Koga H, Yoshikawa S, Shinohara T, Sekiguchi A, Fujii J, Saida T, Sota T. An automated evaluation system of dermoscopic images of longitudinal melanonychia: proposition of a discrimination index for detecting early nail apparatus melanoma. *J Dermatol* 2014; 41: 867–871.
10. Johr RH, Izakovic J. Dermatoscopy/ELM for the evaluation of nail-apparatus pigmentation. *Dermatol Surg* 2001; 27: 315–322.
11. Kawabata Y, Ohara K, Hino H, Tamaki K. Two kinds of Hutchinson’s sign, benign and malignant. *J Am Acad Dermatol* 2001; 44: 305–307.
12. Takata M, Maruo K, Kageshita T, Ikeda S, Ono T, Shirasaki F, et al. Two cases of unusual acral melanocytic tumors: illustration of molecular cytogenetics as a diagnostic tool. *Hum Pathol* 2003; 34: 89–92.
13. Perrin C, Michiels JF, Pisani A, Ortonne JP. Anatomic distribution of melanocytes in normal nail unit: an immunohistochemical investigation. *Am J Dermatopathol* 1997; 19: 461–467.
14. Hu DN, Wakamatsu K, Ito S, McCormick SA. Comparison of eumelanin and pheomelanin content between cultured uveal melanoma cells and normal uveal melanocytes. *Melanoma Res* 2009; 19: 75–79.
15. Simon JD, Peles D, Wakamatsu K, Ito S. Current challenges in understanding melanogenesis: bringing chemistry, biological control, morphology, and function. *Pig Cell Res* 2009; 22: 563–579.