

SHORT COMMUNICATION

Erythrokeratoderma Variabilis Caused by p.Gly45Glu in Connexin 31: Importance of the First Extracellular Loop Glycine Residue for Gap Junction FunctionTakuya Takeichi^{1,2}, Kazumitsu Sugiura¹, Chao-Kai Hsu^{2,3}, Toshifumi Nomura⁴, Hiroyuki Takama¹, Michael A. Simpson⁵, Hiroshi Shimizu⁴, John A. McGrath² and Masashi Akiyama^{1*}¹Department of Dermatology, Nagoya University Graduate School of Medicine, 65 Tsurumai-cho, Showa-ku, Nagoya 466-8550, Japan, ²St John's Institute of Dermatology, ³Division of Genetics and Molecular Medicine, King's College London, Guy's Hospital, London, UK, ³Department of Dermatology, National Cheng Kung University Hospital, College of Medicine, National Cheng Kung University, Tainan, Taiwan, and ⁴Department of Dermatology, Hokkaido University Graduate School of Medicine, Sapporo, Japan. *E-mail: makiyama@med.nagoya-u.ac.jp
Accepted Dec 2, 2015; Epub ahead of print Dec 3, 2015

Most cases of erythrokeratoderma variabilis (EKV, OMIM#133200) are inherited in an autosomal dominant manner, although autosomal recessive cases can occur. EKV is caused by mutations in *GJB3* or *GJB4*, which encode connexin (Cx) 31 and Cx30.3, respectively. Clinically, there are 2 characteristic skin manifestations of EKV: localized, sharply circumscribed hyperkeratotic plaques; and migratory erythematous lesions (1, 2). Cxs are components of gap junctions, intercellular junctions that are expressed in several organs, including the skin and the cochlea. Individual Cxs are assembled in groups of 6 to form hemichannels in the plasma membrane, and then 2 hemichannels between adjacent cells combine to form a gap junction (2). To date, 21 Cx genes have been discovered that have essential roles in cell communication and free transfer of small molecules in many organs. In this report, we describe a recurrent mutation in *GJB3*, p.Gly45Glu, in a Japanese female with EKV. In addition, we review the literature and focus on genotype-phenotype correlations, notably for Cx mutations affecting the first glycine within the first extracellular domain of the protein.

CASE REPORTS

The proband is an 8-year-old Japanese girl who had presented with generalized erythema and ichthyosis since the age of 6 months. She was born to non-related, healthy parents. On

examination, she had transient, migratory, variably sized, irregularly shaped and sharply-margined erythema on her chest, back and extremities (Fig. 1A). Diffuse scaly hyperkeratosis with erythroderma was noted on her cheeks, trunk and extremities (Fig. 1B and C). In addition, she had mild palmoplantar keratoderma. Her hair and nails were normal. She did not have any neurological symptoms or hearing loss. Light microscopy of a lesional skin biopsy revealed hyperkeratosis, slight hypergranulosis, papillomatosis and mild acanthosis (Fig. S1A¹).

Ethical approval was obtained and all research was performed in accordance with the principles of the Declaration of Helsinki. Genomic DNA from the patient's peripheral blood leukocytes was used for whole-exome sequencing analysis, as described previously (3). Analysis of the data disclosed a previously reported heterozygous missense mutation in *GJB3*, c.134G>A (p.Gly45Glu; sequence according to GenBank accession no. NM_024009). The mutation was confirmed by Sanger sequencing (Fig. S1B¹) and was not identified in the DNA from >1,000 control individuals in our exome databank. In addition, the whole exome data did not show any other putative mutation in *GJB3*, *GJB4* or other Cx genes or indeed other genes previously implicated in the molecular pathology of ichthyosis.

DISCUSSION

The mutation identified here, p.Gly45Glu in *GJB3*, has been reported previously as a pathogenic variant

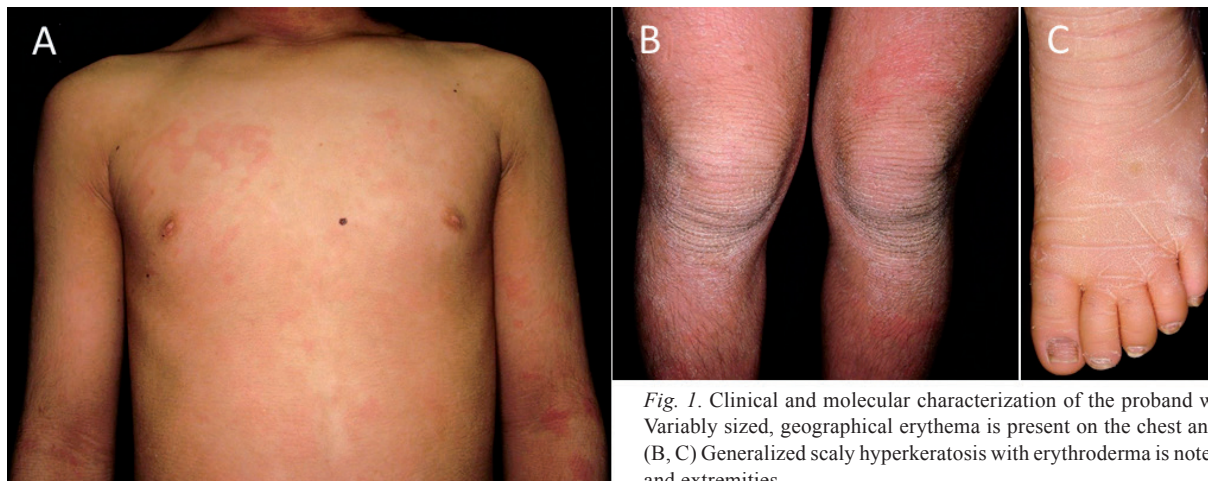
¹<https://doi.org/10.2340/00015555-2307>

Fig. 1. Clinical and molecular characterization of the proband with EKV. (A) Variably sized, geographical erythema is present on the chest and upper arms. (B, C) Generalized scaly hyperkeratosis with erythroderma is noted on the trunk and extremities.

in individuals with EKV from German and Chinese populations (4, 5). It is located in the first of 2 extracellular domains of the Cx31; sites that are necessary for intercellular contact and communication (Fig. S2A¹).

In addition to EKV, mutations in Cx family genes are involved in a variety of hereditary human skin disorders. Briefly, mutations in Cx26 (encoded by *GJB2*) are linked to diseases including Vohwinkel syndrome, keratitis-ichthyosis deafness (KID), and hystrix-like ichthyosis deafness syndromes, palmoplantar keratoderma with deafness, deafness with Clouston-like phenotype, and Bart–Pumphrey syndrome. Mutations in Cx30 (encoded by *GJB6*) underlie Clouston syndrome, whereas in Cx43 (encoded by *GJB1*) mutations lead to oculodentodigital dysplasia (6).

We previously documented a substitution of the corresponding glycine residue in Cx26 (encoded by *GJB2*) in a patient with KID syndrome (7). KID syndrome is a rare congenital ectodermal disorder characterized by vascularizing keratitis, ichthyosis, and sensorineural hearing loss. In that study, we showed that gap junctions containing p.Gly45Glu-mutant-Cx26 displayed aberrant gating activity (7). Indeed, the same heterozygous *de novo* p.Gly45Glu mutation in *GJB2* has been previously reported to underlie a severe form of KID syndrome in an Austrian patient (8). Both these cases died from KID syndrome. Moreover, Mese et al. (9) have created an animal model for KID syndrome by generating an inducible transgenic mouse expressing Cx26-p.Gly45Glu in keratinocytes. Cx26-p.Gly45Glu mice displayed reduced viability, hyperkeratosis, scaling, skin folds, and hair loss. Recently, Levinsohn et al. (10) identified the same mutation, albeit as a somatic finding, in tissue samples isolated from a skin lesion of porokeratotic eccrine ostial and dermal duct naevus (PEODDN). PEODDN is a mosaic disorder presenting clinically as linear epidermal naevi with spiny hyperkeratosis, and with skin histology findings of hyperkeratosis, acanthosis, and porokeratotic plugs emerging from eccrine ducts. Of note, Easton et al. (11) provided the first evidence that type I segmental mosaicism resulting from a single *GJB2* somatic mutation can cause PEODDN. Moreover, PEODDN lesions have been identified in Blaschko-linear patterns in otherwise healthy individuals, as well as in patients with KID syndrome.

In terms of gap junction function, Mese et al. (9) demonstrated that a Cx26-p.Gly45Glu mutant forms leaky hemichannels that are aberrantly activated at low extracellular Ca²⁺ levels. In addition, other studies have shown that the Cx30-p.Gly45Glu mutation (in HEK293 cells) results in leaky hemichannels and death of the cells in the same manner as for the Cx26-p.Gly45Glu cells (12). Furthermore, a mutation in Gly46 of Cx50 (which corresponds to Gly45 in Cx26 and Cx30), namely Cx50-p.Gly46Val, also induces leaky hemichannels, resulting in cell death (in *Xenopus* oocytes) (13).

Although there is no detailed analysis of the 3-dimensional (3D) structure of Cx31, a recent high-resolution 3D structural study of Cx26 gap junction channels was achieved by X-ray crystallography at 3.5 Å resolution (14). In this work, the pore-lining residues at the first transmembrane/first extracellular loop boundary in Cx26 were shown to be Lys 41, Glu 42 and Gly 45. The pore is narrowed at the funnel, which is formed by the 6 amino-terminal helices lining the wall of the channel, which thus determines the molecular size restriction at the channel entrance (14). Their findings therefore also support our hypothesis about the functional importance of p.Gly45 in Cx26.

Mechanistically, the missense mutations affecting the first glycine residue in the first extracellular loop disrupts a highly conserved amino acid residue that shows homology, not only within the family of *GJB* genes, but also to some *GJA* members. Germane to its importance, the corresponding glycine residue is found in 8 of the other human Cxs, including *GJA8* (Fig. S2B¹). *GJA8* is one of the most common genes implicated in congenital cataract with or without other ocular abnormalities (15), and 2 germline missense mutations, p.Gly46Arg and p.Gly46Val, in *GJA8* have been reported as pathogenic variants in inherited congenital cataract pedigrees (13, 15). Functionally, hydropathicity algorithms predict that this amino acid localizes at the beginning of the first extracellular loop of Cx50. Similar to p.Gly45Glu-mutant Cx26, the disease-associated mutant Cx50 p.Gly46Val is also able to induce apoptosis when transfected into HeLa cells (13). In Table S1¹, we summarize the reported missense mutations affecting this particular glycine residue across the Cx gene family and the associated clinical implications.

ACKNOWLEDGEMENTS

The authors would like to thank Ms Haruka Ozeki and Ms Yuka Terashita for their technical help in analysing mutations of *GJB3*. This study was supported in part by a Grant-in-Aid for Scientific Research (B) to MA (15H04887), a Grant-in-Aid for Challenging Exploratory Research to MA (15K15415), a Grant-in-Aid for Scientific Research (B) to KS (15H04886) and a Grant-in-Aid for Challenging Exploratory Research to KS (15K15414) from the Ministry of Education, Culture, Sports, Science and Technology of Japan. The study is also supported by the UK National Institute for Health Research (NIHR) Biomedical Research Centre based at Guy's and St Thomas' NHS Foundation Trust and King's College London.

The authors declare no conflicts of interest.

REFERENCES

1. Richard G, Smith LE, Bailey RA, Itin P, Hohl D, Epstein EH, Jr., et al. Mutations in the human connexin gene *GJB3* cause erythrokeratoderma variabilis. *Nat Genet* 1998; 20: 366–369.
2. Macari F, Landau M, Cousin P, Mevorah B, Brenner S, Panizzon R, et al. Mutation in the gene for connexin 30.3

- in a family with erythrokeratoderma variabilis. *Am J Hum Genet* 2000; 67: 1296–1301.
3. Takeichi T, Liu L, Fong K, Ozoemena L, McMillan JR, Salam A, et al. Whole-exome sequencing improves mutation detection in a diagnostic epidermolysis bullosa laboratory. *Br J Dermatol* 2015; 172: 94–100.
 4. Renner R, Paasch U, Simon JC, Froster UG, Heinritz W. A new mutation in the GJB3 gene in a patient with erythrokeratoderma variabilis. *J Eur Acad Dermatol Venereol* 2008; 22: 750–751.
 5. Wang W, Liu LH, Chen G, Gao M, Zhu J, Zhou FS, et al. A missense mutation in the GJB3 gene responsible for erythrokeratoderma variabilis in a Chinese family. *Clin Exp Dermatol* 2012; 37: 919–921.
 6. Avshalumova L, Fabrikant J, Koriakos A. Overview of skin diseases linked to connexin gene mutations. *Int J Dermatol* 2014; 53: 192–205.
 7. Ogawa Y, Takeichi T, Kono M, Hamajima N, Yamamoto T, Sugiura K, et al. Revertant mutation releases confined lethal mutation, opening Pandora's box: a novel genetic pathogenesis. *PLoS Genet* 2014; 10: e1004276.
 8. Janecke AR, Hennies HC, Gunther B, Gansl G, Smolle J, Messmer EM, et al. GJB2 mutations in keratitis-ichthyosis-deafness syndrome including its fatal form. *Am J Med Genet A* 2005; 133A: 128–131.
 9. Mese G, Sellitto C, Li L, Wang HZ, Valiunas V, Richard G, et al. The Cx26-G45E mutation displays increased hemichannel activity in a mouse model of the lethal form of keratitis-ichthyosis-deafness syndrome. *Mol Biol Cell* 2011; 22: 4776–4786.
 10. Levinsohn JL, McNiff JM, Antaya RJ, Choate KA. A Somatic p.G45E GJB2 Mutation causing porokeratotic eccrine ostial and dermal duct nevus. *JAMA Dermatol* 2015; 151: 638–641.
 11. Easton JA, Donnelly S, Kamps MA, Steijlen PM, Martin PE, Tadini G, et al. Porokeratotic eccrine nevus may be caused by somatic connexin26 mutations. *J Invest Dermatol* 2012; 132: 2184–2191.
 12. Zhang Y, Hao H. Conserved glycine at position 45 of major cochlear connexins constitutes a vital component of the Ca(2)(+) sensor for gating of gap junction hemichannels. *Biochem Biophys Res Commun* 2013; 436: 424–429.
 13. Minogue PJ, Tong JJ, Arora A, Russell-Eggitt I, Hunt DM, Moore AT, et al. A mutant connexin50 with enhanced hemichannel function leads to cell death. *Invest Ophthalmol Vis Sci* 2009; 50: 5837–5845.
 14. Maeda S, Nakagawa S, Suga M, Yamashita E, Oshima A, Fujiyoshi Y, et al. Structure of the connexin 26 gap junction channel at 3.5 Å resolution. *Nature* 2009; 458: 597–602.
 15. Sun W, Xiao X, Li S, Guo X, Zhang Q. Mutational screening of six genes in Chinese patients with congenital cataract and microcornea. *Mol Vis* 2011; 17: 1508–1513.