

## QUIZ SECTION

### Giant Ulcer on Abdominal Wall: A Quiz

Hao Guo, Jiu-Hong Li\*, Xiao-Yi Yang, Xiao-Lu Wang, Jie Cao, Song Zheng and Hong-Duo Chen

Department of Dermatology, No. 1 Hospital of China Medical University, 155N Nanjing Street, Shenyang 110001, China. E-mail: Pfk12011@126.com

A 68-year-old Chinese male presented to our department with a large (20 × 40 cm), rapidly expanding, painful, necrotic skin ulcer that had developed on his lower abdomen 2 months previously (Fig. 1). The ulcer had started as pain and redness 3 days after a retro-pubic prostatectomy for benign prostatic hyperplasia at a local hospital. The patient was moderately feverish (38.5°C) and culture of the discharge revealed *Staphylococcus aureus*. However, there was no improvement in the patient's condition after 2 weeks of treatment with Cefazolin 0.5 g twice daily.

Laboratory tests revealed a white cell count of  $11.23 \times 10^9/l$  (normal range  $3.5 \times 10^9$ – $9.5 \times 10^9/l$ ), haemoglobin 80 g/l (normal range 115–150 g/l), C-reactive protein 48 mg/l (normal range 0–10 mg/l) and erythrocyte sedimentation rate 45 mm/h (normal range 0–20 mm/h). All other tests were normal, including antinuclear antibodies, anti-neutrophil cytoplasmic antibodies, HIV, and Venereal Disease Research Laboratory test (VDRL) for syphilis.

What is your diagnosis? See next page for answer.

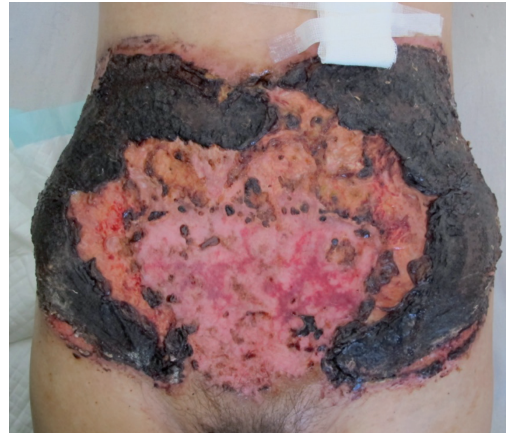

Fig. 1. Skin ulcer on the abdominal wall.

## ANSWERS TO QUIZ

**Giant Ulcer on Abdominal Wall: A Comment**

Acta Derm Venereol 2016; 96: 427–431.

**Diagnosis: Post-surgical pyoderma gangrenosum (PSPG)**

A skin biopsy specimen from the ulcer border revealed diffused infiltration of neutrophils, and fibrinoid necrosis of small vessels in the dermis and subcutaneous tissue peripheral to the base of the ulcer (Fig. 2a). Tissue culture for bacteria and fungus gave negative results.

The biopsy and tissue culture findings were consistent with pyoderma gangrenosum (PG).

Post-surgical PG (PSPG) is a specific condition with a series of characteristics in addition to the clinical features of PG (1). PSPG usually occurs in the first week following surgery (1); it may be acute and fulminant, and usually emerges with a painful and rapidly expanding ulcer. Fever, malaise, leukocytosis, and an elevated C-reactive protein may also be detected in PSPG (2–4). The lesions begin with a simple erythema around the sutures.

Differential diagnosis includes progressive synergistic gangrene, ecthyma gangrenosum, clostridial infection, atypical mycobacterial infection, systemic vasculitis, Sweet's syndrome, granulomatous disorders and stasis ulceration (5). However, there are no specific clinical signatures that distinguish PSPG from other post-surgical infections (5).

The patient was treated with methylprednisolone (40 mg daily). After 2 weeks, the size of the ulcer had decreased and the pain was relieved. The ulcer was completely healed after 2 months of treatment, and cribriform scars were visible over the ulcer site (Fig. 2b). No recurrent disease was observed at 6-month follow-up.

There is currently no standard treatment for PSPG, but systemic prednisone is the most commonly used medication (6). In cases that do not respond to glucocorticoids alone, other agents may be used, either alone or combined with glucocorticoids. These agents include: cyclosporine, methotrexate, azathioprine, cyclophosphamide, infliximab, etanercept, adalimumab, alefacept, mycophenolate mo-

fetil, dapsone, tacrolimus, chlorambucil, intravenous immunoglobulin, colchicine and interferon alpha (6, 7). Direct topical application of corticosteroids or immunomodulators to the ulcer maybe helpful (6). Surgical debridement or necrosectomy is contraindicated in PSPG (6, 7). Management of any active associated disease, such as ulcerative colitis, should also be considered.

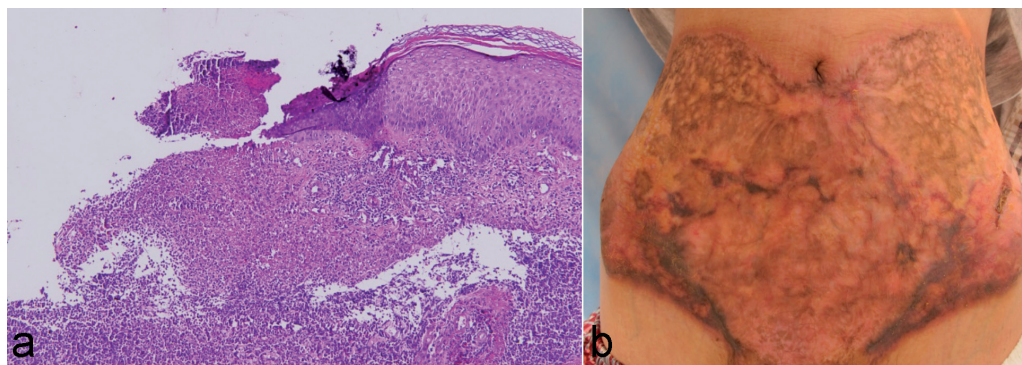
## ACKNOWLEDGEMENT

The authors would like to thank Dr He-Xiao Wang for language editing.

*The authors declare no conflicts of interest.*

## REFERENCES

1. Ouazzani A, Berthe JV, de Fontaine S. Post-surgical pyoderma gangrenosum: a clinical entity. *Acta Chir Belg* 2007; 107: 424–428.
2. Sebastian VA, Carroll BT, Jessen ME. Pyoderma gangrenosum associated with chronic idiopathic myelofibrosis after artery bypass graft surgery. *Interact Cardiovasc Thorac Surg* 2010; 10: 135–137.
3. Noblett SE, Woodcock S. Port-site pyoderma gangrenosum – a rare complication of surgical trauma. *Ann R Coll Surg Engl* 2009; 91: 665–666.
4. Pekmezci S, Saribeyoglu K, Mat C. Pyoderma gangrenosum: an idiopathic case and recurrence after surgery. *Surgery* 1999; 126: 85–87.
5. Su WPD, Davis MDP, Weenig RH, Powell FC, Perry HO. Pyoderma gangrenosum: clinicopathologic correlation and proposed diagnostic criteria. *Int J Dermatol* 2004; 43: 790–800.
6. Dabade TS, Davis MD. Diagnosis and treatment of the neutrophilic dermatoses (pyoderma gangrenosum, Sweet's syndrome). *Dermatol Ther* 2011; 24: 273–284.
7. Patel F, Fitzmaurice S, Duong C, He Y, Fergus J, Raychaudhuri SP, et al. Effective strategies for the management of pyoderma gangrenosum: a comprehensive review. *Acta Derm Venereol* 2015; 95: 525–531.



*Fig. 2. (a) Ulceration with diffuse infiltration of neutrophils (haematoxylin-eosin staining, original magnification  $\times 200$ ). (b) Completely healed ulcer 2 months after treatment.*