

## CLINICAL REPORT

# Coxsackievirus A6 Polymorphic Exanthem in Israeli Children

Yael RENERT-YUVAL<sup>1</sup>, Eytan MARVA<sup>2</sup>, Merav WEIL<sup>3</sup>, Lester M. SHULMAN<sup>3,4</sup>, Nilsu GENCYLMAZ<sup>1</sup>, Sivan SHEFFER<sup>1</sup>, Dana G. WOLF<sup>2</sup> and Vered MOLHO-PESSACH<sup>1</sup>

<sup>1</sup>Department of Dermatology, <sup>2</sup>Clinical Virology Unit, Department of Clinical Microbiology and Infectious Diseases, Hadassah-Hebrew University Medical Center, Jerusalem, <sup>3</sup>Central Virology Laboratory, Israel Ministry of Health, Sheba Medical Center, Tel Hashomer, and <sup>4</sup>Department of Epidemiology, and Preventive Medicine, School of Public Health, Sackler Faculty of Medicine, Tel Aviv University, Tel Aviv, Israel

**Hand foot and mouth disease (HFMD) is an acute childhood viral exanthem usually associated with coxsackievirus A16 or enterovirus 71. Atypical HFMD associated with coxsackievirus A6 was reported recently. The aim of the current study was to describe coxsackievirus A6-associated atypical HFMD in a series of 8 toddlers who were referred with idiopathic extensive eruptions. Demographic and clinical characteristics, Reverse transcriptase-real-time PCR (RT-PCR) results for enterovirus and phylogenetic analysis for the coxsackievirus A6 strains were recorded. Morphologically polymorphous (vesicular, erosive, papular, desquamative or purpuric) and extensive eruptions were found. One patient had delayed nail shedding. Enterovirus was positive in all patients. Genotype analysis confirmed coxsackievirus A6 in 6 patients and 5 sequences underwent phylogenetic analysis. This is the first such report in Israeli children. In conclusion, coxsackievirus A6 atypical HFMD should be regarded as a novel childhood viral exanthem. We suggest the term “coxsackievirus A6 polymorphic exanthem” due to the extensive and variable nature of this eruption. Key words: hand foot and mouth; viral exanthem; coxsackievirus A6.**

Accepted Oct 13, 2015; Epub ahead of print Oct 14, 2015

Acta Derm Venereol 2016; 96: 546–549.

Vered Molho-Pessach, Department of Dermatology, Hadassah-Hebrew University Medical Center, Jerusalem 91120, Israel. E-mail: rverem@hadassah.org.il

Enterovirus (EV)-associated hand foot and mouth disease (HFMD) is an acute viral illness, ordinarily occurring from spring to autumn, and affecting children younger than 5 years of age. It is spread by contact with saliva, faeces, respiratory secretions and vesicular fluid (1). The disease is caused by certain EV strains, with coxsackievirus (CV) A16 and EV-71 most commonly implicated. Typical clinical manifestations include fever and a mucocutaneous rash involving the oral cavity, hands, feet and, occasionally, the buttocks. Oral mucosal lesions consist of vesicles surrounded by red areola, which often ulcerate. Papulovesicles are noted on the hands and feet and tend to run parallel to the skin lines (2). The disease

is usually self-limiting and resolves within one week, although severe systemic manifestations, including myocarditis, meningoencephalitis, aseptic meningitis and acute flaccid paralysis, have been reported in EV-71-related HFMD (3, 4). Delayed cutaneous findings can occur 3–8 weeks after HFMD and include acral desquamation and nail matrix arrest (presenting as Beau's lines or nail shedding) (5).

Since 2008, CV-A6 has emerged as a cause of HFMD with an intense and widespread rash with atypical cutaneous presentations (1). CV-A6 HFMD can easily be misdiagnosed as eczema herpeticum, bullous impetigo, vasculitis and primary immunobullous diseases of childhood (6). CV-A6 has also been shown to affect adults (7). Recently, 5 adults with an acute acral vasculitis-like rash due to CV-A6 were reported from Israel (8); however, thus far, CV-A6 has not been reported as a cause of atypical HFMD in Israeli children.

We report here 8 Israeli toddlers with atypical HFMD. In 6 patients, sufficient quantities of RNA were available for genotyping and all were identified as CV-A6.

## METHODS

Patients were referred to the Hadassah Hebrew University Medical Center ER for EV detection. A swab was taken from the mucocutaneous lesions, and RNA was extracted by use of the automated extractor NucliSENS® easyMAG® (Biomérieux). The purified RNA was subjected to Reverse transcriptase-real-time PCR (RT-PCR), using primers and probes derived from the conserved EV 5' non-coding region, as described previously (9). A partial sequence of viral capsid protein 1 (VP1) was obtained after nested RT-PCR, as described previously (10), using internal primers AN88 and AN89 for sequencing with an ABI PRISM BigDye Terminator Cycle Sequencing kit (Applied Biosystems, Foster City, CA, USA). The sequences were determined on an ABI 3500 Genetic Analyzer (Applied Biosystems). Six sequences were identified as CVA-6 by the Enterovirus Genotyping Tool (11). The sequencer v5.0 program (Gencodes, Anne Arbor MI, USA) was used to align the sequence with equivalent regions of CVA6 prototype genotypes and current isolates downloaded from the DDBJ/EMBL/GenBank database. After truncating 5 of the new Israeli sequences to the longest common sequence among isolates (214 nt) an unrooted neighbor-joining tree with kimura 2-parameter correction was constructed using Clustal X v1.83 after bootstrapping data 1,000 times. The tree was visualized using nj polot. The Israeli sequences reported here were submitted to GenBank and were assigned accession numbers KR011341 to KR011345.

## RESULTS

Eight patients, 6 males and 2 females, were diagnosed between March and October 2014 (patients 1–5 were referred during March and April, patients 6–8 during September and October) with an atypical presentation of HFMD. Patients' demographics and clinical characteristics are described in Table S1<sup>1</sup>. Patients' ages ranged from 6 to 24 months. Patients were unrelated, other than a pair of twins (patients 2 and 3). Past medical history included atopic dermatitis (AD) in 2 patients (patients 1 and 2), food allergies (patient 1) and preterm birth and mild motor developmental delay (patients 2 and 3). Seven patients presented with fever of up to 39.4°C, other symptoms included rhinorrhoea, cervical and inguinal lymphadenopathy, watery diarrhoea, decreased appetite and cough. However, all patients were in good general condition.

The eruption was usually widespread (Figs 1 and 2) and included the face in all patients, with a periorificial, mainly perioral distribution (Fig. 3) in most cases (patients 1, 4, 5–8). Only 3 patients (patients 4, 6 and 8) had intraoral involvement. All patients demonstrated involvement of the limbs, and half of the patients had involvement of the palms and soles (patients 1, 4, 6 and 8). The trunk was involved in 5 patients (patients 2, 3, 5–7) as well as the buttock and genitalia (patients 2–4, 6 and 8). The AD patients (patient 1 and 2) did not exhibit specific localization of the eruption to sites of eczema. The eruption manifested with polymorphic cutaneous features, but was usually monomorphic in each patient (Figs 1 and 2). The most common morphological pattern was erythematous erosive or crusted papules (Fig. 1B, C). Intact vesicles were noted in patient 4. Patients 2 and 3 presented with diffuse erythematous and crusted papules and plaques with marked desquamation (Fig. 2). Parents reported a preceding vesicubullous phase. Patient 6 was also noted to have desquamation. Patients

1 and 6 had purpuric or dusky papules and plaques over the limbs (Fig. 1D, E).

Laboratory evaluation showed mild leukocytosis in 2 patients and relative lymphocytosis of approximately 60% in 3 patients. C-reactive protein was mildly elevated in 3 patients. Two patients (patients 2 and 3) had positive skin cultures for methicillin-sensitive *Staphylococcus aureus*. RT-PCR performed on swabs obtained from mucocutaneous lesions was positive for EV in all 8 children. Seven samples (except patient 2) were subjected to genotypic analysis, 6 samples (patients 1, 3, 4, 5, 7 and 8) were positive for CV-A6. One sample did not yield results due to technical problems (patient 6). Sequences from 5 patients (patients 3, 4, 5, 7 and 8) were used for phylogenetic analysis (Fig. S1<sup>1</sup>). Sequences from isolates from patients 3, 4, 5 and 7, and 2 Israeli adults, KF991009 and KF991012 from 2012 and 2013, respectively, were closely related, but different from the isolate from patient 8. All isolates from toddlers were distinct from 3 other CV-A6s isolated from Israeli adults in 2012. Contemporary isolates that were most closely related to patients 3, 4, 5 and 7 were from the UK and Japan from 2013, whereas patient 8's isolate resembled sequences isolated in Malaysia in 2013 and China in 2012.

Patients 1–3, 5 and 6 were hospitalized and treated with topical corticosteroids and oral antibiotics, as well as intravenous acyclovir, due to an initial differential diagnosis of eczema herpeticum. Treatment with acyclovir was discontinued once herpes simplex virus PCR result returned negative, with positive EV RT-PCR. During admission, all patients were stable and showed gradual resolution of their rash. Patients 4, 7 and 8 were not admitted, due to their good general condition and the clinical diagnosis of atypical HFMD upon presentation. They were treated with topical corticosteroids with disappearance of the rash within several days. One month after admission, patient 4 was the only patient to develop nail shedding of several fingernails. Patient 5 developed widespread hyperpigmented macules, which resolved slowly and were consistent clinically with post-inflammatory hyperpigmentation.

<sup>1</sup><https://doi.org/10.2340/00015555-2261>

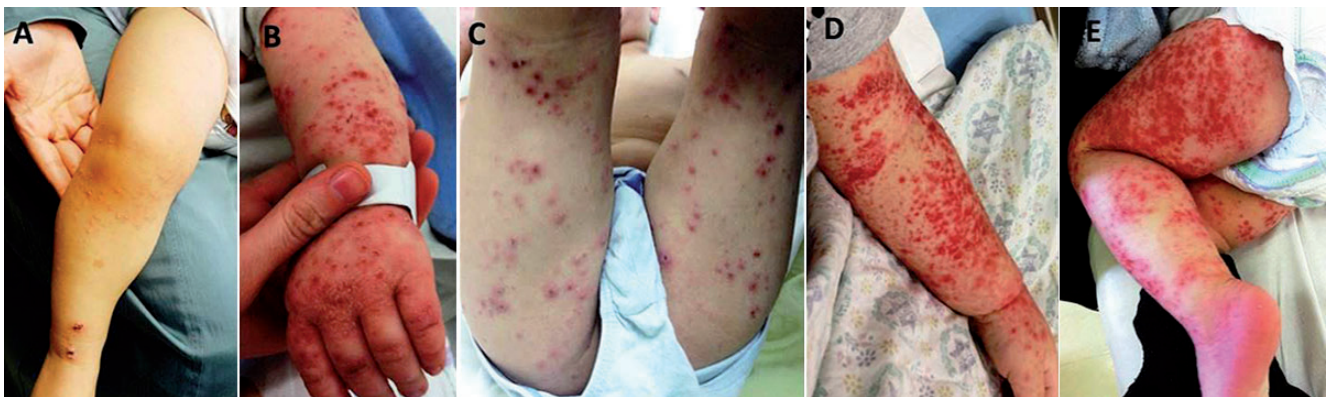


Fig. 1. (A) Papular eruption over the lower limbs in patient 7. (B) Erosive papular eruption in patient 4. (C) Erosive papules in patient 8. (D, E) Purpuric/dusky papules and plaques in patients 6 and 4.

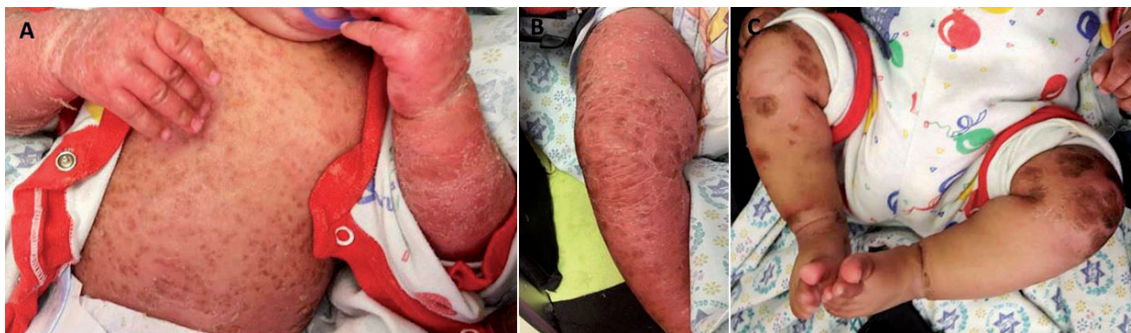

Fig. 2. (A, B) Widespread erythematous and crusted papules and plaques with marked desquamation in patient 2. (C) Crusted plaques with desquamation in patient 3.

## DISCUSSION

In an outbreak of HFMD in Finland in 2008, CV-A6, which had been previously associated with herpangina and only sporadically related to HFMD, was first found to be an eminent cause of HFMD (12, 13). Since then, reports of outbreaks from North America, Europe, Asia and New Zealand have revealed that CV-A6 HFMD is becoming more prevalent (1, 6, 7, 14–17). In 2012, the US Centers for Disease Control and Prevention reported a growing number of “severe and extensive” cases of HFMD associated with CV-A6. The appearance of CV-A6 as a novel cause of HFMD and its’ unique presentation have both been attributed to mutations in various regions of the viral genome (18).

Several different morphological patterns of the CV-A6 atypical HFMD were described (6): (i) a widespread vesiculobullous and erosive eruption – seen most frequently (19); (ii) an eczema herpeticum-like eruption (“eczema coxsackicum”), described as grouped vesicles or erosions, mainly affecting areas involved by eczema in children with AD (7, 20); (iii) a Gianotti-Crosti like eruption – a papulovesicular eruption with prominent involvement of the cheeks, extensor surfaces of the extremities, and buttocks, sparing the torso; (iv) petechial or purpuric eruption – often seen in children older than 5 years of age, most frequently on acral sites; and (v) a bullous palmoplantar eruption (21).

Delayed nail changes were seen in up to 37% of patients (6, 22).

Atypical HFMD had not been previously reported in Israeli children, although CV-A6 was recently shown to cause HFMD in Israeli adults (8). We report here 8 toddlers, seen between March and October 2014 in Jerusalem, with acute extensive polymorphic (papular, vesicular, erosive, purpuric and desquamative) rash, yet monomorphic in each patient. RT-PCR confirmed the diagnosis of EV infection and genotyping was positive for CV-A6 in 6 patients. The partial VP1 sequences of 4 of the CV-A6 strains were similar to those observed for 2 Israeli adults and distinct from the sequence of a fifth isolate. The Israeli strains isolated from the children mapped into branches that included isolates from the UK (2013), Japan (2013), China (2012) and Malaysia (2013); although no evidence has directly linked any of these or previous Israeli cases to importation (8).

The eruption in the toddlers was always extensive and tended to involve facial periorificial pattern, most often perioral. Although 2 patients had a history of AD, we did not observe specific distribution of the eruption to eczema-affected areas. Only 3 toddlers had involvement of the oral mucosa. In accordance with our finding, intraoral erosions are less commonly reported in atypical HFMD, as opposed to classic HFMD where oral lesions are present in up to 90% of cases (2, 6). The majority of patients had complete resolution of their symptoms within 7–10 days, with post-inflammatory hyperpigmentation and nail shedding noted during follow-up in one patient each. Secondary staphylococcal cutaneous infection was the only complication observed.

Despite increasing reports worldwide of CV-A6 atypical HFMD, clinicians are still unaware of this novel, yet common, childhood viral exanthem. All the patients reported herein were referred to the ER with various misdiagnoses, leading to futile admission, investigations, and occasional treatments. The phenotypic heterogeneity and the extensive distribution of the eruptions in our patients as well as in previous reports, argue that the term HFMD may be a misnomer for this viral exanthem. We sug-

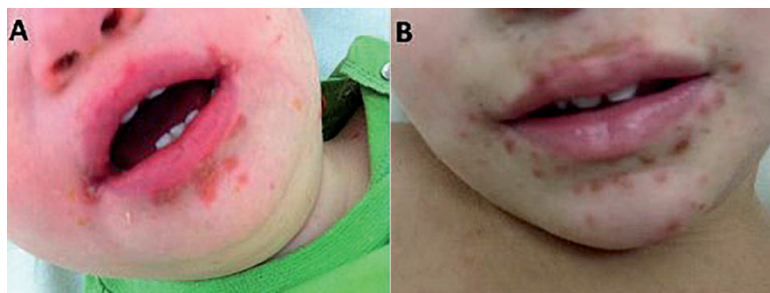

Fig. 3. (A) Perioral vesicles in patient 4. (B) Erosive erythematous papules in patient 8.

gest a more accurate term: “CV-A6 polymorphic exanthem”. Recognition of the clinical and morphological features can simplify differential diagnosis and prevent unnecessary interventions. Our findings underscore the importance of awareness of this emerging clinical-dermatological entity; hence, the presence of an acute widespread erosive papular, vesiculobullous, or even purpuric, eruption with perioral accentuation in a well-looking infant or toddler should raise suspicion of CV-A6 infection and allow prompt virological diagnosis.

*The authors declare no conflict of interest.*

## REFERENCES

- Centers for Disease Control and Prevention. Notes from the field: severe hand, foot, and mouth disease associated with coxsackievirus A6 – Alabama, Connecticut, California, and Nevada, November 2011–February 2012. *MMWR Morb Mortal Wkly Rep* 2012; 61: 213–214.
- James WD, Berger T, Elston D. *Viral Diseases*. In: James WD, Berger T, Elston D, editors. *Andrew’s diseases of the skin: clinical dermatology*, 11th edn. Philadelphia: Saunders Elsevier, 2011: p. 390.
- Ho M, Chen ER, Hsu KH, Twu SJ, Chen KT, Tsai SF, et al. An epidemic of enterovirus 71 infection in Taiwan. Taiwan Enterovirus Epidemic Working Group. *N Engl J Med* 1999; 341: 929–935.
- Wu Y, Yeo A, Phoon MC, Tan EL, Poh CL, Quak SH, et al. The largest outbreak of hand, foot and mouth disease in Singapore in 2008: the role of enterovirus 71 and coxsackievirus A strains. *Int J Infect Dis* 2010; 14: 1076–1081.
- Clementz GC, Mancini AJ. Nail matrix arrest following hand-foot-mouth disease: a report of five children. *Pediatr Dermatol* 2000; 17: 7–11.
- Mathes EF, Oza V, Frieden IJ, Cordoro KM, Yagi S, Howard R, et al. “Eczema acosackium” and unusual cutaneous findings in an enterovirus outbreak. *Pediatrics* 2013; 132: e149–e157.
- Lott JP, Liu K, Landry ML, Nix WA, Oberste MS, Bologna J, et al. Atypical hand-foot-and-mouth disease associated with coxsackievirus A6 infection. *J Am Acad Dermatol* 2013; 69: 736–741.
- Ben-Chetrit E, Wiener-Well Y, Shulman LM, Cohen MJ, Elinav H, Sofer D, et al. Coxsackievirus A6-related hand foot and mouth disease: skin manifestations in a cluster of adult patients. *J Clin Virol* 2014; 59: 201–203.
- Verstrepen WA, Bruynseels P, Mertens AH. Evaluation of a rapid real-time RTPCR assay for detection of enterovirus RNA in cerebrospinal fluid specimens. *J Clin Virol* 2002; 25: S39–S343.
- Nix WA, Oberste MS, Pallansch MA. Sensitive, seminested PCR amplification of VP1 sequences for direct identification of all enterovirus serotypes from original clinical specimens. *J Clin Microbiol* 2006; 44: 2698–2704.
- Kroneman A, Vennema H, Deforche K, Avoort H, Peñaranda S, Oberste MS, et al. An automated genotyping tool for enteroviruses and noroviruses. *J Clin Virol* 2001; 51: 121–125.
- Osterback R, Vuorinen T, Linna M, Susi P, Hyypiä T, Waris M. Coxsackievirus A6 and hand, foot, and mouth disease, Finland. *Emerg Infect Dis* 2009; 15: 1485–1488.
- Blomqvist S, Klemola P, Kaijalainen S, Paananen A, Simonen ML, Vuorinen T, et al. Co-circulation of coxsackieviruses A6 and A10 in hand, foot and mouth disease outbreak in Finland. *J Clin Virol* 2010; 48: 49–51.
- Mirand A, Henquell C, Archimbaud C, Ughetto S, Antona D, Bailly JL, et al. Outbreak of hand, foot and mouth disease/herpangina associated with coxsackievirus A6 and A10 infections in 2010, France: a large citywide, prospective observational study. *Clin Microbiol Infect* 2012; 18: 110–118.
- Fujimoto T, Iizuka S, Enomoto M, Abe K, Yamashita K, Hanaoka N, et al. Hand, foot, and mouth disease caused by coxsackievirus A6, Japan, 2011. *Emerg Infect Dis* 2012; 18: 337–339.
- Lu QB, Zhang XA, Wo Y, Xu HM, Li XJ, Wang XJ, et al. Circulation of Coxsackievirus A10 and A6 in hand-footmouth disease in China, 2009–2011. *PLoS One* 2012; 7: e52073.
- Hayman R, Shepherd M, Tarring C, Best E. Outbreak of variant hand-foot-and-mouth disease caused by coxsackievirus A6 in Auckland, New Zealand. *J Paediatr Child Health* 2014; 50: 751–755.
- Chen YJ, Chang SC, Tsao KC, Shih SR, Yang SL, Lin TY, et al. Comparative genomic analysis of coxsackievirus A6 strains of different clinical disease entities. *PLoS One* 2012; 7: e52432.
- Feder HM Jr, Bennett N, Modlin JF. Atypical hand, foot, and mouth disease: a vesiculobullous eruption caused by Coxsackie virus A6. *Lancet Infect Dis* 2014; 14: 83–86.
- Hubiche T, Schuffenecker I, Boralevi F, Léauté-Labrèze C, Bornebusch L, Chiaverini C, et al. Dermatological spectrum of hand, foot and mouth disease from classical to generalized exanthema. *Pediatr Infect Dis J* 2014; 33: e92–e98.
- Huang WC, Huang LM, Lu CY, Cheng AL, Chang LY. Atypical hand-foot-mouth disease in children: a hospital-based prospective cohort study. *Virol J* 2013; 10: 209.
- Wei SH, Huang YP, Liu MC, Tsou TP, Lin HC, Lin TL, et al. An outbreak of coxsackievirus A6 hand, foot, and mouth disease associated with onychomadesis in Taiwan, 2010. *BMC Infect Dis* 2011; 11: 346.