

SHORT COMMUNICATION

Characterization of a Novel Mutation in the *NCSTN* Gene in a Large Chinese Family with Acne InversaShide Zhang^{1#}, Jin Meng^{2#}, Miao Jiang³ and Jingjun Zhao^{3*}Departments of Dermatology, ¹Affiliated Fuding Hospital, Fujian University of Traditional Chinese Medicine, Fujian, ²Jining City First People Hospital, Jining, and ³Tongji Hospital of Tongji University, 389 Xincun Road, Putuo District, Shanghai 200065, China. *E-mail: zhaomyco@163.com[#]These authors contributed equally to this paper.

Accepted Oct 13, 2015; Epub ahead of print Oct 14, 2015

Acne inversa (AI; also known as hidradenitis suppurativa; OMIM:142690) is a chronic follicular occlusive skin disorder that usually starts after puberty and is characterized by recurrent abscesses, draining sinuses and progressive scarring in apocrine gland-bearing areas of the body, most commonly the axillae, anorectal and perineal areas. Although AI was considered a rare disease in the past, the disorder has been estimated to have a prevalence rate of about 1% in the general population, and one-third of patients with AI are estimated to have a positive family history (1, 2). The pathogenesis of AI is complex and far from fully clarified, but several factors, such as obesity, smoking, hormones, secondary bacterial infections and genetic factors, seem to play a role (1–3). In 2006, Gao et al. (4) mapped the genetic locus responsible for AI to chromosome 1p21.1–1q25.3. Wang et al. (5) performed linkage analyses and whole-exome sequencing and, in 2010, identified λ -secretase genes as a cause of AI. Recently, a spectrum of pathogenic mutations in λ -secretase genes in AI pedigrees has been reported (6, 7).

CASE REPORT

A 4-generation Chinese family with AI was analysed following initial identification of a 40-year-old proband (Fig. 1B and 1C) from Fujian, China. The pedigree (Fig. 1A) consisted of 39 individuals and showed an autosomal dominant inheritance pattern with full penetrance. The proband (III:3 in the pedigree), a 40-year-old man, was referred to our department due to a 23-year history of skin manifestations. The lesions had started when he was 17 years of age. Recurrent inflammatory papules, painful nodules, abscesses and scarring started on the buttocks and groin and subsequently involved the face, scalp, axillae and back. He had been treated with several systemic antibiotics (doxycycline, cefotaxime) without significant improvement of the disease. A histopathological examination of tissue from the buttocks showed perifollicular inflammation, occlusion in combination with hyperkeratinization and follicular dilatation in the dermis. All affected individuals in this family had similar clinical manifestations. Notably, the female patients (the mother, 2 aunts and 1 sister of the proband) had milder lesions than the male patients (the uncle, 5 younger brothers and son of the proband). All patients had normal intellectual ability and no neuropsychiatric disorders or behavioural problems. Based on these findings, a clinical diagnosis of AI was made.

To confirm the diagnosis, we examined the λ -secretase genes (*NCSTN*, *PSENI*, *PSENE* and *APH1*) for mutations. After informed consent was obtained, blood samples with added ethylenediaminetetraacetic acid (EDTA) and whole-blood samples with added anticoagulant were sent for genotyping, and DNA was isolated using a standard procedure. All coding regions

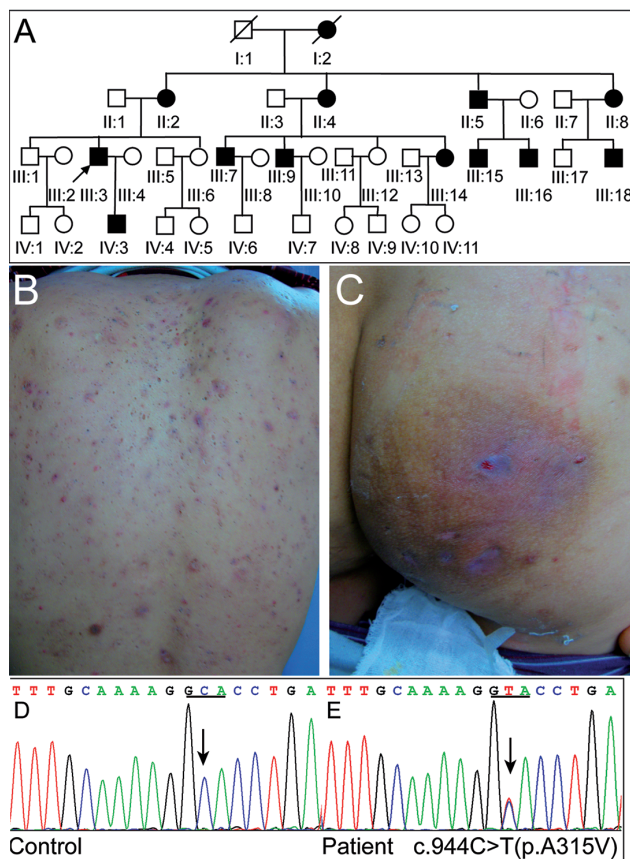


Fig. 1. Clinical and genetic features of the acne inversa (AI) pedigree. (A) A genealogical tree of the large Chinese family in this study. The index patient is indicated by an arrow. (B, C) The clinical appearance of the proband included inflammatory papules, nodules, abscesses, sinuses and scarring on (B) the back and (C) the buttocks. (D, E) Sequencing chromatograms showed a wild-type sequence (black arrow; D) and a missense mutation (c.944C>T [p. A315V]; black arrow; E) in exon 8 of *NCSTN*.

and associated splice sites of the *NCSTN*, *PSENI*, *PSENE* and *APH1* genes were analysed. In addition, samples from 156 unrelated, population-matched controls were sequenced for mutations to exclude the possibility that any observed difference could be a polymorphism in a λ -secretase gene. The study was approved by the medical ethics committee of Tongji Hospital, Tongji University, Shanghai, China, and was conducted in accordance with the principles of the Declaration of Helsinki. Sequencing results revealed a novel missense mutation, c.944C>T, in exon 8 of the *NCSTN* gene (Fig. 1E). This mutation changed codon GCA at position 315 to GTA, leading to an alanine-to-valine substitution. The mutation segregated clearly with the disease phenotype in this family, and it was not detected in 156 unrelated, healthy Chinese individuals. Moreover, the mutation was not present in the National Center for

Biotechnology Information's single nucleotide polymorphism database, dbSNP137, or in the 1000 Genomes Project database (<http://www.ncbi.nlm.nih.gov/snp/>). Based on these findings, we conclude that p.A315V is a mutation that causes AI in this Chinese family.

DISCUSSION

In this study, we describe a large Chinese family with AI in which all affected family members harbour a heterozygous mutation in nicastrin (NCT), a component of γ -secretase. The λ -secretase is a transmembrane protease that mediates intramembrane cleavage of membrane proteins, such as amyloid precursor protein and Notch receptors. The complex consists of 4 components, presenilin (PS1 and PS2), presenilin enhancer 2 (PEN-2), anteriorpharynx-1 (APH-1) and NCT, and is responsible for intramembrane processing (8). The Notch signalling pathway is a highly conserved and ubiquitous cell signalling system that regulates cell fate determination. Alterations in the Notch pathway lead to epidermal and follicular abnormalities in mouse skin that are histopathologically similar to those observed in human AI (9, 10).

Our sequence analysis revealed a C-to-T transition mutation at codon 944 of the *NCSTN* gene, which was shown to co-segregate with the disease phenotype in affected family members. NCT, a type I transmembrane protein, contains 709 amino acids and accounts for approximately two-thirds of the 230-kDa apparent molecular mass of the intact human γ -secretase (11). The failure to detect this mutation in 156 normal *NCSTN* alleles suggests that this mutation is not a normal polymorphic variant of the *NCSTN* gene. The resulting alanine to valine substitution was associated with a unique phenotype of AI. This finding suggests that even subtle changes in amino acid sequences may lead to conformational alterations of the γ -secretase complex. The A315V substitution reported here is located within the ectodomain of NCT; this domain is thought to play a critical role in the recruitment of γ -secretase substrates (11, 12). We hypothesize that this mutation disrupts the structure of NCT, which is likely to be deleterious to the function of the γ -secretase complex.

However, the precise role of γ -secretase mutations in the pathogenesis of AI remains unclear. The results of this study provide further evidence that mutations resulting in the loss of function of components of the γ -secretase complex are involved in the pathogenesis of familial AI. To date, the overwhelming majority of AI-specific mutations that have been identified in genes encoding γ -secretase components occur within the *NCSTN* gene (6, 7). Moreover, that multiple mutations occur within the *NCSTN* gene supports the claims that mutational hot spots exist within this domain and

that this domain may play a key functional role in the pathogenesis of AI. It should, however, be noted that many patients have no mutations in *PSEN1*, *PSEN2*, *NCSTN*, *PSENE1*, *APH1A* or *APH1B* genes, and other factors are therefore likely to be involved (13). In conclusion, these results support a role for *NCSTN* in the pathogenesis of AI.

ACKNOWLEDGEMENTS

This study was supported in part by the National Natural Science Foundation of China (no. 81371726) and by the Medical Innovation Foundation of Fujian Province in China (no. 2014-CXB-27).

REFERENCES

1. Yazdanyar S, Jemec GB. Hidradenitis suppurativa: a review of cause and treatment. *Curr Opin Infect Dis* 2011; 24: 118–123.
2. Alikhan A, Lynch PJ, Eisen DB. Hidradenitis suppurativa: a comprehensive review. *J Am Acad Dermatol* 2009; 60: 539–563.
3. Revuz JE, Canoui-Poitrine F, Wolkenstein P, Viallette C, Gabison G, Pouget F, et al. Prevalence and factors associated with hidradenitis suppurativa: results from two case-control studies. *J Am Acad Dermatol* 2008; 59: 596–601.
4. Gao M, Wang PG, Cui Y, Yang S, Zhang YH, Lin D, et al. Inversa acne (hidradenitis suppurativa): a case report and identification of the locus at chromosome 1p21.1-1q25.3. *J Invest Dermatol* 2006; 126: 1302–1306.
5. Wang B, Yang W, Wen W, Sun J, Su B, Liu B, et al. Gamma-secretase gene mutations in familial acne inversa. *Science* 2010; 330: 1065.
6. Ingram JR, Piguat V. Phenotypic heterogeneity in hidradenitis suppurativa (acne inversa): classification is an essential step toward personalized therapy. *J Invest Dermatol* 2013; 133: 1453–1456.
7. Zhang X, Sisodia SS. Acne inversa caused by missense mutations in *NCSTN* is not fully compatible with impairments in Notch signaling. *J Invest Dermatol* 2015; 135: 618–620.
8. Kelleher RJ, 3rd, Shen J. Genetics. Gamma-secretase and human disease. *Science* 2010; 330: 1055–1056.
9. Yamamoto N, Tanigaki K, Han H, Hiai H, Honjo T. Notch/RBP-J signaling regulates epidermis/hair fate determination of hair follicular stem cells. *Curr Biol* 2003; 13: 333–338.
10. Pan Y, Lin MH, Tian X, Cheng HT, Gridley T, Shen J, et al. gamma-secretase functions through Notch signaling to maintain skin appendages but is not required for their patterning or initial morphogenesis. *Dev Cell* 2004; 7: 731–743.
11. Yu G, Nishimura M, Arawaka S, Levitan D, Zhang L, Tandon A, et al. Nicastrin modulates presenilin-mediated notch/glp-1 signal transduction and betaAPP processing. *Nature* 2000; 407: 48–54.
12. Shirotani K, Edbauer D, Capell A, Schmitz J, Steiner H, Haass C. Gamma-secretase activity is associated with a conformational change of nicastrin. *J Biol Chem* 2003; 278: 16474–16477.
13. Ingram JR, Wood M, John B, Butler R, Anstey AV. Absence of pathogenic gamma-secretase mutations in a South Wales cohort of familial and sporadic hidradenitis suppurativa (acne inversa). *Br J Dermatol* 2013; 168: 874–876.