

REVIEW ARTICLE

Diagnosis of Mastocytosis in Children and Adults in Daily Clinical Practice

Magdalena LANGE¹, Hanna ŁUGOWSKA-UMER¹, Marek NIEDOSZYTKO², Bartosz WASĄG³, Janusz LIMON³, Anton ŻAWROCKI⁴, Bogusław NEDOSZYTKO¹, Michał SOBJANEK¹, Katarzyna PLATA-NAZAR⁵ and Roman NOWICKI¹

Departments of ¹Dermatology, Venereology and Allergology, ²Allergology, ³Biology and Genetics, ⁴Pathology, and ⁵Pediatrics, Pediatric Gastroenterology, Hepatology and Nutrition, Medical University of Gdańsk, Gdańsk, Poland

Mastocytosis comprises a heterogeneous group of disorders characterized by clonal, neoplastic proliferation of mast cells accumulating in one or multiple organs. In the majority of cases skin involvement is the first clinical manifestation of the disease. Clinical work-up consists of a combination of morphological, immunohistochemical, flow cytometric immunophenotyping and molecular examination. Cutaneous mastocytosis predominates in children, whereas systemic mastocytosis is the most common form of the disease in adults. Therefore, different diagnostic algorithms have to be applied in adult patients and children with suspected mastocytosis. This comprehensive review presents currently defined variants of the disease and recommendations to facilitate diagnostic work-up in children and adults with suspected mastocytosis in daily clinical practice. Key words: mastocytosis; children; adults; diagnostic algorithm; tryptase; KIT D816V mutation.

Accepted Aug 11, 2015; Epub ahead of print Aug 13, 2015

Acta Derm Venereol 2016; 96: 292–297.

Hanna Ługowska-Umer, Department of Dermatology, Venereology and Allergology, Medical University of Gdańsk, 7 Dębinki St, PL-80-211 Gdańsk, Poland. E-mail: hannaumer@wp.pl

Mastocytosis is an unusual clonal disease of bone marrow-derived hematopoietic progenitor cells, which manifests with a broad spectrum of clinical and morphological appearances (1, 2). The WHO classification of tumours of hematopoietic and lymphoid tissues includes mastocytosis as 1 of 8 subcategories of myeloproliferative neoplasms (3). Mastocytosis is characterized by excessive proliferation of morphologically and immunophenotypically abnormal mast cells in the skin and in various tissues (1–6). Organ systems typically involved are the bone marrow, skin, liver, lymph nodes, and gastrointestinal tract. Childhood-onset mastocytosis is usually a skin-limited disease that spontaneously regresses with age, whereas adult-onset mastocytosis presents with multi-organ involvement and a persistent course (1, 2).

Somatic activating mutations of the proto-oncogen *KIT* are the most common casual genetic abnormali-

ties in mastocytosis (1, 2, 4). *KIT* oncogene encodes a transmembrane protein KIT (CD117), which is a type III receptor tyrosine kinase (2, 4, 6, 7). KIT is expressed by mast cells, hematopoietic progenitor cells, germ cells, melanocytes and interstitial cells of Cajal in the gastrointestinal tract (2). The interaction between KIT and its ligand, stem cell factor (SCF), plays a central role in regulating proliferation, growth, differentiation, adhesion, chemotaxis, and survival of mast cells (5, 6). A *KIT* D816V mutation has been found in approximately 90% of patients with systemic mastocytosis (SM)¹, irrespective of WHO SM subtype (1, 4, 6). D816V *KIT* mutation in exon 17 induces ligand-independent constitutive auto-phosphorylation of the KIT receptor, which results in dysregulation of the normal development and proliferation of mast cells and, in consequence, accumulation of these neoplastic cells in tissues (4, 7). Apart from D816V *KIT* mutation other less common *KIT* mutations have been detected in adult SM, including V560G, D815K, D816Y, D816F, D816H, among others (2, 4, 8, 9). Recent studies have indicated the clonal nature of childhood-onset mastocytosis, which may be associated with germline and acquired activating *KIT* mutations (10, 11). Bodemer et al. (11) screened the entire *KIT* coding sequence for mutations using skin lesional DNA obtained from children with cutaneous mastocytosis (CM) and found that 86% of these children had various alterations in *KIT*, mostly in exons 8 and 9 coding for the extracellular domain of KIT. Nevertheless, activating *KIT* mutations do not occur universally in patients with mastocytosis, and the significance of some oncogenic mutations in the pathogenesis of the disease remains unclear (1, 2, 6).

CM is defined by increased numbers of skin mast cells in the absence of the involvement of extracutaneous tissues (12, 13). In unclear cases, if the histology is not diagnostic, the presence of D816V *KIT* mutation at codon 816 in lesional skin confirms the clonal nature of cutaneous disease (12).

¹Frequently used abbreviations:

SM: systemic mastocytosis; CM: cutaneous mastocytosis; ISM: indolent systemic mastocytosis; ASM: aggressive systemic mastocytosis; MCAS: mast cells activation syndromes

SM is characterized by proliferation and accumulation of mast cells in the bone marrow and/or other internal organs, with or without skin involvement. The diagnosis of SM is based on the WHO criteria (Table I) (1–3). The presence of the major criterion and at least one of the minor criteria, or more than 2 minor criteria is required for diagnosis of SM (12). Clinical presentation of mastocytosis ranges from good-prognosis forms, such as: CM, indolent SM (ISM) and extracutaneous mastocytoma to poor-prognosis, advanced forms including aggressive SM (ASM), SM associated with clonal haematological non-mast cells lineage diseases (SM-AHNMD), mast cells leukaemia (MCL) and sarcoma (MCS) (1–3, 6, 14).

Clinical manifestation of the disease depends on both the tissue burden of mast cells and symptoms due to the release of mediators of mast cells (15–17). Mast cells are multipotent effector cells of the immune system that produce histamine, tryptase, chymase, carboxypeptidase A, heparin, chondroitin sulphate glycosaminoglycans, prostaglandin D₂, leukotrienes (LTC₄, LTD₄, LTE₄), vascular endothelial growth factor (VEGF), platelet-activating factor (PAF), multifunctional cytokines (tumour necrosis factor (TNF)- α , TNF- β , SCF, interleukin (IL)-1, IL-2, IL-3, IL-4, IL-5, IL-6, IL-9, IL-10, IL-13, granulocyte-macrophage colony-stimulating factor (GM-CSF)) and chemokines (IL-8, monocyte chemoattractant protein-1 (MCP-1), macrophage inflammatory protein-1 α (MIP-1 α)). However, the complete role of each mast cells-dependent mediator in the pathogenesis of mastocytosis remains unclear; these mediators are responsible for a wide variety of clinical symptoms (16, 17). The most frequently reported mast cells mediator-related symptoms in patients with mastocytosis are: flushing, itching, blistering, diarrhoea, abdominal cramping and pain, vomiting, peptic symptoms, hypotensive episodes with vascular collapse, anaphylaxis, headache and bone pain (16, 18). Other symptoms that are considered typical for mast cells activation syndromes (MCAS) include: urticaria, angioedema, nasal pruritus and congestion, wheezing, throat swelling, transient increase in serum tryptase levels and response to anti-mediator drugs (18). In patients without mastocytosis in the skin (MIS), who

present with MCAS symptoms and KIT D816V mutation and/or CD25-positive mast cells in bone marrow, monoclonal MCAS (MMCAS) should be diagnosed (18). The organ infiltration by mast cells in advanced mastocytosis leads to lymphadenopathies, liver failure, ascites, malabsorption, cytopaenias, osteopaenia, osteoporosis and osteolyses (1, 14, 17). This explains the heterogeneity of clinical manifestations of mastocytosis and makes the diagnosis difficult, particularly in cases without skin involvement (19).

The heterogeneity of clinical presentations of the disease mean that mastocytosis falls within the scope of interest of dermatologists, allergists, haematologists and paediatricians. This article provides a brief review of the literature concerning clinical aspects of mastocytosis in children and adults, including newly described variants of the disease. It focuses in particular on the refinement of diagnostic methods and presentation of currently recommended diagnostic algorithms.

PAEDIATRIC MASTOCYTOSIS

In contrast to adult-onset mastocytosis, childhood-onset mastocytosis usually consists of skin disease characterized by a benign and self-limiting course (13, 20, 21). Based on the patterns of skin lesions 3 major clinical manifestations of CM are distinguished: maculopapular type (MPCM), diffuse cutaneous mastocytosis (DCM) and solitary mastocytoma of the skin (12, 13). Mechanical irritation of skin lesions leads to release of mast cells mediators, and thus to reddening and urticarial swelling. This reaction is known as Darier's sign and is pathognomonic for all forms of CM (13, 21, 22). MPCM, historically termed "urticaria pigmentosa", is characterized by small, brown macules and papules. The plaque form consists of slightly tan-to-orange, flat, slightly elevated plaques up to several centimetres in diameter and usually occurs in infancy and early childhood. Hartmann & Henez (22) underline that the small MPCM lesions, which occur in children as well as in adults, rarely resolve spontaneously, in contrast to the plaque form, which usually disappears near to puberty. MPCM and mastocytoma are reported to be common clinical types of CM, in contrast to DCM, which is a rare finding (13, 22–24). Mastocytoma is a solitary nodular or plaque lesion, which resolves spontaneously with age.

DCM is the most severe form of CM, and is characterized by infiltration of mast cells involving almost the entire skin (21, 25, 26). DCM usually occurs at birth or in early infancy. Widespread haemorrhagic blisters may be the first clinical presentation of DCM (25, 26). Bullous lesions do not represent a specific subset of the CM phenotype. Bullae can occur in all forms of CM, particularly in infants. In cases of DCM blistering and severe mast cell-related symptoms have a tendency to

Table I. WHO diagnostic criteria for systemic mastocytosis (3)^a

Major criterion

Multifocal, compact infiltrates of MCs > 15 MCs in aggregates detected in sections of BM and/or other extracutaneous organs

Minor criteria

1. More than 25% of spindle-shaped MCs in BM smears
2. Aberrant expression of CD25 and/or CD2 by BMMC
3. Detection of D816V KIT mutation in BM
4. Serum tryptase levels exceeding 20 ng/ml (does not count in patients who have clonal haematological non-MCs lineage disease)

^aDiagnosis of systemic mastocytosis requires the major and 1 minor or 3 minor criteria.

MCs: mast cells, BM: bone marrow.

decrease or even disappear over time (26). A generalized thickening of the skin with leather-grain appearance and pronounced Darier's sign are prominent features of the disease in teenagers and adults with DCM (24, 25). Four variants of DCM have been described recently, including large haemorrhagic bullous, infiltrative small vesicular, pseudoxanthomatous and pachydermic forms (24–29). Due to a widespread and heavy load of mast cells in the entire skin, children with DCM experience flushing, itching, hypotension, anaphylactic shock, diarrhoea and gastrointestinal bleeding (26, 27, 30, 31). Triggering factors for mast cells degranulation are presented in Table II (16, 17, 21). The true incidence of anaphylactic shock in DCM is difficult to estimate because this form of CM is very rare. Heide et al. (25) did not identify any life-threatening events in their 8 DCM patients, in contrast to 3 of 10 patients diagnosed in our centre who experienced this complication (26). The literature review indicates that SM may occur in patients who initially present with DCM (24, 32–35). DCM cases associated with mast cells infiltration of the liver, spleen, lymph nodes and bone marrow, chronic diarrhoea, malnutrition and myeloproliferative disorders have been described (32–35). Taking these reports together with significant frequency of anaphylaxis in our series of DCM patients, we recommend more careful diagnosis, including multi-disciplinary consultations and monitoring of the disease.

The true incidence of SM in children is unknown. Alvarez-Twoose et al. (36) recognized 2 cases of SM in a group of 111 Spanish children with mastocytosis, Hannaford & Rogers (24) found SM in 2 of 173 children with mastocytosis in Australia, whereas Lange et al. (37) reported that only 1 of 101 children with mastocytosis in Poland progressed to SM. The literature review reveals that SM associated with acute myelomonocytic leukaemia and acute myeloid leukaemia (SM-AML) may occur in children (38–42). In the majority of these cases skin involvement was not present. Genetic examination of bone marrow revealed *KIT* mutations and/or chromosome t(8;21) in children with SM-AML (39–42). Interestingly, in 2 cases of childhood-onset

SM reported in 2013 internal organ involvement was associated with MPCM (42, 43).

The determination of tryptase levels appears to be a useful tool in monitoring patients with CM because it correlates closely with the disease course and is considered a marker of disease severity in both children and adults (20, 21, 36, 44). Taking into the consideration the low incidence of SM in children, we support the view that bone marrow biopsy in children should be performed only in selected cases if there is suspicion of SM or another haematological neoplasm (12, 20, 21). Published data indicate that tryptase levels may reflect an intensity of skin involvement (37, 44, 45). In our DCM cases highly elevated tryptase levels, particularly in the early stage of the disease, correlated with significant extent and severity of cutaneous lesions and mediator-related symptoms (26). Temporal decline in tryptase levels was associated with a tendency of improvement of these symptoms (26). Serum tryptase level has been proposed as an indicator of the total body burden of mast cells (12). This may explain the elevation of serum tryptase levels in DCM cases, which are characterized by infiltration of mast cells in the entire skin. On the other hand, a highly elevated serum tryptase level that increased over time was the first symptom of SM in a child diagnosed in our centre (37). Interestingly, this child presented only with several maculo-papular lesions on the trunk and face, as well as having recurrent flushing, frequent severe anaphylaxis provoked by emotional stress and eosinophilia. According to previously published recommendations and the authors' personal experience in the clinical care of patients with mastocytosis, a diagnostic algorithm for paediatric mastocytosis has been proposed (Fig. 1) (12, 15, 19–21). In substantial number of cases clinical investigation and the presence of Darier's sign are sufficient for the diagnosis of CM. In all clinically unclear cases, in which either Darier's sign is not pronounced or the skin lesions resemble other skin diseases that may mimic cutaneous mastocytosis (e.g. staphylococcal scalded skin syndrome, epidermolysis bullosa hereditaria, xanthomas) histopathology is required to establish the diagnosis. If the histology of the skin lesions is questionable due to polymorphic cell-infiltrate or low numbers of mast cells, then mutational analysis of *KIT* in affected skin is recommended. It is noteworthy that even if a *KIT* mutation is detectable in the skin or blood, or serum tryptase is moderately elevated, bone marrow biopsy is not required in children (19).

ADULT-ONSET MASTOCYTOSIS

SM in a predominant clinical manifestation of mastocytosis in adults (2, 3, 46, 47). SM is divided into 4 subcategories: (1) ISM, which usually is associated with skin involvement and a benign course; (2) SM-

Table II. *Triggering factors for mast cells (MCs) degranulation*

Trigger	
Physical agents	Heat, cold, mechanical irritation of the skin, fever, exercise, invasive diagnostic procedures
Environmental agents	Perfumes, pesticides
Emotional factors	Stress, anxiety
Venoms	Bee, wasp, fire ant, snake
Drugs	Aspirin and non-steroidal anti-inflammatory drugs, opioids, general and local anaesthesia, contrast media, interferon, 2-chlorodeoxyadenosine, hydroxyurea, vaccines, dextrans
Foods	Matured cheese, smoked meat, nuts, shellfish, chocolate and cocoa products, citric fruits, beans, tomato, spicy foods, additives: glutamate, sulphites
Miscellaneous	Menstruation, teething, alcohol

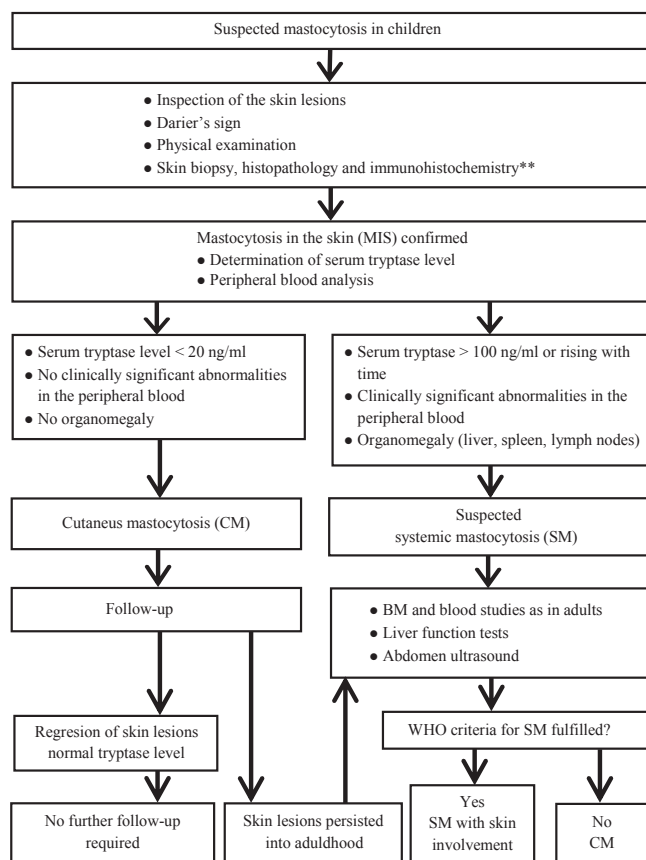


Fig. 1. Diagnostic algorithm for mastocytosis in children (12, 15, 19–21)*. *The proposal of the algorithm is based on previously published data and authors' clinical experience; **If the histology is questionable lesional skin should be examined for *KIT* mutation.

AHNMD, recognized when SM is associated with another clonal, haematological non-mast cells lineage disease; (3) ASM, which is characterized by life-threatening impaired organ function due to mast cells infiltration; and (4) MCL, in which bone marrow aspirate smears show >20% mast cells (3, 6). Patients with SM are categorized further according to the presence of "B and C findings", which assess disease burden and disease aggressiveness, respectively (6). B findings are: (1) infiltration grade of mast cells in bone marrow >30% on histology and serum total tryptase levels >200 ng/ml; (2) hypercellular bone marrow with loss of fat cells, discrete signs of dysmyelopoiesis without substantial cytopaenias or WHO criteria for myelodysplastic syndrome or myeloproliferative disorder; (3) hepatomegaly, splenomegaly, or lymphadenopathy without impaired organ function. C findings reflect impaired organ function because of infiltration of mast cells, and present as: (1) 1 or more cytopaenia(s), but no obvious non-mast cell hematopoietic malignancy; (2) hepatomegaly with ascites and impaired liver function; (3) palpable splenomegaly with hypersplenism; (4) malabsorption with hypoalbuminaemia and weight loss; (5) large osteolytic lesions and/or severe osteopo-

rosis causing pathological fractures (2, 6). In SM patients without these findings ISM is diagnosed, whereas those who have 2 or more B findings are categorized as smouldering SM (SSM), a subtype of ISM that has a more aggressive clinical course. Patients who meet C findings are categorized as ASM and are candidates for cytoreductive therapy (2, 6). In recent years 2 new subtypes of ISM have been described: isolated bone marrow mastocytosis (BMM) and well-differentiated SM (WDSM). BMM is characterized by a low burden of mast cells and lack of cutaneous involvement (3, 6). WDSM is diagnosed in cases with bone marrow infiltration by mature-appearing CD25 negative mast cells and the presence of non-D816V *KIT* mutation (48, 49).

DIAGNOSIS OF CUTANEOUS MASTOCYTOSIS

Diagnosis of MIS is established on clinical grounds, including skin manifestation of the disease and Darier's sign, and findings on skin biopsy. MIS is the pre-diagnostic checkpoint. In patients with MIS the exclusion of SM leads to the final diagnosis of CM. Skin infiltrate by mast cells can be visualized by the use of basic dyes, such as Giemsa, toluidine blue, and Astra blue, or by immunocytochemical stains, preferentially tryptase and anti-*KIT* (CD117) (2, 12, 13). Mast cell aggregates greater than 15 per cluster or scattering exceeding 20 cells in a high-power field detected in skin samples comply with the histological criterion of CM (12). If the histology is questionable lesional skin should be examined for D816V *KIT* mutation. Of note, neither tryptase nor CD117 immunostaining is able to distinguish between normal and neoplastic mast cells, which are characterized by atypical morphology and immunoreactivity for CD2 and/or CD25 (2, 5, 12).

DIAGNOSIS OF SYSTEMIC MASTOCYTOSIS

The criteria established by the WHO remain the gold standard for diagnosis of SM (3, 12). However, recent advances in the refinement of diagnostic methods provide new data to revise some aspects concerning diagnostic criteria and methods (6, 48–51). The presence of multifocal dense aggregates of mast cells in bone marrow has been categorized as major criterion of SM by the WHO diagnostic system. An important aspect is that this criterion is missed in a significant proportion of early stages of SM (48). Therefore, detection of activating *KIT* mutations and aberrant immunophenotypes of mast cells with the use of highly sensitive diagnostic methods plays a crucial role in proving the clonal nature of mastocytosis and recognizing SM (18, 46). These methods include multi-parametric flow cytometry and molecular analyses of highly purified bone marrow mast cells and other hematopoietic cells

(52, 53). Sensitivity of detection of *KIT* D816V mutation may be enhanced by enriching lesional mast cells (laser capture micro-dissection, magnetic-bead cell sorting, fluorescence-activated cell sorting (FACS)), or through the use of highly sensitive PCR techniques (2, 46, 52, 53). Currently, the most sensitive detection methods are real-time reverse-transcription PCR plus restriction fragment length polymorphism analysis, peptide nucleic acid-mediated PCR, and allele-specific quantitative real-time PCR (7, 46). In the presence of blood eosinophilia, screening for *FIP1L1-PDGFR*A and further haematological examinations are recommended to distinguish SM from chronic eosinophilic leukaemia (2). As far as the immunophenotype of BMMCs in SM is concerned, CD25 is the most sensitive parameter, typically expressed on the neoplastic mast cells and therefore recommended as the marker of choice (54). Recent studies indicate that BMMCs in advanced SM (ASM, MCL) often display lower levels of CD2 compared with ISM, and show strong expression of CD30 (Ki-1 antigen) (54, 55). The specificity of serum tryptase level persistently exceeding 20 ng/ml is limited by the finding that marked elevations in tryptase have been determined in other myeloid malignancies. However, further bone marrow histology allows detection of a second haematological neoplasm, if present. The tryptase level met SM criterion in 85% of SM patients in the largest study of 342 patients with mastocytosis (47). It should be emphasized that serum tryptase level determination is the only pre-invasive examination that is performed in routine diagnostic work-up and therefore is of great value. To check all other SM criteria it is necessary to perform bone marrow biopsy. The European Competence Network on Mastocytosis (ECNM) has established a diagnostic algorithm for patients with suspected mastocytosis (19). According to ECNM recommendations, in adult patients with MIS a bone marrow biopsy is required independently of the clinical course, symptoms and serum tryptase level (12, 19). As far as patients with no cutaneous involvement are concerned, diagnostic work-up depends on serum tryptase level and clinical symptoms. In those with unclear mediator-related symptoms and normal or slightly elevated serum tryptase a *KIT* mutation analysis using peripheral blood cells and a highly sensitive test such as DNA clamp PCR is recommended (9, 19). The presence of *KIT* D816V mutation in the peripheral blood is suggestive of SM (56). Therefore, in these patients bone marrow biopsy should be performed. The *KIT* D816V mutation analysis in the peripheral blood is an essential, currently proposed pre-invasive test in patients with suspected SM.

In patients with no evidence of MIS and clearly elevated serum tryptase and in those with a constantly increasing serum tryptase level bone marrow studies are indicated (19). Patients with the absence of skin invol-

vement who present mediator-related symptoms require allergy tests, internal disorder diagnostic procedures and consideration of MCAS in differential diagnosis (18, 19). It is noteworthy that serum tryptase levels increase during and shortly after an anaphylactic episode. Therefore, in patients with suspected mastocytosis, the tryptase level should be measured at least 24 h after complete resolution of all anaphylactic symptoms (12, 18). To facilitate routine work-up in adult-onset mastocytosis a proposed diagnostic algorithm is shown in Fig. 2 (2, 12, 18, 19). Based on previously published recommendations and our own experience in anaphylaxis, including more than 400 insect venom allergy cases, we have elaborated a practical diagnostic algorithm. In cases with excluded CM and tryptase level above 15 ng/ml, the analysis is repeated 3 times within a 6-month period. If at least 1 of the measurements exceeds 20 ng/ml a full bone marrow examination is performed. In case of a level below 20 ng/ml, *KIT* D816V mutation is analysed in the peripheral blood. All patients with mastocytosis should be followed-up, regardless of the clinical presentation of the disease and the patient's age.

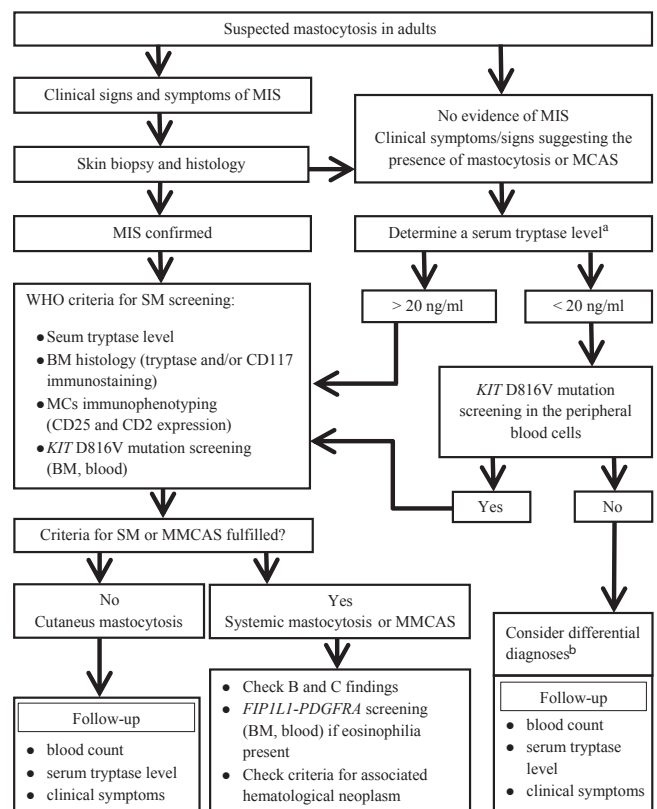


Fig. 2. Diagnostic algorithm for mastocytosis in adults (2, 12, 15, 18, 19); The proposal of the algorithm is based on previously published data and authors' clinical experience). ^aDetermine a serum tryptase level 3 times; consider the highest result. ^bHaematological disorders, non-haematological reactive disorders (allergic reactions, MCAS, atopic diseases, chronic inflammatory disease, chronic infections) and chronic severe renal failure among others. MIS: mastocytosis in the skin; MCAS: mast cell activation syndrome; MMCAS: monoclonal mast cell activation syndrome.

The frequency of serum tryptase determination should depend on the risk of a development of aggressive form of the disease. In patients presenting B findings serum tryptase is performed at least once within 3 months. In stable, uncomplicated cases serum tryptase can be measured at least once a year. In the majority of children with mastocytoma and plaque form of MPCM, follow-up including physical examination, clinical evaluation of skin lesions and mast cell mediator-related symptoms is sufficient. In children who present with small lesions MPCM, DCM, and in those with severe mediator-related symptoms, determination of serum tryptase level and blood count with differential are recommended once a year. All children with significant abnormalities in the peripheral blood, clearly elevated serum tryptase level and organomegaly at an initial visit, require further diagnostic procedures and more careful follow-up (20, 21). However, in children with spontaneous regression of CM after puberty and normal serum tryptase levels, further follow-up may be discontinued. In those patients in whom cutaneous manifestation of mastocytosis persist into adulthood, bone marrow studies are indicated (12, 19).

It is noteworthy that the great heterogeneity of mastocytosis, determined by a broad spectrum of symptoms, means that patients should be subject to a multidisciplinary approach and careful differential diagnosis.

ACKNOWLEDGEMENT

Funding sources: Polish Ministry of Science and Higher Education 02-0066/07/253.

The authors declare no conflicts of interest.

REFERENCES

1. Arock M, Valent P. Pathogenesis, classification and treatment of mastocytosis: state of the art in 2010 and future perspectives. *Exp Rev Hematol* 2010; 3: 497–516.
2. Pardanani A. Systemic mastocytosis in adults: 2013 Update on diagnosis, risk stratification and management. *Am J Hematol* 2013; 88: 613–624.
3. Horny HP, Akin C, Metcalfe DD, Escribano L, Bennett J M, Valent P, et al. Mastocytosis (Mast cell disease). In: Swerdlow SH, Campo E, Harris NL, editors. *World Health Organization (WHO) classification of tumors: pathology and genetics*. In: *Tumours of haematopoietic and lymphoid tissues* Lyon: IARC Press, 2008, p. 54–63.
4. Orfao A, Garcia-Montero AC, Sanchez L, Escribano L. Recent advances in the understanding of mastocytosis: the role of KIT mutations. *Br J Haematol* 2007; 138: 12–30.
5. Valent P, Cerny-Reiterer S, Herrmann H, Mirkina I, George T I, Sotlar K, et al. Phenotypic heterogeneity, novel diagnostic markers, and target expression profiles in normal and neoplastic human mast cells. *Best Pract Res Clin Haematol* 2010; 23: 369–378.
6. Quintas-Cardama A, Jain N, Verstovsek S. Advances and controversies in the diagnosis, pathogenesis, and treatment of systemic mastocytosis. *Cancer* 2011; 117: 5439–5449.
7. Erben P, Schwaab J, Metzgeorth G, Horny HP, Jawhar M, Sotlar K, et al. The KIT D816 expressed allele burden for diagnosis and disease monitoring of systemic mastocytosis. *Ann Hematol* 2014; 93: 81–88.
8. Garcia-Montero AC, Jara-Acevedo M, Teodosio C, Sanchez ML, Nunez R, Prados A, et al. KIT mutation in mast cells and other bone marrow hematopoietic cell lineages in systemic mast cell disorders: a prospective study of the Spanish Network on Mastocytosis (REMA) in a series of 113 patients. *Blood* 2006; 108: 2366–2372.
9. Sotlar K, Escribano L, Landt O, Möhrle S, Herrero S, Torrelo A, et al. One-step detection of c-kit point mutations using peptide nucleic acid-mediated polymerase chain reaction clamping and hybridization probes. *Am J Pathol* 2003; 162: 737–746.
10. Yanagori H, Oyama N, Nakamura K, Kaneko F. c-kit mutations in patients with childhood-onset mastocytosis and genotype-phenotype correlation. *J Mol Diagn* 2005; 7: 252–257.
11. Bodemer C, Hermine O, Palmerini F, Yang Y, Grandpeix-Guyodo C, Leventhal PS, et al. Pediatric mastocytosis is a clonal disease associated with D816V and other activating c-KIT mutations. *J Invest Dermatol* 2010; 130: 804–815.
12. Valent P, Akin C, Escribano L, Fodinger M, Hartmann K, Brockow K, et al. Standards and standardization in mastocytosis: consensus statements on diagnostics, treatment recommendations and response criteria. *Eur J Clin Invest* 2007; 37: 435–453.
13. Wolff K, Komar M, Petzelbauer P. Clinical and histopathological aspects of cutaneous mastocytosis. *Leuk Res* 2001; 25: 519–528.
14. Escribano L, Alvarez-Twose I, Sanchez-Munoz L, Garcia-Montero A, Nunez R, Almeida J, et al. Prognosis in adult indolent systemic mastocytosis: a long-term study of the Spanish Network on mastocytosis in a series of 145 patients. *J Allergy Clin Immunol* 2009; 124: 514–521.
15. Lange M, Nedoszytko B, Górska A, Żawrocki A, Sobjanek M, Kozłowski D. Mastocytosis in children and adults: clinical disease heterogeneity. *Arch Med Sci* 2012; 8: 533–541.
16. Escribano L, Akin C, Castells M, Schwartz LB. Current options in the treatment of mast cell mediator-related symptoms in mastocytosis. *Allergy* 2006; 5: 61–77.
17. Niedoszytko M, de Monchy J, van Doormaal JJ, Jassem E, Oude Elbering JN. Mastocytosis and insect venom allergy: diagnosis, safety, and efficacy of venom immunotherapy. *Allergy* 2009; 64: 1237–1245.
18. Valent P, Akin C, Arock M, Brockow K, Butterfield JH, Carter MC, et al. Definitions, criteria and global classification of mast cell disorders with special reference to mast cell activation syndromes: a consensus proposal. *Int Arch Allergy Immunol* 2012; 157: 215–225.
19. Valent P, Escribano L, Broesby-Olsen S, Hartmann K, Grattan C, Brockow K, et al. Proposed diagnostic algorithm for patients with suspected mastocytosis; a proposal of the European Competence Network on Mastocytosis. *Allergy* 2014; 69:1267–1274.
20. Heide R, Beishuizen A, de Groot H, den Hollander JC, van Doormaal JJ, de Monchy JGR, et al. Mastocytosis in children: a protocol for management. *Pediatr Dermatol* 2008; 25: 493–500.
21. Castells M, Metcalfe DD, Escribano L. Diagnosis and treatment of cutaneous mastocytosis in children. *Am J Clin Dermatol* 2011; 12: 259–270.
22. Hartmann K, Henez BM. Classification of cutaneous mastocytosis: a modified consensus proposal. *Luek Res* 2002; 26: 483–484.
23. Morren MA, Hoppe A, Renard M, Debiec Rychert M,

- Uytenbroeck A, Dubrenil P, et al. Imatinib mesylate in the treatment of diffuse cutaneous mastocytosis. *J Pediatr* 2013; 162: 205–207.
24. Hannaford R, Rogers M. Presentation of cutaneous mastocytosis in 173 children. *Aust J Dermatol* 2001; 42: 15–21.
 25. Heide R, Zuidema E, Beishuizen A, van Gysel D, Seyger MMB, Pasmans SGMA, et al. Clinical aspects of diffuse cutaneous mastocytosis in children: two variants. *Dermatology* 2009; 219: 309–315.
 26. Lange M, Niedoszytko M, Niedoszytko B, Łata J, Trzeciak M, Biernat W. Diffuse cutaneous mastocytosis: analysis of 10 cases and a brief review of the literature. *J Eur Acad Dermatol Venereol* 2012; 26: 1565–1571.
 27. Srivastava N, Chand S, Singh S. Pseudoxanthomatous mastocytosis. *Int J Dermatol* 2008; 47: 50–51.
 28. Kleewein K, Lang R, Diem A, Vogel T, Pohla-Grubo G, Bauer JW, et al. Diffuse Cutaneous Mastocytosis masquerading as epidermolysis bullosa. *Pediatr Dermatol* 2011; 28: 720–725.
 29. Sanchez-Salas MP, Lazaro AC, Martin J, Grasa MP, Carapeto FJ. Atypical pachydermatous cutaneous course of mastocytosis. *Actas Dermosifiliogr* 2007; 98: 707–710.
 30. Murphy M, Walsh D, Drumm B, Watson R. Bullous mastocytosis: a fatal outcome. *Pediatr Dermatol* 1999; 16: 452–455.
 31. Simone J, Hayes W. Bullous urticaria pigmentosa with bleeding. *J Pediatr* 1971; 78: 189–192.
 32. Waxtein LM, Vega-Memije ME, Cortes-Franco R, Domingues-Soto L. Diffuse cutaneous mastocytosis with bone marrow infiltration in a child: a case report. *Pediatr Dermatol* 2000; 3: 198–201.
 33. Shah PY, Sharma V, Worobec AS, Metcalfe DD, Zwick DC. Congenital bullous mastocytosis with myeloproliferative disorder and c-kit mutation. *J Am Acad Dermatol* 1998; 39: 119–121.
 34. Angus J, Leach IH, Grant J, Ravenscroft. Systemic mastocytosis with diffuse cutaneous involvement and haematological disease presenting in utero treated unsuccessfully with vincristine. *Clin Exp Dermatol* 2007; 33: 36–39.
 35. Olgun N, Oren H, Oren B, Irken G, Polat M, Cevik N. Diffuse erythrodermic cutaneous mastocytosis with bone marrow infiltration. *Dermatology* 1993; 2: 127–129.
 36. Alvarez-Twose I, Vano-Galvan S, Sanchez-Munoz L, Morgado JM, Matito A, Torrelo A, et al. Increased serum baseline tryptase levels and extensive skin involvement are predictors for the severity of mast cell activation episodes in children with mastocytosis. *Allergy* 2012; 67: 813–821.
 37. Lange M, Niedoszytko M, Renke J, Gleń J, Niedoszytko B. Clinical aspects of paediatric mastocytosis: a review of 101 cases. *J Eur Acad Dermatol Venereol* 2013; 27: 97–102.
 38. Kar R, Rao S, Pati HP. Systemic mastocytosis with acute myelomonocytic leukemia: a case report. *Indian J Hematol Blood Transfus* 2008; 24: 182–185.
 39. Mamadeo KM, Wolgast L, McMahon C, Cole PD. Systemic mastocytosis in a child with t(8;21) acute myeloid leukemia. *Pediatr Blood Cancer* 2011; 57: 684–687.
 40. Yabe M, Masukawa A, Kato S, Yabe H, Nakamura N, Matsushita H. Systemic mastocytosis associated with t(8;21) acute myeloid leukemia in a child: detection of the D816A mutation of KIT. *Pediatr Blood Cancer* 2012; 59: 1313–1316.
 41. Gadage VS, Kadam Amare PS, Galani KS, Mittal N. Systemic mastocytosis with associated acute myeloid leukemia with t(8;21) (q22;q22). *Indian J Pathol Microbiol* 2012; 55: 409–412.
 42. Gogia A, Sharawat SK, Kumar R, Sarkar C, Bakhshi S. Systemic mastocytosis associated with childhood acute myeloid leukemia. *J Pediatr Hematol Oncol* 2013; 35: 163–164.
 43. Synakiewicz A, Stachowicz-Stencel T, Renke J, Lange M, Adamkiewicz-Drożyńska E, Balcerska A. Systemic mastocytosis in children – therapeutic problems. *Dev Period Med* 2013; 17: 126–129.
 44. Matito A, Morgado JM, Álvarez-Twose I, Sánchez-Muñoz L, Pedreira CE, Jara-Acevedo M, et al. Serum tryptase monitoring in indolent systemic mastocytosis: association with disease features and patient outcome. *Plos One* 2013; 8: e76116.
 45. Heide R, van Dorn K, Mulder PG, van Toorenenbergen AW, Beishuizen A, de Groot H, et al. Serum tryptase and SCORMA (SCORing MASTocytosis) Index as disease severity parameters in childhood and adult cutaneous mastocytosis. *Clin Exp Dermatol* 2008; 34: 462–468.
 46. Verstovsek S. Advanced systemic mastocytosis: the impact of KIT mutations in diagnosis, treatment, and progression. *Eur J Hematol* 2012; 90: 89–98.
 47. Lim KH, Tefferi A, Lasho TL, Finke C, Patnaik M, Butterfield JH, et al. Systemic mastocytosis in 342 consecutive adults: survival studies and prognostic factors. *Blood* 2009; 113: 5727–5736.
 48. Sanchez-Munoz L, Alvarez-Twose I, Garcia-Montero AC, Teodosio C, Jara-Acevedo M, Pedreira CE, et al. Evaluation of the WHO criteria for the classification of patients with mastocytosis. *Mod. Pathol* 2011; 24: 1157–1168.
 49. Sperr WR, Valent P. Diagnosis, progression patterns and prognostication in mastocytosis. *Exp Rev Hematol* 2012; 5: 261–274.
 50. Schwaab J, Schnittger S, Sotlar K, Walz C, Fabarius A, Pffirmann M, et al. Comprehensive mutational profiling in advanced systemic mastocytosis. *Blood* 2013; 122: 2460–2466.
 51. Teodosio C, Garcia-Montero AC, Jara-Acevedo M, Sanchez-Munoz L, Alvarez-Twose I, Nunez R, et al. Mast cells from different molecular and prognostic subtypes of systemic mastocytosis display distinct immunophenotypes. *J Allergy Clin Immunol* 2010; 125: 719–726.
 52. Alvarez-Twose I, Morgado JM, Sanchez-Munoz L, Jara-Acevedo M, Alvarez-Twose I, Matito A, et al. Current state of biology and diagnosis of clonal mast cell diseases in adults. *Int Jnl Lab Hem* 2012; 34: 445–460.
 53. Sotlar K, Colak S, Bache A, Berezowska S, Krokowski M, Bultmann B, et al. Variable presence of KIT(D816V) in clonal haematological non-mast cell lineage diseases associated with systemic mastocytosis (SM-AHNMD). *J Pathol* 2010; 220: 586–595.
 54. Morgado JM, Sanchez-Munoz L, Teodosio CG, Jara-Acevedo M, Alvarez-Twose I, Matito A, et al. Immunophenotyping in systemic mastocytosis diagnosis: CD25 positive alone is more informative than the CD25 and/or CD2. *Mod Pathol* 2012; 25: 516–521.
 55. Valent P, Sotlar K, Horny H-P. Aberrant expression of CD30 in aggressive systemic mastocytosis and mast cell leukemia: a differential diagnosis to consider in aggressive hematopoietic CD30-positive neoplasms. *Leuk Lymph* 2011; 52: 740–744.
 56. Kristensen T, Broesby-Olsen S, Vestergaard H, Bindsvlev-Jensen C, Møller MB. Mastocytosis Centre Odense University Hospital (MastOUH). Circulating KIT D816V mutation-positive non-mast cells in peripheral blood are characteristic of indolent systemic mastocytosis. *Eur J Haematol* 2012; 89: 42–46.