

SHORT COMMUNICATION

The Adult Phenotype of Tuberous Sclerosis Complex

Neera Nathan^{1,2}, Kristina Burke³, Cory Trickett⁴, Joel Moss² and Thomas N. Darling^{1*}

¹Department of Dermatology, Uniformed Services University of Health Sciences, Bethesda, Maryland, USA 20814 ²Cardiovascular and Pulmonary Branch, National Heart, Lung, and Blood Institute, National Institutes of Health, Bethesda, ³Department of Dermatology, Madigan Army Medical Center, Tacoma, and ⁴Department of Dermatology, Blanchfield Army Community Hospital, Ft. Campbell, USA. E-mail: thomas.darling@usuhs.edu
Accepted Aug 4, 2015; Epub ahead of print Aug 10, 2015

Tuberous sclerosis complex (TSC) is an autosomal dominant neurocutaneous syndrome characterized by hamartomatous growths in multiple organ systems (1). Over 80% of patients with TSC will be diagnosed in early life, often secondary to presence of seizures or hypomelanotic macules (2). Nevertheless, there remains a subset where presentation is delayed until adulthood (3). Our prior work in a cohort of adults highlighted unrecognized lymphangiomyomatosis (LAM), a disease caused by proliferation of smooth muscle-like cells in the lungs, kidneys, and axial lymphatics that occurs almost exclusively in adult women (3). Herein, we add the presentation of TSC in adult men to emphasize the unique phenotype, including multifocal micronodular pneumocyte hyperplasia (MMPH). Furthermore, these patients lacked seizures or intellectual impairment but still exhibited types of brain dysfunction encompassed by the newly coined term TSC-associated neuropsychiatric disorders (TAND).

METHODS

We performed a retrospective review of medical records from patients recruited for studies of TSC at the National Institutes of Health Clinical Center in Bethesda, Maryland from 1998 to 2013. Five patients met inclusion criteria of male gender and diagnosis of TSC in adulthood (≥ 18 years old) according to the most recent clinical diagnostic criteria (4, 5). Data from clinical notes and radiological imaging for each patient was collected. Written informed consent was obtained to protocols 00-H-0051, 95-H-0186 and/or 82-H-0032, which were approved by the National Heart, Lung, and Blood Institute Institutional Review Board.

RESULTS

Significant findings and age of onset of TSC-related lesions (when known) in the 5 patients are shown in Table I. Median age of diagnosis of TSC was 30 years (range 21–43). By time of diagnosis, all patients had significant visceral disease, including bilateral renal angiomyolipomas (3 of 5 patients)

and MMPH ($n=3$). Three patients were affected by TAND, including depression ($n=2$), bipolar disorder ($n=1$) and anxiety disorder ($n=1$). No patients had active epilepsy; although, two patients reported a history of seizures in childhood. Additional patient history is presented below:

Patient 1 reported presence of angiofibromas since age 4, although he did not manifest a second major feature (ungual fibromas) until age 21, leading to TSC diagnosis. At age 28, he was diagnosed with bilateral renal angiomyolipomas. At age 52, he was diagnosed with MMPH by routine computed tomography (CT) scan of the chest.

Patient 2 was diagnosed with possible TSC at age 15 after skin biopsy confirmed the presence of angiofibromas. After a bout of flank pain at age 31, ultrasound revealed bilateral renal angiomyolipomas, at which time he received a TSC diagnosis. His right-sided angiomyolipoma was treated with embolization. Chest CT scan performed at age 31 was initially read as “irregular nodules possibly consistent with scarring”, and later determined to represent MMPH. Dermatological examination confirmed the presence of angiofibromas and revealed subtle nail pathology (Fig. 1).

Patient 3 had two cutaneous major features present during his teens (angiofibromas and unguinal fibromas), although not recognized until age 28. Past medical history was notable for a spontaneous pneumothorax at age 44, which prompted consideration of LAM. Chest CT scan failed to reveal any cystic changes; instead, it demonstrated scattered pulmonary nodules that were interpreted initially as “pulmonary metastatic disease”, which we determined to represent MMPH.

Table I. Characteristics of 5 men with adult diagnosis of tuberous sclerosis complex

Pat. No.	Cutaneous major features (age manifested)	Other TSC-associated internal disease (age diagnosed)	Family history of TSC	Age of first cutaneous major feature	Age of diagnosis
1	Angiofibromas (4) Ungual fibromas (21)	Angiomyolipomas (28) MMPH (52) Depression	Yes	4	21
2	Angiofibromas (15) Ungual fibromas (31)	Angiomyolipomas (31) MMPH (31) Cortical dysplasia (31) Anxiety	No	15	31
3	Angiofibromas (teens) Ungual fibromas (teens) Hypomelanotic macules	MMPH (47) Multiple renal cysts	No	Teens	28
4	Ungual fibromas (childhood) Hypomelanotic macules (childhood)	Subependymal nodules (30) Nonrenal hamartoma (46) Depression Bipolar disorder	Yes	Childhood	43
5	Angiofibromas (6) Fibrous cephalic plaque (birth) Shagreen patch	Angiomyolipomas (27)	No	Birth	26

TSC: tuberous sclerosis complex; MMPH: multifocal micronodular pneumocyte hyperplasia.

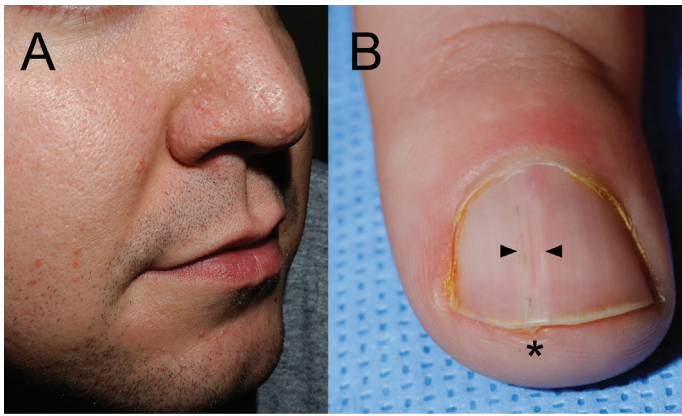


Fig 1. Subtle cutaneous manifestations of tuberous sclerosis complex. (A). Angiofibromas of the nose and medial cheek. (B) Ungual fibroma (black arrowheads) with distal hyperkeratosis (black star).

Patient 4 reports presence of one (multiple hypomelanotic macules), if not two (ungual fibromas) cutaneous major features since childhood, and a third major feature (subependymal nodules) discovered at age 30. Diagnosis was made at age 43 while participating in a family medical evaluation in response to a relative with seizures. Chest CT scan was unremarkable.

Patient 5 manifested at least one and possibly two cutaneous major features early in life (angiofibromas/fibrous cephalic plaque and shagreen patch), though these features were not noticed until age 26. Renal ultrasound revealed bilateral renal angiomyolipomas; subsequently, treatment with sirolimus 2 mg daily was initiated. Follow-up imaging at 6 months showed a decrease in maximum tumor length from 15.6 cm to 12.5 cm. Chest CT scan was within normal limits.

DISCUSSION

The cutaneous features most frequently apparent in these men were angiofibromas followed by unguinal fibromas, which is consistent with our prior cohort of adult women (3). While hypomelanotic macules are the more frequent cutaneous presentation of TSC in children (1), they fade with age and are detected less frequently in older patients (3, 6). Congenital onset may help distinguish TSC-related hypomelanotic macules from acquired causes of hypopigmentation common in adults, such as vitiligo, idiopathic guttate hypomelanosis, post-inflammatory hypopigmentation and hypopigmented scars (7).

Skin lesions are among the most common manifestations of TSC in adult patients (3, 8). An important point is that absence of seizures in adult patients presenting with TSC-related skin findings should not dampen TSC consideration. Rather, seizures are not common in adult TSC patients (9).

Additionally, most patients diagnosed with TSC in adulthood do not have profound intellectual deficits. Instead, they may exhibit a range of behavioral, social, psychiatric, and intellectual difficulties, called TAND (10). TAND affects many adult TSC patients including 3 men in our cohort, and necessitates recognition, facilitated by a TAND checklist (10), and treatment. In

addition to TAND, renal angiomyolipomas and pulmonary lymphangiomyomatosis are manifestations of TSC in adulthood that require proper management, which can include initiation of an oral mTOR inhibitor (11). After identifying TSC in Patient 5, we commenced oral sirolimus to treat his bilateral renal angiomyolipomas. This treatment effectively decreased his tumor volume, which may lessen hemorrhage risk, as there is evidence that larger angiomyolipomas are prone to bleeding (12).

MMPH is a common pulmonary manifestation of TSC in adulthood. It is characterized by hamartomatous proliferation of type II pneumocytes that appear as solid or ground-glass nodules on CT scan. More than half of men with TSC may have MMPH (13); however, it is usually asymptomatic and thus more likely to be uncovered as part of routine or incidental imaging. Without knowing that someone has TSC, the differential diagnosis of multiple pulmonary nodules favors metastatic cancer (misdiagnosed in patient 3), followed by granulomas or scars (misdiagnosed in patient 2) (14). A patient with kidney masses, if not known to have TSC, may be presumed to have renal cell carcinoma, particularly if accompanied by MMPH interpreted as lung metastases, potentially resulting in surgical intervention for benign hamartomas. In fact, one of our patients was being considered for a brain biopsy to evaluate for a possible primary cancer before it was realized that he had TSC and cortical tubers. Thus, pinpointing subtle cutaneous features of TSC in adult patients is pivotal not only to uncover internal disease, but also to correctly attribute it to TSC.

ACKNOWLEDGEMENTS

J.M. was supported by the Intramural Research Program, NIH, National Heart, Lung, and Blood Institute, Bethesda, MD. This research was made possible through the NIH Medical Research Scholars Program and a Doris Duke Charitable Foundation Clinical Research Mentorship award 2014088.

Disclaimer: The opinions presented in this article are those of the authors and do not necessarily represent those of the US Army, Department of Defense, or the US Government; and do not constitute official policy.

REFERENCES

- Curatolo P, Bombardieri R, Jozwiak S. Tuberous sclerosis. *Lancet* 2008; 372: 657–668.
- Józwiak S, Schwartz RA, Janniger CK, Michalowicz R, Chmielik J. Skin lesions in children with tuberous sclerosis complex: their prevalence, natural course, and diagnostic significance. *Int J Dermatol* 1998; 37: 911–917.
- Seibert D, Hong CH, Takeuchi F, Olsen C, Hathaway O, Moss J, et al. Recognition of tuberous sclerosis in adult women: delayed presentation with life-threatening consequences. *Ann Intern Med* 2011; 154: 806–813.
- Northrup H, Krueger DA, International Tuberous Sclerosis Complex Consensus Group. Tuberous sclerosis complex

- diagnostic criteria update: recommendations of the 2012 International Tuberous Sclerosis Complex Consensus Conference. *Pediatr Neurol* 2013; 49: 243–254.
5. Teng JM, Cowen EW, Wataya-Kaneda M, Gosnell ES, Witman PM, Hebert AA, et al. Dermatologic and dental aspects of the 2012 International Tuberous Sclerosis Complex Consensus Statements. *JAMA Dermatol* 2014; 150: 1095–1101.
 6. Wataya-Kaneda M, Tanaka M, Hamasaki T, Katayama I. Trends in the prevalence of tuberous sclerosis complex manifestations: an epidemiological study of 166 Japanese patients. *PLoS One* 2013; 8: e63910.
 7. Vanderhooft SL, Francis JS, Pagon RA, Smith LT, Sybert VP. Prevalence of hypopigmented macules in a healthy population. *J Pediatr* 1996; 129: 355–361.
 8. Rentz AM, Skalicky AM, Liu Z, Wheless JW, Dunn DW, Frost MD, et al. Tuberous sclerosis complex: a survey of health care resource use and health burden. *Pediatr Neurol* 2015; 52: 435–441.
 9. Thiele EA, Granata T, Matricardi S, Chugani HT. Transition into adulthood: tuberous sclerosis complex, Sturge-Weber syndrome, and Rasmussen encephalitis. *Epilepsia* 2014; 55: 29–33.
 10. de Vries PJ, Whittemore VH, Leclezio L, Byars AW, Dunn D, Ess KC, et al. Tuberous sclerosis associated neuropsychiatric disorders (TAND) and the TAND Checklist. *Pediatr Neurol* 2015; 52: 25–35.
 11. Krueger DA, Northrup H, International Tuberous Sclerosis Complex Consensus Group. Tuberous sclerosis complex surveillance and management: recommendations of the 2012 International Tuberous Sclerosis Complex Consensus Conference. *Pediatr Neurol* 2013; 49: 255–265.
 12. Bissler JJ, Kingswood JC. Renal angiomyolipomata. *Kidney Int* 2004; 66: 924–934.
 13. Muzykewicz DA, Black ME, Muse V, Numis AL, Rajagopal J, Thiele EA, et al. Multifocal micronodular pneumocyte hyperplasia: computed tomographic appearance and follow-up in tuberous sclerosis complex. *J Comput Assist Tomo* 2012; 36: 518–522.
 14. Gross BH, Glazer GM, Bookstein FL. Multiple pulmonary nodules detected by computed tomography: diagnostic implications. *J Comput Assist Tomo* 1985; 9: 880–885.