

CLINICAL REPORT

Vulvovaginal-gingival Lichen Planus: Association with Lichen Planopilaris and Stratified Epithelium-specific Antinuclear Antibodies

Malgorzata OLSZEWSKA¹, Agnieszka BANKA-WRONA¹, Anna SKROK¹, Adriana RAKOWSKA¹, Renata GÓRSKA², Lynn W. SOLOMON³ and Lidia RUDNICKA^{1,4}

Departments of ¹Dermatology, ²Oral Medicine and Periodontology, Medical University of Warsaw, Warsaw, Poland, ³Department of Oral Diagnostic Sciences, Nova Southeastern University Fort Lauderdale, USA, and ⁴Department of Neuropeptides, Mossakowski Medical Research Centre, Polish Academy of Sciences, Warsaw, Poland

Vulvovaginal-gingival lichen planus (VVG-LP) consists of a triad of symptoms: vulval, vaginal and gingival lichen planus lesions. The aim of this study was to analyse the prevalence of lesions in various anatomical locations in patients with VVG-LP. The study included 126 consecutive patients with lichen planus. Sixteen (12.7%) patients fulfilled the criteria of VVG-LP. In 12/16 (75%) patients with VVG-LP scalp lesions were also observed. Stratified epithelium-specific antinuclear antibodies (SES-ANA) and anti- Δ Np.3 α antibodies were detected in 10/16 (75%) patients with VVG-LP and in 15/110 (13.6%) patients with other forms of lichen planus ($p < 0.05$). In conclusion, VVG-LP is frequently associated with lichen planopilaris. The new entity may be termed “vulvovaginal-gingival-pilar lichen planus” and our study indicates that SES-ANA is a marker of this type of lichen planus with extensive, severe and refractory-to-therapy involvement of the mucous membranes, skin and scalp. Key words: alopecia; chronic ulcerative stomatitis; dermoscopy; oral lichen planus; frontal fibrosing alopecia; vulvitis; trichoscopy.

Accepted May 11, 2015; Epub ahead of print May 27, 2015

Acta Derm Venereol 2016; 96: 92–96.

Malgorzata Olszewska, Department of Dermatology, Medical University of Warsaw, Koszykowa 82A, PL-02-008 Warsaw, Poland. E-mail: malgorzata.olszewska@wum.edu.pl

Pelisse (1) described a special form of lichen planus (LP), which consists of a triad of symptoms: vulval, vaginal and gingival LP lesions. The disorder is known as vulvovaginal-gingival lichen planus (VVG-LP) or vulvovaginal-gingival syndrome (1, 2). The terms: oro-vaginal-vulval LP and plurimucosal LP have been used by some authors as alternative names for the condition. A counterpart of this disease in men is termed peno-gingival LP (3–5). VVG-LP has usually a chronic course and requires more aggressive therapy than other types of LP.

Stratified epithelium-specific antinuclear antibodies (SES-ANA) were first described by Jaremko et al. (6) and Beutner et al. (7) and are considered the immunological

marker of chronic ulcerative stomatitis (8). These are IgG antibodies, which show speckle-patterned deposits in the nuclei of basal epithelial cells in indirect and direct immunofluorescence (7). The antigenic target of these autoantibodies has been identified as a 70-kDa non-transactivating isoform of p63, the Δ Np63 α (9). The presence of SES-ANA is a major diagnostic feature of chronic ulcerative stomatitis, but it may also occasionally be detected in patients with LP. According to a study by Parodi et al. (10), circulating SES-ANA may be detected in 13.8% of patients with cutaneous and mucosal LP. The clinical features of chronic ulcerative stomatitis and erosive mucosal LP are similar and differentiation of these diseases may be challenging. According to some researchers, the presence of circulating SES-ANA is the only feature that differentiates these 2 diseases (11). However, some authors believe that chronic ulcerative stomatitis is a disease in the broad spectrum of LP (10, 12).

The aim of this study was to analyse the prevalence of VVG-LP among patients presenting with LP and to analyse the possible association of VVG-LP with SES-ANA antibodies.

METHODS

A total of 126 consecutive patients with LP (median age 57 years; range 22–79 years; 110 women, 16 men) were included in the study. The study included patients from the Department of Dermatology at Medical University of Warsaw, Department of Dermatology at CSK MSW in Warsaw, and Specialisci Dermatologii S.C. Clinic in the years 2009–2014. The Department of Dermatology at Medical University of Warsaw is a general dermatology facility with special expertise in diseases of the oral and genital mucous membranes and hair disorders.

Each patient underwent detailed examination of the glabrous skin, scalp, oral and genital mucosa and nails. The diagnosis of LP in each location (except nails) was confirmed by histopathology.

Trichoscopy was performed in each patient, using the Fotofinder II videodermoscope (FotoFinder Systems GmbH, Bad Bimbach, Germany), to verify the diagnosis of lichen planopilaris and exclude other causes of hair loss (13, 14). At least one trichoscopy-guided biopsy, followed by routine histopathology evaluation, was performed in every patient with any scalp abnormality.

In each patient an indirect immunofluorescence test of the serum was performed with monkey and guinea pig oesophagus as substrates. In addition, direct immunofluorescence of a perilesional area was performed in patients with circulating

antinuclear antibodies. Both indirect and direct immunofluorescence tests were performed as described previously (8).

Detection of Δ Np63-specific IgG in patients' sera was performed by enzyme-linked immunosorbent assay (ELISA), as described previously (15).

The study was approved by the ethics committee of Medical University of Warsaw.

RESULTS

Of the 126 patients included in the study the largest group consisted of patients with skin involvement ($n=80$; 63.5%). Involvement of both skin and oral mucosa was observed in 39 patients (31.0%). Exclusive oral involvement was seen in 19 cases (15.1%). Detailed data are presented in Table I. A total of 16 patients (12.7%) revealed features of vulvovaginal-gingival syndrome. Detailed characteristics of women with vulvovaginal-gingival syndrome are shown in Table II. The median age of this group of patients was 59 years (range 55–73 years).

Desquamative gingivitis was present in all cases (100%). The other most common oral locations were the buccal mucosa (9/16, 56.3%) and the tongue (7/16, 43.8%). The reticular form, present in 14 cases (14/16, 87.5%), was most common. In 15 patients the erosive form of vulval involvement was observed (15/16, 93.8%). In all cases red erosive patches were observed in the vagina. In 1 case white reticular lesions, and in 2 cases vaginal stenosis requiring surgery were present. The scalp was the most frequently observed extramucosal location in this group (12 patients, 75.0%). Skin and nails were involved in 5 (31.3%) and 3 (18.8%) cases, respectively.

Lichen planopilaris of the scalp was observed in 12/16 (75%) patients with VVG-LP (Fig. 1 a–d). In 4/12 cases this was classic lichen planopilaris, in 6/12 frontal fibrosing alopecia, and in 2/12 coexistence of both diseases. One patient had a full manifestation of Graham-Little syndrome, and 2 patients had non-cicatricial alopecia

Table I. Localization of lesions in 126 patients with lichen planus

Location	n (%)
Single location	
Skin	32 (25.4)
Oral mucous membrane	19 (15.1)
Scalp	9 (7.1)
Nails	1 (0.8)
Two locations	
Oral mucous membrane and skin	39 (31.0)
Oral mucous membrane and scalp	6 (4.8)
Skin and scalp	4 (3.2)
Oral mucous membrane and anogenital mucous membranes	4 (3.2)
Three locations	
Oral mucous membrane, scalp, and anogenital mucous membranes	7 (5.6)
Four locations	
Oral mucous membrane, skin, scalp, and anogenital mucous membranes	2 (1.6)
Five locations	
Oral mucous membrane, skin, scalp, anogenital mucous membranes, and nails	3 (2.38)

Table II. Characteristics of 16 patients with vulvovaginal gingival lichen planus (women with both oral and anogenital mucosal involvement)

Skin, n (%)	5 (31.3)
Scalp, n (%)	12 (75)
Nails, n (%)	3 (18.8)
Stratified epithelium – specific antinuclear antibodies, n (%)	10 (62.5)

of the axillae in addition to classic lichen planopilaris of the scalp, but did not fulfil the criteria for this syndrome.

In all patients with classic lichen planopilaris trichoscopy milky-red to white areas lacking follicular openings were observed. In the periphery of these areas the predominant features were: tubular, perifollicular scaling and elongated blood vessels arranged concentrically around hair follicle openings. White dots were not present. In patients with frontal fibrosing alopecia trichoscopy showed mild to minor perifollicular scaling and areas lacking follicular openings.

In 25/126 (19.8%) of all patients with LP SES-ANA were detected in the serum by indirect immunofluorescence test. Ten (10/25, 40%) of the SES-ANA-positive patients presented features of VVG-LP. SES-ANA were present in only 5 cases in patients without genital involvement. The positive titres of SES-ANA ranged from 80 to 5,120 (median 1,280) on monkey oesophagus and from 1,280 to 40,960 (median 5,120) on guinea pig oesophagus as substrates. In 23/25 (92.0%) patients with circulating SES-ANA, the antibodies also were detected *in vivo* bound in the perilesional epithelium and epidermis. All patients (100%) with vulvovaginal-gingival syndrome and with circulating SES-ANA also had *in vivo* bound SES-ANA. In all (100%) SES-ANA positive patients ELISA confirmed the presence of anti- Δ Np63 α antibodies. A control group of 101 SES-ANA negative patients with LP were also negative for anti- Δ Np63 α antibodies.

SES-ANA were detected in 10/16 (62.5%) patients with VVG-LP. All except 2 of these patients had co-existing features of lichen planopilaris. Thus, 8/12 (66.7%) patients with “vulvovaginal-gingival-pilar lichen planus” tested positive for SES-ANA.

DISCUSSION

LP occurs in 0.44–2% of the population (16). There are variable data regarding the coexistence of LP lesions in various locations. It is believed that oral mucosa is often involved in patients with cutaneous LP. Bhattacharya et al. (17) found mucosal involvement in 16.8% and genital involvement in 5.2% of patients with cutaneous LP. Other authors report that genital LP is present in approximately 25–50% of women and 5–25% of men with cutaneous LP lesions (18–20). Kirtschig et al. (21) believe that mucosal vulval LP is more frequently associated with other mucosal lesions than skin lesions. The authors described a group of 44 patients with vulval LP, and

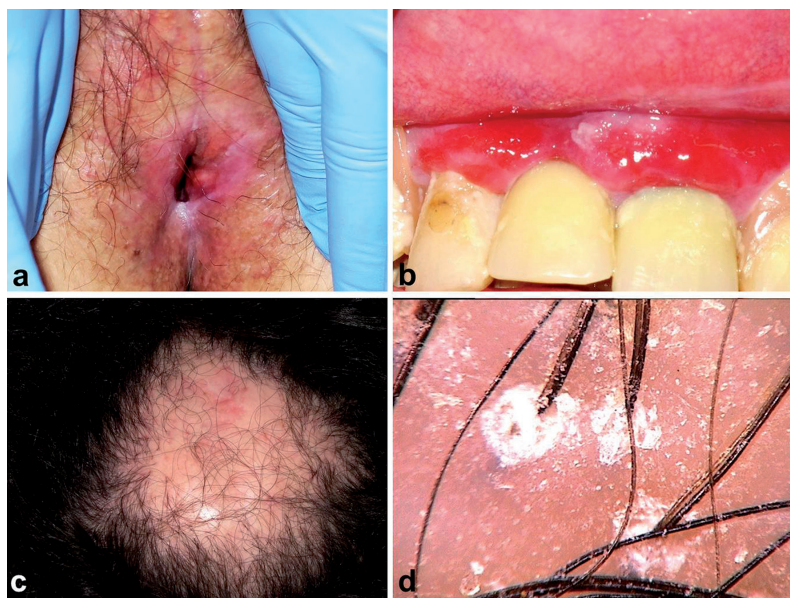


Fig. 1. Manifestations of vulvovaginal-gingival-pilar lichen planus. (a) Lichen planus of the vagina and vulva, (b) desquamative gingivitis, (c) lichen planopilaris. (d) Trichoscopy shows areas lacking follicular openings and perifollicular scaling.

found that oral involvement was more frequent in this group (30/44, 75%), compared with cutaneous lesions, which were observed in only 9/44 (20.4%) patients (21). Ebrahimi et al. (22) reported the coexistence of oral and genital lesions in 40% of men and 53% of women in a group of 120 patients with mucosal LP. Scalp and nail lesions are rarely observed in patients with oral LP. In a study of 584 patients with oral LP the percentage of patients with oral LP coexisting with scalp LP was 1.02% and nail involvement was 1.88% (23). These numbers may be an underestimate, since at the time the study was performed, by Doro Eisen, current techniques for differential diagnosis of alopecia (trichoscopy) and nail changes (onychoscopy) were not yet available (23). There are also reports in the literature on LP lesions in the oesophagus, the conjunctiva and the larynx (24–26). Our study did not include evaluation of these anatomical locations of the body.

The VVG-LP is a special form of LP with involvement of the genital and oral mucous membranes, first described by Pelisse et al. (2). This triad: vulvitis, vaginitis and gingivitis in patients with LP has also been described by Eisen (27), Rogers & Eisen (28) and Setterfield et al. (29). Di Fede (30) found that 27 patients had genital involvement out of 31 patients with oral LP (27/31, 87.1%), this study included both genital LP and lichen sclerosis. Danielsson et al. (31) analysed RNA expression in LP epithelium of the oral cavity, the genital area and normal counterparts. The authors found that 105 genes were up- or down-regulated in a similar manner in the oral cavity and the genital area, which led the authors to conclude that oral LP and genital LP are distinct clinical manifestations of the same disease.

It should be emphasized that the prevalence of VVG-LP is probably underestimated and that patients may be treated separately for their vulvitis and vaginitis by a gynaecologist and for their oral lesions by a dermatologist or a dentist. The aim of this study was to analyse the prevalence of VVG-LP among patients with any clinical manifestation of LP and to identify the characteristic clinical and immunological features of the syndrome beyond current descriptions. Our study included 126 consecutive patients with LP. In this group 16 women (12.7%) fulfilled the criteria of VVG-LP. Among these patients, only 4 (4/16, 25.0%) showed features of “pure” VVG-LP with exclusive involvement of oral and genital mucous membranes. In all other cases skin and/or scalp and/or nail involvement was observed. In 5/16 cases (31.3%) glabrous skin lesions were observed. This percentage is similar to the data presented by Setterfield et al. (29) (40%), but higher than observed by Rogers & Eisen (28) and Eisen et al. (18) in patients with VVG-LP (18%).

There are sparse data in the literature indicating a higher prevalence of scalp and nail lesions in the course of vulval LP than in typical mucosal LP (28, 29, 32). However, none of these studies focused on lichen planopilaris. Our study included a detailed clinical and trichoscopic analysis of the scalp in all patients with VVG-LP. Trichoscopy-guided biopsy (33, 34) was performed in all patients with any scalp abnormality either in clinical evaluation or in trichoscopy. In 12/16 (75.0%) patients with VVG-LP scalp LP was observed. In 4/12 cases this was classic lichen planopilaris, in 6/12 frontal fibrosing alopecia, and in 2/12 coexistence of both diseases. The results show a high prevalence of lichen planopilaris in the course of VVG-LP. We suggest the term “vulvovaginal-gingival-pilar LP” to describe this entity. Our experience shows that the condition has a particularly chronic course and is refractory to therapy. Our results also indicate the need for trichoscopy screening in all patients with LP in order to decrease the risk of missing early lichen planopilaris.

Setterfield et al. (29) stressed the relationship of VVG-LP with autoimmune diseases such as alopecia areata, vitiligo, autoimmune thyroiditis and specific HLA genes (HLA DQB1 * 0201). None of our patients with VVG-LP had alopecia areata or vitiligo during the study or in anamnesis. One patient was diagnosed with autoimmune thyroiditis. Neoplastic diseases have not been observed (35). The association between HLA antigens and LP has been studied extensively, but the findings are inconsistent (36).

There are no reports on the presence of antinuclear antibodies in VVG-LP. Setterfield et al. (29) detected

anti-basement membrane IgA antibodies in low titres in 2 patients with VVG-LP only. There are conflicting reports on the presence of various types of antinuclear antibodies detected in the serum of patients with various forms of LP. The reported percentage of patients with LP and coexisting antinuclear antibodies ranges from 3.2% to 13.8% (10, 12, 37). Some authors, however, deny the presence of antinuclear antibodies in the sera of patients with either cutaneous LP or mucosal LP (8, 29).

We investigated our patients for a specific type of antinuclear antibodies; stratified epithelium-specific antinuclear antibodies (SES-ANA). SES-ANA were first described by Jaremko et al. (6) and Beutner et al. (7) as a marker of chronic ulcerative stomatitis. These are IgG antibodies directed against stratified epithelium, bound *in vivo* in the oral mucosa and usually present in serum in high titres (1,280–20,480 on the guinea pig oesophagus as substrate and 1:20 to 1:10,240 on monkey oesophagus). The antibodies are directed against the nuclear antigens of cells in the basal and parabasal layers of squamous epithelium (6, 8). Lee et al. (38) and Solomon et al. (39) identified the Δ Np63 α protein as the autoantigen for SES-ANA (38, 39). This is one of 6 p63 protein isoforms (40, 41), encoded by a gene located on chromosome 3q27-29. P63 isoforms (TAp63 α , TAp63 β , TAp63 γ , Δ Np63 α , Δ Np63 β and Δ Np63 γ) are the result of alternative splicing or activation of different promoters. In 2011 Carlsol et al. demonstrated a direct pathogenic role of anti- Δ Np63 α IgG (42). The antibodies are blocking Δ Np63 α functions, and consequently cause a dysregulation of the expression and function of integrin α 6 β 4, resulting in erosive changes in the mucous membranes (in chronic ulcerative stomatitis).

Chronic ulcerative stomatitis is a rarely described entity (38, 43). Patients are most commonly women (over 90%) and the disease typically begins in the fifth or sixth decade of life (8, 43–45). Chorzelski et al. (8) developed criteria for diagnosis of the disease. The major criteria are: (i) the presence of erosions or exfoliative changes in the oral mucosa; and (ii) the presence of *in vivo* bound and circulating SES-ANA. The minor criteria are: (i) chronic and/or recurrent course; (ii) occurrence in peri- and postmenopausal women; and (iii) good response to treatment with chloroquine in monotherapy or in combination with low doses of corticosteroids. Fulfilment of both major criteria and 2 minor criteria is necessary to establish a diagnosis of chronic ulcerative stomatitis.

The relationship between chronic ulcerative stomatitis, SES-ANA and LP is still unclear and is debated in the literature. The clinical picture of chronic ulcerative stomatitis is similar to that of LP (especially the erosive form), and differentiation of these diseases is difficult. Some authors believe that chronic ulcerative stomatitis is part of the broad spectrum of LP (46). Parodi et al. (10) identified cutaneous LP and LP-like lesions in 13.6% of patients of patients with circulating SES-ANA.

There are reports of SES-ANA in patients with LP of the skin, mucous membranes, scalp and nails, as well as in patients with LP-like lesions, but in only 6 cases was LP confirmed by histopathology (8, 10, 12, 47–50).

In our study, we found SES-ANA in 25/126 (19.8%) patients with LP and in 10/16 (62.5%) patients with VVG-LP. It is interesting to note that, in patients with VVG-LP with scalp involvement (vulvovaginal-gingival-pilar LP), 66.6% (8/12) of patients were positive for SES-ANA.

In 23/25 (92.0%) patients with circulating SES-ANA, the antibodies were also detected *in vivo*, bound in the perilesional area in skin and/or oral mucosa and/or genital mucosa. SES-ANA were present most frequently in patients with extensive severe involvement of the mucous membranes, skin and scalp, a form of LP that is most refractory to therapy.

In conclusion, the results of this study indicate that VVG-LP is frequently associated with lichen planopilaris. This entity may be termed “vulvovaginal-gingival-pilar lichen planus”. Furthermore, this study indicates that SES-ANA are a marker of VVG-LP and forms of LP with extensive, severe and refractory-to-therapy involvement of the mucous membranes and scalp, such as “vulvovaginal-gingival-pilar” LP.

REFERENCES

1. Pelisse M. The vulvo-vaginal-gingival syndrome. A new form of erosive lichen planus. *Int J Dermatol* 1989; 28: 381–384.
2. Pelisse M, Leibowitch M, Sedel D, Hewitt J. Un nouveau syndrome vulvo-vaginal gingival: lichen planus erosive plurimucqueux. *Ann Dermatol Venereol* 1982; 109: 797–798.
3. Buffon RB, Lisboa AP, Carvalho F, Muller KR, Bonamigo RR. Vulvovaginal-gingival lichen planus – a rare or under-reported syndrome? *Int J Dermatol* 2009; 48: 322–324.
4. Panagiotopoulou N, Wong CS, Winter-Roach B. Vulvovaginal-gingival syndrome. *J Obstet Gynaecol* 2010; 30: 226–230.
5. Petrucci M, De Benedittis M, Pastore L, Grassi FR, Serpico R. Peno-gingival lichen planus. *J Periodontol* 2005; 76: 2293–2298.
6. Jaremko WM, Beutner EH, Kumar V, Kipping H, Condry P, Zeid MY, et al. Chronic ulcerative stomatitis associated with a specific immunologic marker *J Am Acad Dermatol* 1990; 22: 215–220.
7. Beutner EH, Chorzelski TP, Parodi A, Schosser R, Guin J, Cardo PP, et al. Ten cases of chronic ulcerative stomatitis with stratified epithelium-specific antinuclear antibody. *J Am Acad Dermatol* 1991; 24: 781–782.
8. Chorzelski TP, Olszewska M, Jarzabek-Chorzelska M, Jablonska S. Is chronic ulcerative stomatitis an entity? Clinical and immunological findings in 18 cases. *Eur J Dermatol* 1998; 8: 261–265.
9. Romano RA, Solomon LW, Sinha S. Tp63 in oral development, neoplasia, and autoimmunity. *J Dent Res* 2012; 91: 125–132.
10. Parodi A, Cozzani E, Massone C, Rebora A, Priano L, Ghigliotti G, et al. Prevalence of stratified epithelium-specific antinuclear antibodies in 138 patients with lichen planus. *J Am Acad Dermatol* 2007; 56: 974–978.
11. Solomon LW. Chronic ulcerative stomatitis. *Oral Dis* 2008; 14: 383–389.
12. Cozzani E, Cacciapuoti M, di Marco E, Zerega B, Descalzi

- Cancedda F, Parodi A. Patients with oral erosive and cutaneous lichen planus may have antibodies directed against the chronic ulcerative stomatitis protein antigen of 70-kDa. *Acta Dermatovenereol Alp Pannonica Adriat* 2008; 17: 120–124.
13. Rudnicka L, Olszewska M, Rakowska A, Kowalska-Oledzka E, Slowinska M. Trichoscopy: a new method for diagnosing hair loss. *J Drugs Dermatol* 2008; 7: 651–654.
 14. Mubki T, Rudnicka L, Olszewska M, Shapiro J. Evaluation and diagnosis of the hair loss patient: part II. Trichoscopic and laboratory evaluations. *J Am Acad Dermatol* 2014; 71: 431 e1–e11.
 15. Solomon LW, Stark PC, Winter L, Kumar V, Sinha S. ELISA test for p63 antibodies in chronic ulcerative stomatitis. *Oral Dis* 2010; 16: 151–155.
 16. Arora SK, Chhabra S, Saikia UN, Dogra S, Minz RW. Lichen planus: a clinical and immuno-histological analysis. *Indian J Dermatol* 2014; 59: 257–261.
 17. Bhattacharya M, Kaur I, Kumar B. Lichen planus: a clinical and epidemiological study. *J Dermatol* 2000; 27: 576–582.
 18. Eisen D, Carrozzo M, Bagan Sebastian JV, Thongprasom K. Number V Oral lichen planus: clinical features and management. *Oral Dis* 2005; 11: 338–349.
 19. Mignogna MD, Lo Russo L, Fedele S. Gingival involvement of oral lichen planus in a series of 700 patients. *J Clin Periodontol* 2005; 32: 1029–1033.
 20. Lewis FM, Bogliatto F. Erosive vulval lichen planus – a diagnosis not to be missed: a clinical review. *Eur J Obstet Gynecol Reprod Biol* 2013; 171: 214–219.
 21. Kirtschig G, Wakelin SH, Wojnarowska F. Mucosal vulval lichen planus: outcome, clinical and laboratory features. *J Eur Acad Dermatol Venereol* 2005; 19: 301–307.
 22. Ebrahimi M, Lundqvist L, Wahlin YB, Nylander E. Mucosal lichen planus, a systemic disease requiring multidisciplinary care: a cross-sectional clinical review from a multidisciplinary perspective. *J Low Genit Tract Dis* 2012; 16: 377–380.
 23. Eisen D. The evaluation of cutaneous, genital, scalp, nail, esophageal, and ocular involvement in patients with oral lichen planus. *Oral Surg Oral Med Oral Pathol Oral Radiol Endod* 1999; 88: 431–436.
 24. Webber NK, Setterfield JF, Lewis FM, Neill SM. Lacrimal canalicular duct scarring in patients with lichen planus. *Arch Dermatol* 2012; 148: 224–227.
 25. Fox LP, Lightdale CJ, Grossman ME. Lichen planus of the esophagus: what dermatologists need to know. *J Am Acad Dermatol* 2011; 65: 175–183.
 26. Rennie CE, Dwivedi RC, Khan AS, Agrawal N, Ziyada W. Lichen planus of the larynx. *J Laryngol Otol* 2011; 125: 432–435.
 27. Eisen D. The vulvovaginal-gingival syndrome of lichen planus. The clinical characteristics of 22 patients. *Arch Dermatol* 1994; 130: 1379–1382.
 28. Rogers RS, 3rd, Eisen D. Erosive oral lichen planus with genital lesions: the vulvovaginal-gingival syndrome and the peno-gingival syndrome. *Dermatol Clin* 2003; 21: 91–98.
 29. Setterfield JF, Neill S, Shirlaw PJ, Theron J, Vaughan R, Escudier M, et al. The vulvovaginal gingival syndrome: a severe subgroup of lichen planus with characteristic clinical features and a novel association with the class II HLA DQB1*0201 allele. *J Am Acad Dermatol* 2006; 55: 98–113.
 30. Di Fede O, Belfiore P, Cabibi D, De Cantis S, Maresi E, Kerr AR, et al. Unexpectedly high frequency of genital involvement in women with clinical and histological features of oral lichen planus. *Acta Derm Venereol* 2006; 86: 433–438.
 31. Danielsson K, Coates PJ, Ebrahimi M, Nylander E, Wahlin YB, Nylander K. Genes involved in epithelial differentiation and development are differentially expressed in oral and genital lichen planus epithelium compared to normal epithelium. *Acta Derm Venereol* 2014; 94: 526–530.
 32. Chew A, Stefanato CM, Savarese I, Neill SM, Fenton DA, Lewis FM. Clinical patterns of lichen planopilaris in patients with vulval lichen planus. *Br J Dermatol* 2014; 170: 218–220.
 33. Miteva M, Tosti A. Dermoscopy guided scalp biopsy in cicatricial alopecia. *J Eur Acad Dermatol Venereol* 2013; 27: 1299–1303.
 34. Rakowska A, Slowinska M, Olszewska M, Rudnicka L. New trichoscopy findings in trichotillomania: flame hairs, V-sign, hook hairs, hair powder, tulip hairs. *Acta Derm Venereol* 2014; 94: 303–306.
 35. Sumida H, Sugaya M, Kamata M, Suga H, Miyagaki T, Ohmatsu H, et al. Lichen planus-like lesions as the first manifestation of adult T-cell leukaemia/lymphoma. *Acta Derm Venereol* 2013; 93: 461–463.
 36. Pavlovsky L, Israeli M, Sagy E, Berg AL, David M, Sheiner A, et al. Lichen Planopilaris is Associated with HLA DRB1*11 and DQB1*03 Alleles. *Acta Derm Venereol* 2015; 95: 177–180.
 37. Lin SC, Sun A, Wu YC, Chiang CP. Presence of anti-basal cell antibodies in oral lichen planus. *J Am Acad Dermatol* 1992; 26: 943–947.
 38. Lee LA, Walsh P, Prater CA, Su LJ, Marchbank A, Egbert TB, et al. Characterization of an autoantigen associated with chronic ulcerative stomatitis: the CUSP autoantigen is a member of the p53 family. *J Invest Dermatol* 1999; 113: 146–151.
 39. Solomon LW, Neiders ME, Zwick MG, Kirkwood KL, Kumar V. Autoimmunity to deltaNp63alpha in chronic ulcerative stomatitis. *J Dent Res* 2007; 86: 826–831.
 40. Hau PM, Yip YL, Huen MS, Tsao SW. Loss of DeltaNp63alpha promotes mitotic exit in epithelial cells. *FEBS Lett* 2011; 585: 2720–2726.
 41. Yang X, Lu H, Yan B, Romano RA, Bian Y, Friedman J, et al. DeltaNp63 versatilely regulates a Broad NF-kappaB gene program and promotes squamous epithelial proliferation, migration, and inflammation. *Cancer Res* 2011; 71: 3688–3700.
 42. Carlson MW, Garlick JA, Solomon LW. Chronic ulcerative stomatitis: evidence of autoimmune pathogenesis. *Oral Surg Oral Med Oral Pathol Oral Radiol Endod* 2011; 111: 742–748.
 43. Islam MN, Cohen DM, Ojha J, Stewart CM, Katz J, Bhattacharyya I. Chronic ulcerative stomatitis: diagnostic and management challenges – four new cases and review of literature. *Oral Surg Oral Med Oral Pathol Oral Radiol Endod* 2007; 104: 194–203.
 44. Worle B, Wollenberg A, Schaller M, Kunzelmann KH, Plewig G, Meurer M. Chronic ulcerative stomatitis. *Br J Dermatol* 1997; 137: 262–265.
 45. Solomon LW, Helm TN, Stevens C, Neiders ME, Kumar V. Clinical and immunopathologic findings in oral lichen planus pemphigoides. *Oral Surg Oral Med Oral Pathol Oral Radiol Endod* 2007; 103: 808–813.
 46. Parodi A, Cozzani E, Cacciapuoti M, Rebora A. Chronic ulcerative stomatitis: antibodies reacting with the 70-kDa molecule react with epithelial nuclei. *Br J Dermatol* 2000; 143: 671–672.
 47. Church LF, Jr., Schosser RH. Chronic ulcerative stomatitis associated with stratified epithelial specific antinuclear antibodies. A case report of a newly described disease entity. *Oral Surg Oral Med Oral Pathol* 1992; 73: 579–582.
 48. Lewis JE, Beutner EH, Rostami R, Chorzelski TP. Chronic ulcerative stomatitis with stratified epithelium-specific antinuclear antibodies. *Int J Dermatol* 1996; 35: 272–275.
 49. Solomon LW, Aguirre A, Neiders M, Costales-Spindler A, Jividen GJ, Jr, Zwick MG, et al. Chronic ulcerative stomatitis: clinical, histopathologic, and immunopathologic findings. *Oral Surg Oral Med Oral Pathol Oral Radiol Endod* 2003; 96: 718–726.
 50. Fourie J, van Heerden WF, McEachen SC, van Zyl A. Chronic ulcerative stomatitis: a distinct clinical entity? *SADJ* 2011; 66: 119–121.