

## QUIZ SECTION

### Vesicles on the Breast Post-mastectomy: A Quiz

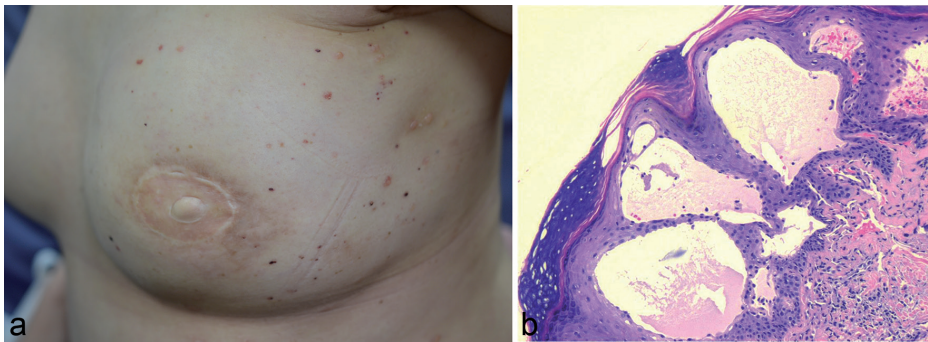
Jade Nicolette Chee and Mark Jean-Aan Koh

Dermatology Service, KK Women's & Children's Hospital, Singapore, 100 Bukit Timah Road, Singapore 229899, Singapore. E-mail: jade.chee@gmail.com

A 43-year-old Chinese woman was diagnosed with carcinoma of her left breast in September 2005, for which she underwent a left skin-sparing mastectomy with axillary lymph node clearance, followed by left breast reconstruction. Histology revealed a 20-mm, grade 2, invasive ductal carcinoma, and 2 axillary lymph nodes with metastatic tumour (the largest being 45 mm in diameter). She completed chemotherapy and radiation therapy in 2006, followed by 5 years of tamoxifen. She presented to our Dermatology unit in 2014 with progressively increasing numbers of

small vesicular lesions over her left axilla and reconstructed left breast that had developed over one year. The lesions were associated with occasional itch, and were reported to increase in both size and number during menstruation. On examination, there were scattered, "frogspawn-like" skin-coloured vesicles, with a few being haemorrhagic (Fig. 1a). Punch biopsy revealed several dilated, thin-walled, vascular channels in the epidermis and superficial dermis (Fig. 1b).

*What is your diagnosis? See next page for answer.*



*Fig. 1. (a) Scattered, "frogspawn-like" vesicles over reconstructed breast and axillae. (b) Dilated thin-walled vascular channels on haematoxylin and eosin (H&E, ×40) stain.*

## ANSWERS TO QUIZ

**Vesicles on the Breast Post-mastectomy: A Commentary**

Acta Derm Venereol

**Diagnosis: Lymphangioma circumscriptum**

On histopathology the vascular channels in the epidermis and superficial dermis were found to be lined with a single layer of flattened endothelial cells, and contained mostly clear serous fluid, with a sprinkling of red cells (see Fig. 1b). The cells lining the dilated vascular channels stained positively for podoplanin (D2-40) immunohistochemical stain (Fig. 2).

Lymphangioma circumscriptum, also known as microcystic lymphangioma or lymphatic malformations, are vascular malformations characterized clinically by grouped, translucent or haemorrhagic vesicles ranging in size from minute to 5 mm in diameter. They are formed by superficial saccular dilations from underlying lymphatic vessels that occupy the dermal papilla, which are pushed upwards against the overlying epidermis (1). The lesions usually present at birth or arise in early childhood. However, acquired forms with similar clinical and histological features have been reported as rare sequelae of lymphatic damage resulting from cancer treatment, e.g. following post-mastectomy lymphoedema, following radiation therapy, and in the lymphoedematous vulva and leg of a patient after surgery and radiation therapy for cervical carcinoma (2–4). Lymphangioma circumscriptum can oc-

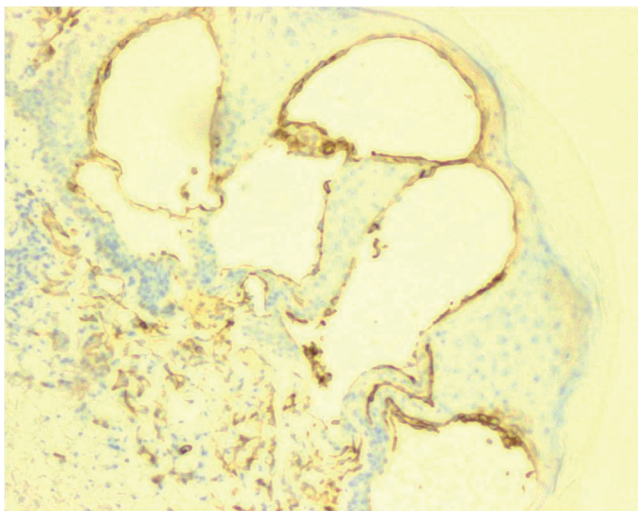


Fig. 2. Podoplanin (D2-40) immunohistochemical stain. Positively-stained lymphatic endothelial cells lining dilated vascular channel (H&E,  $\times 40$ ).

cur anywhere on the skin, but are most commonly found on the neck, axilla, breasts, chest, buttocks and thighs. The condition is more common in females.

The basic pathology of lymphangioma circumscriptum involves the collection of lymphatic cisterns in the deep subcutaneous plane, which arise from primitive lymph sacs that fail to connect with the rest of the lymphatic system (5). It is postulated that these sequestered primitive sacs are lined with a thick coat of muscle fibres whose rhythmic contractions increase the intramural pressure and force the dilated channels to protrude from the walls of the cisterns toward the skin. The deep cisterns do not communicate with the general lymphatic system (2). The development of lymphoedema following surgery or radiation therapy is presumably related to increased hydrostatic pressure within vessels proximal to lymphatic obstruction, and it is postulated that cases of lymphangiectasias are similarly related to altered lymphatic flow (2).

Indications for treatment of lymphangioma circumscriptum may include persistent leakage of lymph fluid or blood, recurrent infection, or for cosmesis. Treatment options include electrocautery, radiotherapy, cryosurgery, argon laser phototherapy and surgical excision. Regardless of the treatment modality used, recurrences are common unless the entire lesion, including the deep communicating cistern, is removed or destroyed. Surgery is the treatment of choice for lymphangioma circumscriptum, with the highest success rate for lesions confined to the superficial dermis. Nevertheless, recurrence after surgical excision has been reported, even with the addition of lymphangiography and frozen sections along incision margins (6).

*The authors declare no conflicts of interests.*

## REFERENCES

- Blank AA, Eichmann F. Palliative chirurgic und computer-tomographie bei lymphangiokeratoma circumscriptum naeviforme. *Z Hautkr* 1982; 57: 252–262.
- Leshin B, Whitaker DC, Foucar E. Lymphangioma circumscriptum following mastectomy and radiation therapy. *J Am Acad Dermatol* 1986; 15: 1117–1119.
- LaPolla J, Foucar E, Leshin B, Whitaker D, Anderson B. Vulvar lymphangioma circumscriptum: a rare complication of therapy for squamous cell carcinoma of the cervix. *Gynecol Oncol* 1985; 22: 363–366.
- Fisher I, Orkin M. Acquired lymphangioma (lymphangiectasias). *Arch Dermatol* 1970; 101: 230–234.
- Whimster IW. The pathology of lymphangioma circumscriptum. *Br J Dermatol* 1976; 94: 473–486.
- Flanagan B, Helwig E. Cutaneous lymphangioma. *Arch Dermatol* 1977; 113: 24–30.