

## SHORT COMMUNICATION

### Childhood Epidermolysis Bullosa Acquisita with Underlying Coeliac Disease

Michael Kasperkiewicz<sup>1</sup>, Irén Orosz<sup>2</sup>, Dietrich Abeck<sup>3</sup>, Sibylle Koletzko<sup>4</sup>, Thomas Ruzicka<sup>5</sup> and Miklós Sárdy<sup>5\*</sup>

Departments of <sup>1</sup>Dermatology and <sup>2</sup>Pediatrics, University of Lübeck, Lübeck, <sup>3</sup>Group Practice for Dermatology and Allergology, <sup>4</sup>Division of Pediatric Gastroenterology and Hepatology, and <sup>5</sup>Department of Dermatology and Allergology, Ludwig Maximilian University Munich, Frauenlobstr. 9–11, DE-80337 München, Germany. E-mail: miklos.sardy@med.lmu.de

Accepted Mar 30, 2015; Epub ahead of print Mar 31, 2015

Epidermolysis bullosa acquisita (EBA) is a chronic sub-epidermal, mucocutaneous blistering disease caused by autoantibodies targeting the non-collagenous domain 1 (NC1) of type VII collagen (1). Most reported cases have occurred in adults, while patients with childhood EBA are very rare (2–4). Coeliac disease (CD) is an immune-mediated systemic disorder in genetically (mostly HLA-related) predisposed individuals, elicited by exposure to gluten and characterized by gluten-dependent signs and symptoms, autoantibodies and a typical small bowel enteropathy (5). Autoantibodies against tissue transglutaminase are highly specific and sensitive for patients with CD on a normal gluten-containing diet regardless of symptoms (5). We report here a rare case of occurrence of EBA in childhood and the first report of association with CD.

#### CASE REPORT

A 5-year-old Caucasian girl was admitted to our department with a 6-month history of facial cutaneous blistering eruptions that were refractory to treatment with topical antibiotics and glucocorticosteroids. She also had recurrent abdominal pain, constipation, mood changes, and fatigue, which had started a few months prior to the blistering. As CD was suspected 2 months prior to admission, anti-tissue transglutaminase and anti-gliadin antibody tests were performed and were positive. A gluten-free diet (GFD) was started, which led to some improvements in both gastrointestinal and skin symptoms. To confirm CD according to the current diagnostic guidelines (5), gluten was reintroduced into the diet prior to obtaining duodenal biopsies. This resulted in a relapse of the skin lesions.

Physical examination revealed tense bullae and erosions on the face (Fig. 1A), trunk, perianal area, and oral and genital mucosa. Routine laboratory tests at the time of endoscopy were normal, except for iron deficiency. Histopathology of a skin biopsy showed subepidermal blistering with predominantly neutrophil infiltration in the upper dermis. Direct immunofluorescence microscopy revealed linear deposition of IgG1, IgG3 and IgG4 at the dermo-epidermal junction. Indirect immunofluorescence microscopy was positive for both IgA and IgG (Fig. 1C and D). Immunoblot analysis demonstrated IgG4 antibodies reactive with both a 290-kDa

polypeptide in dermal extracts and recombinant NC1 domain of type VII collagen. CD was proven by repeated positive IgA anti-tissue transglutaminase antibodies and histology of duodenal biopsies with total villous atrophy, crypt hyperplasia, and increased intraepithelial lymphocytes (Marsh IIIB). Thus, she was diagnosed as having EBA with concomitant CD.

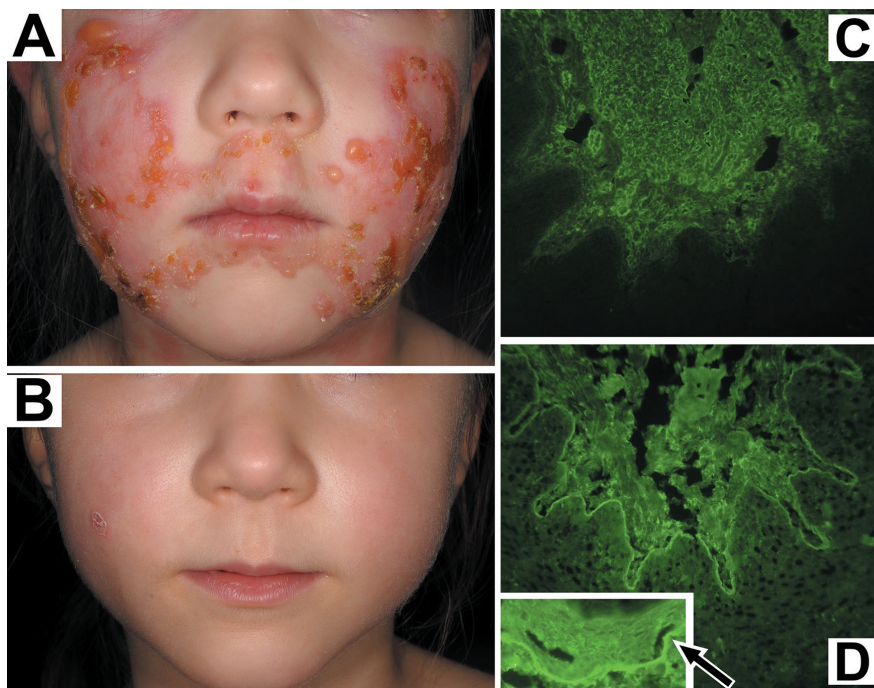
Due to severe skin lesions and a deteriorated general condition, the patient was hospitalized and started on prednisolone (1 mg/kg/day) while a GFD was reinitiated. Within 4 days, her skin and general condition improved substantially, and prednisolone was gradually tapered to 0.7 mg/kg/day within 2 weeks. Glucose-6-phosphate dehydrogenase activity was within normal limits, and she was started on dapsone 1.8 mg/kg/day. This resulted in better control of her skin disease (Fig. 1B), allowing the systemic prednisolone to be tapered off over the next 4 months. EBA- and CD-specific autoantibodies decreased and remained sustainably negative.

During the following 17 months, EBA was well controlled by dapsone in combination with a GFD (7 months) and subsequently a GFD alone (10 months). Recurrences of isolated and occasional blistering after accidental gluten intake could be controlled with topical glucocorticosteroids. The patient's mood changes and fatigue did not regress despite the GFD.

#### DISCUSSION

To date, only 39 cases of childhood EBA, including the present case, have been reported (2–4). While adult EBA often requires prolonged treatment with high doses of prednisolone and adjuvant immunosuppressants, in childhood EBA, a combination of dapsone with low-dose prednisolone usually results in sufficient control (2–4).

Dermatitis herpetiformis is considered a specific cutaneous manifestation associated with CD responding to a GFD. A few patients with other autoimmune bullous diseases, including linear IgA bullous dermatosis, bullous pemphigoid, and pemphigus, have also been described to be possibly associated with CD and to partly improve on a GFD. In some of these cases, however, duodenal biopsy was not performed (6–8). In contrast, we did not find any reported case of CD-associated EBA induced by gluten intake and controlled by a GFD.



*Fig. 1.* Clinical manifestation. (A) Tense, grouped blisters in annular and string of pearls patterns with crusted erosions on erythematous facial skin. (B) Almost complete recovery 4 months after first presentation. The girl received prednisolone (1 mg/kg/day) gradually tapered off over 4 months. From the third week of treatment, dapsone 1.8 mg/kg/day was given as adjuvant to facilitate the tapering off of prednisolone. Indirect immunofluorescence microscopy on monkey oesophagus revealing both (C) immunoglobulin A (IgA) antibodies against endomysium and (D) linear deposits of immunoglobulin G (IgG) at the basement membrane zone. *Inset:* IgG binding to the dermal side of the artificial blister on human salt-split skin (*arrow*).

A recent review found 42 cases of coincident EBA and inflammatory bowel disease (only one child with Crohn's disease and no child with CD) (9). Since type VII collagen is expressed in both the skin and gastrointestinal tract (10), antigen presentation of type VII collagen during inadequately regulated intestinal inflammation might predispose to formation of autoantibodies (9). In most described cases of EBA, including our patient, the diagnosis of inflammatory bowel disease or CD preceded the development of the skin lesions (9).

Therefore, type VII collagen exposure during duodenojejunal inflammation caused by CD could be a possible explanation for EBA development in our patient. This is supported by the facts that: (i) the onset of gastrointestinal symptoms of CD preceded the skin disease; (ii) a GFD could control skin manifestations; and (iii) dietary mistakes led to relapses.

## REFERENCES

- Ludwig RJ. Clinical presentation, pathogenesis, diagnosis, and treatment of epidermolysis bullosa acquisita. *ISRN Dermatol* 2013; 812029.
- Mayuzumi M, Akiyama M, Nishie W, Ukae S, Abe M, Sawamura D, et al. Childhood epidermolysis bullosa acquisita with autoantibodies against the noncollagenous 1 and 2 domains of type VII collagen: case report and review of the literature. *Br J Dermatol* 2006; 155: 1048–1052.
- Abrams ML, Smidt A, Benjamin L, Chen M, Woodley D, Mancini AJ. Congenital epidermolysis bullosa acquisita: vertical transfer of maternal autoantibody from mother to infant. *Arch Dermatol* 2011; 147: 337–341.
- Baican A, Chiriac G, Torio-Padron N, Sitaru C. Childhood epidermolysis bullosa acquisita associated with severe dental alterations: a case presentation. *J Dermatol* 2013; 40: 410–411.
- Husby S, Koletzko S, Korponay-Szabó IR, Husby S, Koletzko S, Korponay-Szabó IR, et al. European Society for Pediatric Gastroenterology, Hepatology, and Nutrition guidelines for the diagnosis of coeliac disease. *J Pediatr Gastroenterol Nutr* 2012; 54: 136–160.
- Egan CA, Smith EP, Taylor TB, Meyer LJ, Samowitz WS, Zone JJ. Linear IgA bullous dermatosis responsive to a gluten-free diet. *Am J Gastroenterol* 2001; 96: 1927–1929.
- Marconi B, Campanati A, Marzioni M, Cataldi I, Brandozzi G, Giuliodori K, et al. Bullous pemphigoid of Lever and celiac disease: a coincidental occurrence or an unusual association? *G Ital Dermatol Venereol* 2012; 147: 654–656.
- Drago F, Cacciapuoti M, Basso M, Parodi A, Rebora A. Pemphigus improving with gluten-free diet. *Acta Derm Venereol* 2005; 85: 84–85.
- Reddy H, Shipman AR, Wojnarowska F. Epidermolysis bullosa acquisita and inflammatory bowel disease: a review of the literature. *Clin Exp Dermatol* 2013; 38: 225–229.
- Chen M, O'Toole EA, Sanghavi J, Mahmud N, Kelleher D, Weir D, et al. The epidermolysis bullosa acquisita antigen (type VII collagen) is present in human colon and patients with Crohn's disease have autoantibodies to type VII collagen. *J Invest Dermatol* 2002; 118: 1059–1064.