

SHORT COMMUNICATION

Successful Methotrexate Treatment of Oesophageal Pemphigus Vulgaris in an Immunosuppressed Patient with Crohn's Disease

Orsolya N. Horváth^{1,2}, Alena Borovaya¹, Elisabeth Roeder¹, Joachim Klose³, Eva Hartlieb⁴, Jens Waschke⁴, Thomas Ruzicka¹ and Miklós Sárdy¹Departments of ¹Dermatology and Allergology, and ³Gastroenterology, ⁴Institute of Anatomy and Cell Biology, Ludwig Maximilian University, Frauenlobstr. 9–11, DE-80337 Munich, Germany, and ²Institute of Behavioural Sciences, Semmelweis University, Budapest, Hungary. E-mail: Orsolya.Horvath@med.lmu.de
Accepted Feb 16, 2015; Epub ahead of print Feb 24, 2015

Association of different autoimmune diseases, such as pemphigus vulgaris (PV) and rheumatoid arthritis or type 1 diabetes, is well known. However, the development of PV during significant immunosuppressive treatment for another autoimmune disease, as in the case described here, is uncommon (1).

CASE REPORT

A 32-year-old Caucasian man was admitted to our department for evaluation of oesophageal erosions that had persisted for one year (Fig. 1A and 1B). On admission a small erosion was observed on his soft palate. The patient had a history of recalcitrant Crohn's disease, with colon manifestation at 17 years of age. An early colectomy was performed as the patient's condition was unresponsive to systemic immunosuppression. However, the small bowel subsequently became involved, requiring various immunosuppressive therapies including systemic prednisolone, azathioprine, mercaptopurine, adalimumab, and certolizumab. On admission, the patient's Crohn's disease was stable on treatment with 400 mg certolizumab monotherapy s.c. bi-weekly. The patient was also on prednisolone 60 mg/day orally (0.82 mg/kg body weight) due to oesophageal lesions.

Oesophageal Crohn's disease, PV, and persistent erosive infection were taken into consideration. The prednisolone dose was tapered below 10 mg, resulting in a severe relapse. Yeast, human herpes virus 1–5, HIV, hepatitis B+C, and syphilis infections were excluded. Indirect immunofluorescence revealed linear intercellular epithelial staining on monkey oesophagus (titre 1:40). Both desmoglein 1 and 3 enzyme-linked

immunoassays (ELISAs) were positive (titres 44.1 and 47.4 AU/ml, respectively; cut-off: 20 AU/ml). However, direct immunofluorescence on repeated, multiple (7 oesophageal and 2 oral) perilesional biopsies were negative, although acantholysis could be observed. To prove that the circulating autoantibodies are indeed pathogenic, an *in vitro* keratinocyte dissociation assay was performed confirming pathogenicity (Fig. 1C). In addition to 60 mg oral prednisolone daily, the patient received 2 g/kg body weight intravenous immunoglobulins monthly and azathioprine up to 3 mg/kg body weight daily, but the dose of prednisolone could not be tapered below 20 mg daily, and azathioprine was hepatotoxic. Thus, azathioprine was replaced by methotrexate in increasing doses up to 30 mg weekly. The prednisolone dose could be reduced to 10 mg daily, but further reduction led to relapse, requiring a long-term maintenance dose of 10 mg daily. At the 2-year follow-up, the patient was free of signs or symptoms of PV on a combination of prednisolone (10 mg daily), methotrexate (30 mg weekly) and immunoglobulins.

DISCUSSION

Isolated oesophageal PV is very rare (2), while involvement of the oesophagus as part of widespread mucocutaneous PV is reported more frequently (3). Oesophageal manifestation of PV occurs rarely under immunosuppression, but has already been described several times (2, 4). Although the association of PV with inflammatory bowel disease has been reported previously in 4 patients, none showed oesophageal invol-

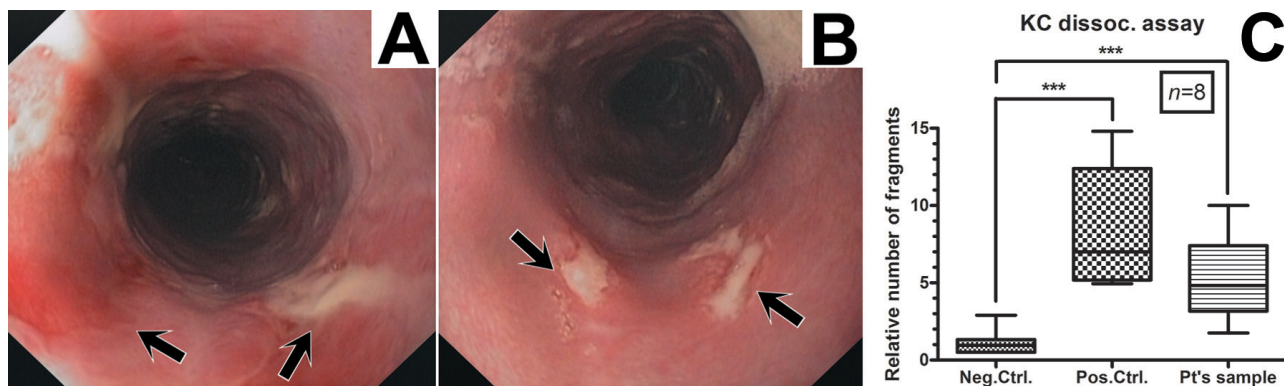


Fig. 1. (A, B) Endoscopy of oesophageal erosions (arrows) partially covered by fibrin. (C) Keratinocyte (KC) dissociation assay using primary keratinocytes from a healthy donor and total serum immunoglobulin G (IgG) of the patient purified by a GraviTrap protein A/G column (GE Healthcare, Freiburg, Germany). The number of fragments is given as a ratio of the mean number of fragments of the samples and negative controls in 8 independent experiments. A monoclonal antibody against desmoglein 3 (AK23) was used as positive control (Pos. Ctrl.); phosphate buffered saline was used as negative control (Neg. Ctrl.). Upper and lower whiskers indicate the maximum and minimum values, respectively. The top and bottom of the boxes show the 75th and 25th percentiles, respectively. The median is shown by a line through each box. *** $p < 0.001$ using Mann-Whitney's non-parametric, 2-tailed test.

vement (1). The inflammatory bowel disease affected the colon in all patients, as in our patient, before the colectomy (1). PV occurred both before and after the diagnosis of inflammatory bowel disease, and in 2 patients it appeared during immunosuppressive therapy.

PV has been reported to occur due to treatment with TNF α -inhibitor (etanercept) (5). Thus, we cannot exclude the unlikely possibility of a drug-induced PV. However, we decided not to stop certolizumab because this was the only drug in the patient's history that could efficiently stabilize the Crohn's disease.

The diagnostic situation in our patient was difficult because, despite serological evidence for desmoglein autoantibodies and acantholysis in the histological specimen, direct immunofluorescence could not prove oesophageal pathogenicity of these circulating autoantibodies; therefore, we suspected false serological positivity. Hence, keratinocyte dissociation assay was also performed. This is a non-standard and commercially unavailable test, but it is an established assay for analysis of the pathogenicity of pemphigus autoantibodies, which is used routinely by our research group (6).

In conclusion, immunosuppressive therapy is not always sufficient to prevent a second autoimmune disease. If false-positive serological results for PV are

suspected, the keratinocyte dissociation assay can help to make the correct diagnosis. Methotrexate was useful for treatment of mucosal PV in this case.

The authors declare no conflicts of interest.

REFERENCES

1. Prendiville JS, Israel DM, Wood WS, Dimmick JE. Oral pemphigus vulgaris associated with inflammatory bowel disease and herpetic gingivostomatitis in an 11-year-old girl. *Pediatr Dermatol* 1994; 11: 145–150.
2. Faias S, Lage P, Sachse F, Pinto A, Fidalgo P, Fonseca I, et al. Pemphigus vulgaris with exclusive involvement of the esophagus: case report and review. *Gastrointest Endosc* 2004; 60: 312–315.
3. Eliakim R, Goldin E, Livshin R, Okon E. Esophageal involvement in pemphigus vulgaris. *Am J Gastroenterol* 1988; 83: 155–157.
4. Kanbay M, Selcuk H, Gur G, Yilmaz U, Boyacioglu S. Involvement of the esophagus in a patient with pemphigus vulgaris who was on immunosuppressive therapy. *J Natl Med Assoc* 2006; 98: 1369–1370.
5. Daulat S, Detweiler JG, Pandya AG. Development of pemphigus vulgaris in a patient with psoriasis treated with etanercept. *J Eur Acad Dermatol Venereol* 2009; 23: 483–484.
6. Spindler V, Rötzer V, Dehner C, Kempf B, Gliem M, Radeva M, et al. Peptide-mediated desmoglein 3 crosslinking prevents pemphigus vulgaris autoantibody-induced skin blistering. *J Clin Invest* 2013; 123: 800–811.