

## SHORT COMMUNICATION

## A Case of Felty's Syndrome Associated with Skin Ulcers and Extranodal NK/T-cell Lymphoma

En Shu<sup>1</sup>, Hiroyuki Kanoh<sup>1</sup>, Yusuke Kito<sup>2</sup> and Mariko Seishima<sup>1</sup><sup>1</sup>Department of Dermatology, Gifu University School of Medicine, and <sup>2</sup>Department of Pathology and Translational Research, Gifu University Graduate School of Medicine, Yanagido, Gifu 501-1194, Japan. E-mail: shu1402@gifu-u.ac.jp

Accepted Feb 11, 2015; Epub ahead of print Feb 12, 2015

Felty's syndrome (FS), which occurs in 1% of patients with rheumatoid arthritis (RA), is characterized by the symptoms of arthritis, leukopaenia and splenomegaly (1). This condition usually develops after a long disease course in RA patients and is considered to be a severe variant of RA (2). Moreover, patients with FS are at increased risk of developing lymphoma (3). We report here a rare case of FS associated with NK/T-cell lymphoma.

## CASE REPORT

A 59-year-old woman presented with a 3-month history of multiple leg ulcers with peripheral purpura and reticular pigmentation on her lower leg (Fig. 1a). She had been diagnosed with Sjögren's syndrome 5 years previously and had received various anti-TNF $\alpha$  agents in addition to methotrexate (MTX) for 3 years for refractory RA. Despite these treatments, the patient had arthralgia and joint destruction. Therefore, the anti-TNF $\alpha$  agents and MTX were withdrawn 11 months prior to the current visit, and tocilizumab, an anti-IL6 receptor blocker, was administered instead. A skin biopsy of the edge of a leg ulcer demonstrated leukocytoclastic vasculitis extending from the middle to upper dermis (Fig. 1b).

Laboratory tests showed pancytopenia (white blood cells (WBC) =  $1.9 \times 10^9/l$ , haemoglobin (Hb) = 9.9g/dl, platelets (Plt) =  $6.4 \times 10^{10}/l$ ), which had also been detected on previous tests, with leukopaenia being the first manifestation, followed by thrombocytopenia and anaemia. The antinuclear antibody (ANA) titre was 1:80 with a homogenous pattern and 1:1,280 with a speckled pattern. Autoantibodies to SS-A ( $\geq 500$  U/ml), SS-B (18.7 U/ml), double-strand DNA (31 IU/ml, normal: 12 IU/ml) and neutrophils were positive, whereas antibodies to Sm and U1-RNP were negative. Other examinations revealed markedly high titres of rheumatoid factor (423 IU/ml) and anti-CCP antibodies (688 U/ml, normal  $<4.5$  U/ml).

Three months after the initial visit, the patient began to notice subcutaneous nodules on her trunk and lower extremities. A com-

puted tomography scan of the entire body showed splenomegaly, multiple swollen lymph nodes in the para-aortic, bilateral inguinal and axilla regions, as well as subcutaneous nodules. Based on these findings, a diagnosis of FS was made. Bone marrow aspiration showed no involvement of lymphoma. The biopsy specimens of a subcutaneous nodule demonstrated infiltration of lymphoid cells within the subcutis associated with focal necrosis of the adipose tissue. In addition, there was admixture of small lymphocytes, histiocytes and plasma cells. The lymphoid cells were medium-to-large in size, with irregular nuclei and pale cytoplasm (Fig. 2a). Notably, these cells were positive for cytoplasmic CD3 (Fig. 2b), granzyme B (Fig. 2c), TIA-1 and Epstein-Barr virus (EBV)-encoded RNA (EBER) (Fig. 2d) and negative for CD4, CD8 and CD56, leading to a diagnosis of extranodal NK/T-cell lymphoma. The patient subsequently received one cycle of carboplatin, etoposide, ifosfamide and dexamethasone (DeVIC) between 2 cycles of steroids, methotrexate, ifosfamide, L-asparaginase and etoposide (SMILE) and has survived for 17 months after the diagnosis.

## DISCUSSION

Patients with FS exhibit the clinical features of rheumatoid factor positivity and rheumatoid nodules with additional affected extra-articular lesions and more severe joint destruction compared with that observed in other patients with RA (4). The present patient's arthritis was under poor control and she had a high titre of rheumatoid factor associated with skin manifestations, including cutaneous vasculitis and leg ulceration, consistent with the characteristics of FS. Moreover, patients with FS are at increased risk of developing lymphoma and cancer (4). Previous reports have described comorbid primary T-cell lymphoma (5) and localized B-cell lymphoma (6), but not NK/T-cell lymphoma.

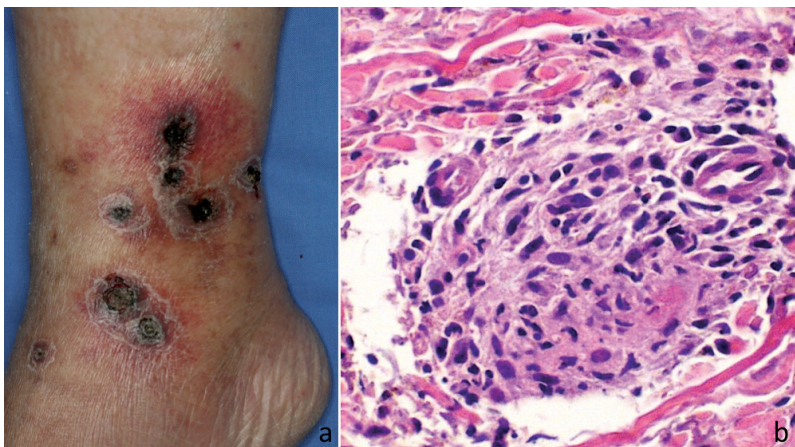


Fig. 1. (a) Ulcers covered by black necrotic tissues associated with peripheral purpura were observed on the patient's lower leg. (b) A skin biopsy of the edge of an ulcer showed leukocytoclastic vasculitis (haematoxylin-eosin, original magnification  $\times 200$ ).

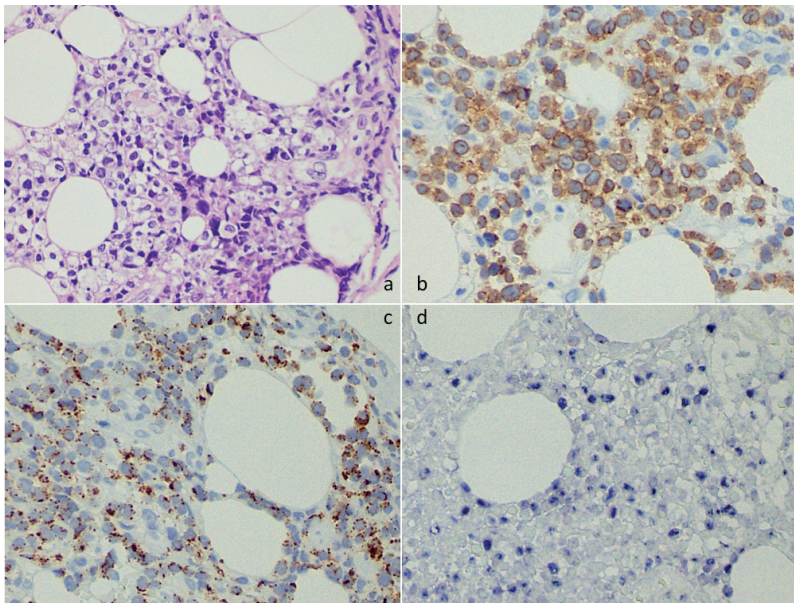


Fig. 2. Lymphoma cells had infiltrated the subcutis. (a) These cells were medium-to-large in size, with irregular nuclei and pale cytoplasm (haematoxylin-eosin, original magnification  $\times 400$ ). The lymphoma cells showed positive staining for: (b) CD3 $\epsilon$  (original magnification  $\times 400$ ), (c) granzyme B (original magnification  $\times 400$ ), and (d) Epstein-Barr virus-encoded RNA (EBER) on *in situ* hybridization (original magnification  $\times 400$ ).

In contrast, NK/T-cell lymphoma is an aggressive EBV-associated lymphoma more commonly seen in Asian populations. In fact, the EBV was detected in our patient's blood, indicating the presence of a chronic EBV infection. In some cases, the lymphoma is accompanied by haemophagocytic syndrome (HPS) (7). Although our patient had pancytopenia, HPS was excluded based on the results of bone marrow aspiration and biopsy examination, which showed no haemophagocytic signs. The diagnosis was also supported by the low serum level of ferritin, ranging from 200 to 300 ng/ml.

The patient demonstrated autoantibodies against dsDNA in addition to pancytopenia; thus, the possibility of systemic lupus erythematosus should be considered. However, there were no other manifestations, such as skin eruptions, renal disorders, serositis or neurological disorders. In addition, it is reasonable that the pancytopenia was caused by splenomegaly as a symptom of FS. Other possible cause included treatment with MTX and various biological therapies. Anti-TNF $\alpha$  therapy induces the production of secondary autoantibodies, such as ANA and anti-dsDNA antibodies, which were also noted in our patient. However, despite the relatively high incidence of autoantibody development, the frequency of drug-induced lupus is considered to be low (8). The findings of autoantibodies against neutrophils also support the diagnosis of FS.

Because our patient had Sjögren's syndrome and had been treated with MTX for years, it is possible that the NK/T lymphoma was a lymphoproliferative disease (LPD) related to the pathogenesis of Sjögren's syndrome and/or administration of MTX. However, in such cases, LPD usually originates from B cells, not NK/T cells (9, 10). The most likely explanation for the

co-existence of FS and NK/T-cell lymphoma in this case is treatment with MTX for the underlying presence of RA (resulting in the onset of unspecific splenomegaly, possibly in turn leading to thrombocytopenia and leukopenia), which subsequently induced myelotoxic cytopenia and the secondary development of lymphoma.

## REFERENCES

- Hanrahan EM, Miller SR. Effect of splenectomy in Felty's syndrome. *JAMA* 1932; 99: 1247–1249.
- Balint GP. Felty's syndrome. *Best Pract Res Clin Rheumatol* 2004; 18: 631–645.
- Gridley G, Klippel JH, Hoover RN, Fraumeni JF. Incidence of cancer among men with Felty syndrome. *Ann Intern Med* 1994; 120: 35–39.
- Campion G, Maddison PJ, Goulding N, James I, Ahern MJ, Watt I, et al. The Felty's syndrome: a case-matched study of clinical manifestations and outcome, serological features, and immunogenetic association. *Medicine* 1990; 69: 69–80.
- Bowman SJ, Levison DA, Cotter FE, Kingsley GH. Primary T cell lymphoma of the liver in a patient with Felty's syndrome. *Br J Rheumatol* 1994; 33: 157–160.
- Nassif PS, Feldon SE. Orbital lymphoma in a patient with Felty's syndrome. *Br J Ophthalmol* 1992; 76: 173–174.
- Willemze R, Jaffe ES, Burg G, Cerroni L, Berti E, Swerdlow SH, et al. WHO-EORTC classification for cutaneous lymphomas. *Blood* 2005; 105: 3768–3785.
- Araújo-Fernández S, Ahijón-Lana M, Isenberg DA. Drug-induced lupus: Including anti-tumour necrosis factor and interferon induced. *Lupus* 2014; 23: 545–553.
- Voulgarelis M, Moutsopoulos HM. Lymphoproliferation in autoimmunity and Sjögren's syndrome. *Curr Rheumatol Rep* 2003; 5: 317–323.
- Rizzi R, Curci P, Delia M, Rinaldi E, Chiefa A, Specchia G, Liso V. Spontaneous remission of "methotrexate-associated lymphoproliferative disorders" after discontinuation of immunosuppressive treatment for autoimmune disease. Review of the literature. *Med Oncol* 2009; 26: 1–9.